

UTERINE FIBROIDS

Shawqi Saleh, FRCOG
Professor Of OB/GYN
The University of Jordan

LEIOMYOMA

- A benign neoplasm of the muscular wall of the uterus composed primarily of smooth muscle surrounded by a false capsule.
- They are the most common gynecological tumors
- 25% of white women & 50% of black women
- The majority of fibroids are asymptomatic and will not require intervention or further investigations.

ETIOLOGY

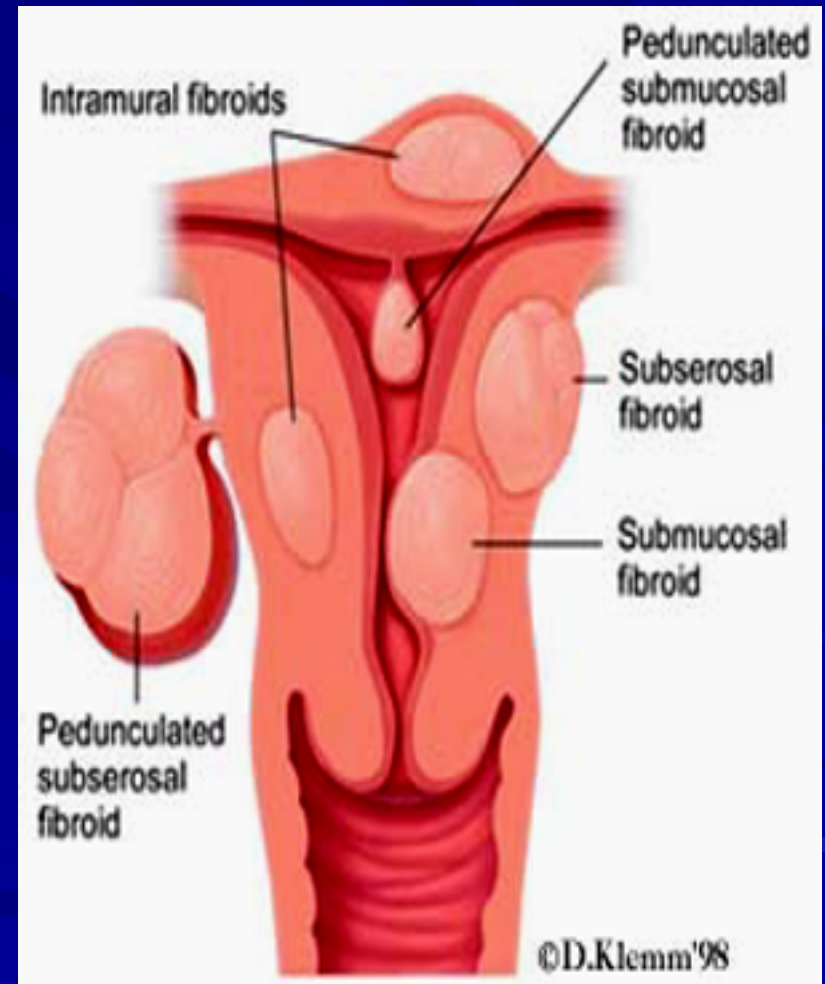
- Unknown
- Estrogens ➡ no evidence that it is a causative factor , it has been implicated in growth of myomas
 - Myomas contain estrogen receptors in higher concentration than surrounding myometrium
 - Myomas may increase in size with estrogen therapy & in pregnancy & decrease after menopause
 - They are not detectable before puberty
- Progesterone increase mitotic activity ➡ ↑ in size
- There may be genetic predisposition

PATHOLOGY—gross

- Frequently multiple
- May reach 15 cm in size or larger
- Firm
- Spherical or irregularly lobulated
- Have a false capsule
- Can be easily enucleated from surrounding myometrium

CLASSIFICATION

- Submucous leiomyoma
- Pedunculated submucous
- Intramural or interstitial
- Subserous or subperitoneal
- Pedunculated abdominal
- Parasitic
- Intraligmentary
- Cervical



MICROSCOPIC STRUCTURE

- Nonstriated muscle fibers arranged in bundles running in different directions
- Individual cells are spindle shaped uniform
- Varying amount of connective tissue are interlaced between muscle fibers
- Pseudocapsule of areolar tissue & compressed myometrium
- Arteries are less dense than myometrium & do not have a regular pattern of distribution
- 1-2 major vesseles are found at the base or pedicle

Benign Degeneration

- **Atrophic**
- **Hyaline ➡ yellow, soft gelatinous areas**
- **Cystic ➡ liquefaction follows extreme hyalinization**
- **Calcification ➡ circulatory deprivation ➡ precipitation of ca carbonate & phosphate**
- **Septic ➡ circulatory deprivation ➡ necrosis ➡ infection**
- **Myxomatous (fatty) ➡ uncommon, follows hyaline or cystic degeneration**
- **Red degeneration**

Red degeneration

- Commonly occurs during pregnancy
- Edema & hypertrophy ➡impede blood supply ➡aseptic degeneration & infarction with venous thrombosis & hemorrhage
- Painful but self-limiting
- May result in preterm labor

MALIGNANT TRANSFORMATION

- Transformation to leiomyosarcomas occurs in 0.1-0.5%

Clinical presentation

- Symptomatic in only 35-50% of Pt
- Symptoms depend on location, size, changes & pregnancy status

Abnormal uterine bleeding

- The most common 30%
- Heavy / prolonged bleeding (menorrhagia) ➡ iron deficiency anemia
- Submucous myoma produce the most pronounced symptoms of menorrhagia, pre & post-menstrual spotting
- Bleeding is due to interruption of blood supply to the endometrium, distortion & congestion of surrounding vessels or ulceration of the overlying endometrium
- Pedunculated submucous ➡ areas of venouse thrombosis & necrosis on the surface ➡ intermenstrual bleeding

Pain

- Vascular occlusion ➡ necrosis, infection
- Torsion of a pedunculated fibroid ➡ acute pain
- Myometrial contractions to expel the myoma
- Red degeneration ➡ acute pain
- Heaviness fullness in the pelvic area
- If the tumor gets impacted in the pelvis ➡ pressure on nerves ➡ back pain radiating to the lower extremities
- Dyspareunia if it is protruding to vagina
- In the postmenopausal woman presenting with pain and fibroids, leiomyosarcoma should be considered
- Cervical tumors ➡ serosanguineous vaginal discharge, bleeding, dyspareunia or infertility

PRESSURE EFFECTS

- If large may distort or obstruct other organs like ureters, bladder or rectum ➡ urinary symptoms, hydronephrosis, constipation, pelvic venous congestion & LL edema
- Rarely a posterior fundal tumor ➡ extreme retroflexion of the uterus distorting the bladder base ➡ urinary retention
- Parasitic tumor may cause bowel obstruction

Infertility

- The impact of fibroids on fertility is controversial.
- Fibroids probably account for only 2% to 3% of infertility cases.
- 27-40% of women with multiple fibroids are infertile ➡ but other causes of infertility are present
- Endocavitary tumors affect fertility more
- Theories
 1. Dysfunctional uterine contractility
 2. Focal endometrial vascular disturbance
 3. Endometrial inflammation
 4. Secretion of vasoactive substances
 5. Obstruction of the ostia of the fallopian tubes

Infertility---cont

- Fibroids larger than 5 cm, and those close to the cervix or tubal ostia, are also thought to be more problematic.
- In women undergoing IVF cycles , submucous or intramural myomas, which distort the uterine cavity, have a negative impact on implantation and pregnancy rates.

Fibroids and pregnancy

- In 4% to 5% of women undergoing prenatal ultrasounds, uterine fibroids are detected.
- An increasing number of women are delaying pregnancy until their late thirties, which is also the most likely time for fibroids to develop.

- **SPONTANEOUS ABORTIONS**

~2X N ➡ incidence before myomectomy 40%
after myomectomy 20%

More with intracavitary tumors

Fibroids and pregnancy

If the placenta implants over or in close proximity to a myoma, there may be an increased risk of

- Miscarriage,
- Preterm labour,
- Abruptio,
- Prelabour rupture of membranes
- Intrauterine growth restriction.

Fibroids and pregnancy

Fibroids located in the lower uterine segment may increase the likelihood of:

1. **Fetal malpresentation**
2. **Caesarean section.**
3. **Postpartum hemorrhage.**

Fibroids and Pregnancy

Red degeneration

- In the 2nd or 3rd trimester of pregnancy ➡ rapid
↑ in size ➡ vascular deprivation ➡ degeneration
- Causes pain & tenderness
- May initiate preterm labor
- Managed conservatively with bedrest & narcotics
+ tocolytics if indicated
- After the acute phase pregnancy will continue to
term

Fibroids and Pregnancy During Labor

- **Uterine inertia**
- **Malpresentation**
- **Obstruction of the birth canal**
- **Cervical or isthmeic myoma ➡ necessitate CS**
- **PPH**

Fibroids and Pregnancy (myomectomy)

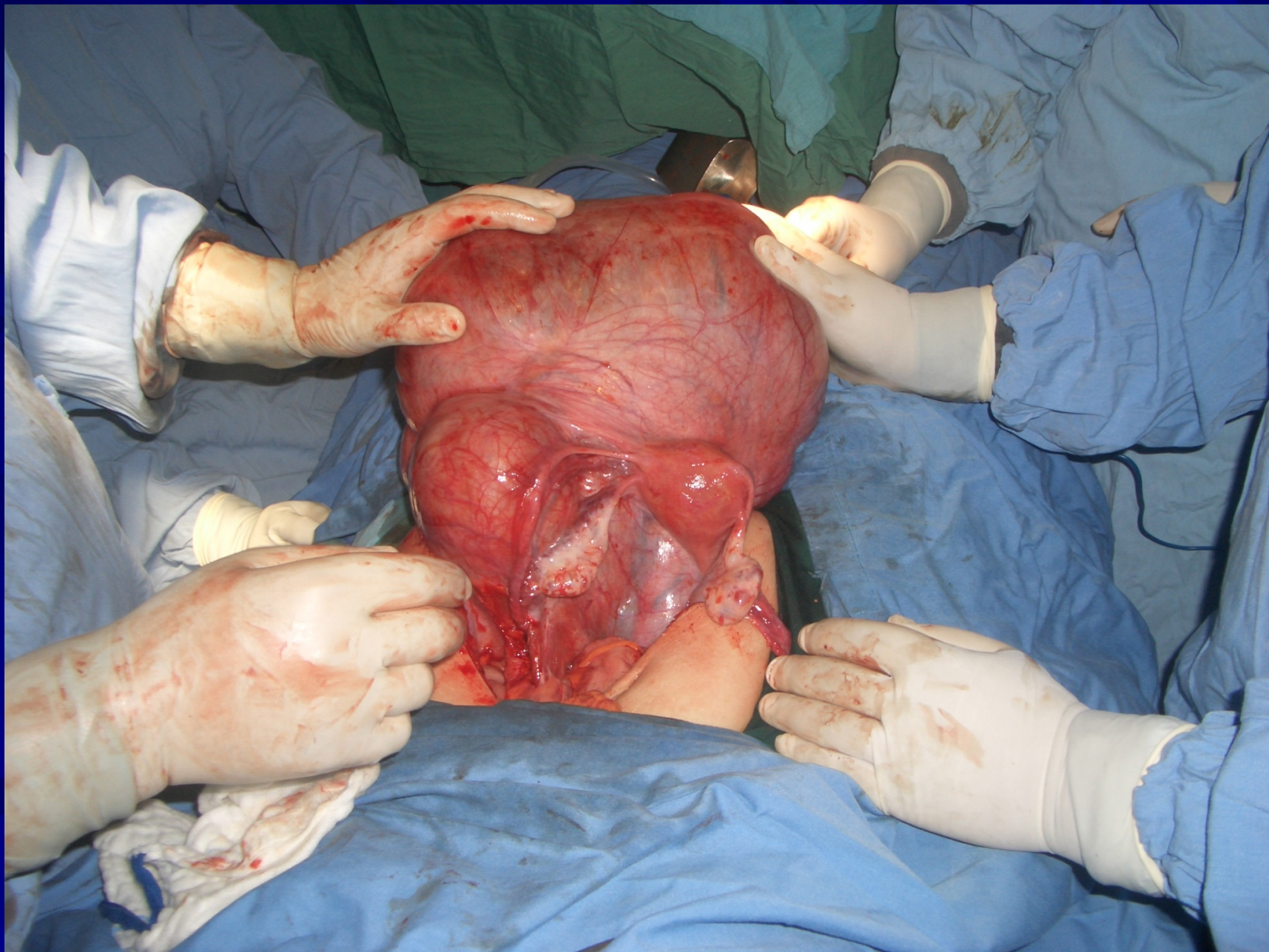
- **Myomectomy should not be performed in pregnant women because of the increased risk of uncontrolled bleeding.**
- **The exception may be symptomatic subserous fibroids on a pedicle less than 5 cm thick, in which case the risk of hemorrhage may be reduced.**

EXAMINTION

- Most myoma are discovered on routine bimanual pelvic exam or abdominal examination

LABORATORY FINDINGS

- Anemia
- Depletion of iron reserve
- Rarely erythrocytosis ➡ pressure on the ureters ➡ back pressure on the kidneys ➡ ↑ erythropoietin
- Acute degeneration & infection ➡ ↑ ESR, leucocytosis, & fever



IMAGING

- Pelvic U/S is very helpful in confirming the Dx & excluding pregnancy / Particularly in obese Pt
- Saline hysterosonography ➡ can identify submucous myoma that may be missed on U/S
- HSG ➡ will show intrauterine leiomyoma
- MRI ➡ highly accurate in delineating the size, location & no. of myomas , but not always necessary
- IVP ➡ will show ureteral dilatation or deviation & urinary anomalies

HYSTROSCOPY ➡ for identification & removal of submucous myomas

DIFFERENTIAL DIAGNOSIS

- Usually easily diagnosed
- Exclude pregnancy
- Exclude other pelvic masses
 - Ovarian Ca
 - Tubo-ovarian abscess
 - Endometriosis
 - Adenexa, omentum or bowel adherent to the uterus
- Exclude other causes of uterine enlargement:
 - Adenomyosis
 - Congenital anomalies
 - Endometrial Ca

DIFFERENTIAL DIAGNOSIS

Exclude other causes of abnormal bleeding

- Endometrial hyperplasia
- Endometrial ca
- Uterine sarcoma
- Ovarian Ca
- Polyps
- Adenomyosis
- DUB
- Endometriosis
- Exogenous estrogens

Endometrial biopsy or D&C is essential in the evaluation of abnormal bleeding to exclude endometrial Ca

COMPLICATIONS IN NONPREGNANT WOMEN

- Heavy bleeding with anemia is the most common
- Urinary or bowel obstruction from large parasitic myoma is much less common
- Malignant transformation is rare
- Ureteral injury or ligation is a recognized complication of surgery for Cx myoma
- No evidence that COCP ↑ the size of myomas
- Postmenopausal women on HRT must be followed up with pelvic exam or U/S every 6 M

TREATMENT

Depends:

- Age
- Parity
- Pregnancy status
- Desire for future pregnancy
- General health
- Symptoms
- Size
- Location

GNRH AGONISTS

RX results in:

- 1-↓ size of the myomas up to 50%
- 2- This shrinkage is achieved in 3M of RX
- 3-Amenorrhea & hypoestrogenic side-effects occur
- 4-Osteoporosis may occur if Rx last > 6M

It is indicated for

- 1-↓ menstrual related anemia
- 2-Preoperative to ↓ size →
 - Allow for vaginal hysterectomy
 - Abdominal myomectomy
 - laparoscopic myomectomy

Medical management--cont

Tranexamic acid may reduce menorrhagia associated with fibroids.

Progestins may be associated with fibroid growth.

There is no evidence that low-dose oral contraceptives cause benign fibroids to grow, thus uterine fibroids are not a contraindication to their use.

Surgical management

When considering hysterectomy for menorrhagia attributed to fibroids, other causes should be ruled out.

Endometrial biopsy should be considered to exclude endometrial lesions.

Surgical Management

Myomectomy

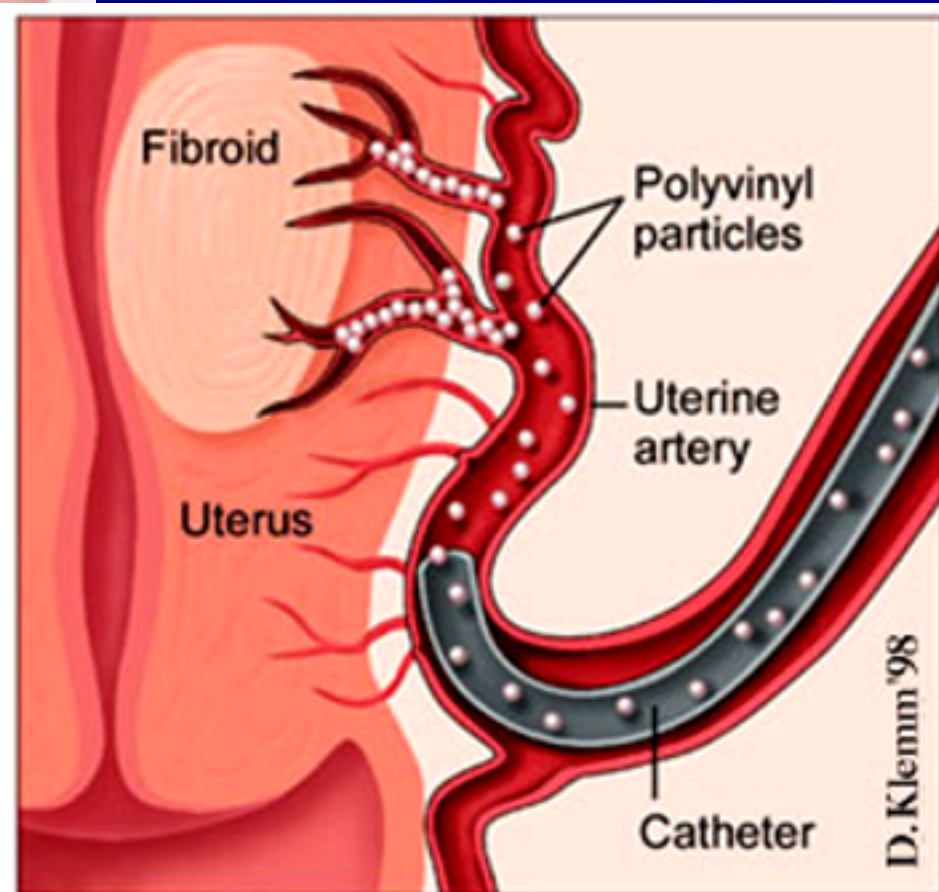
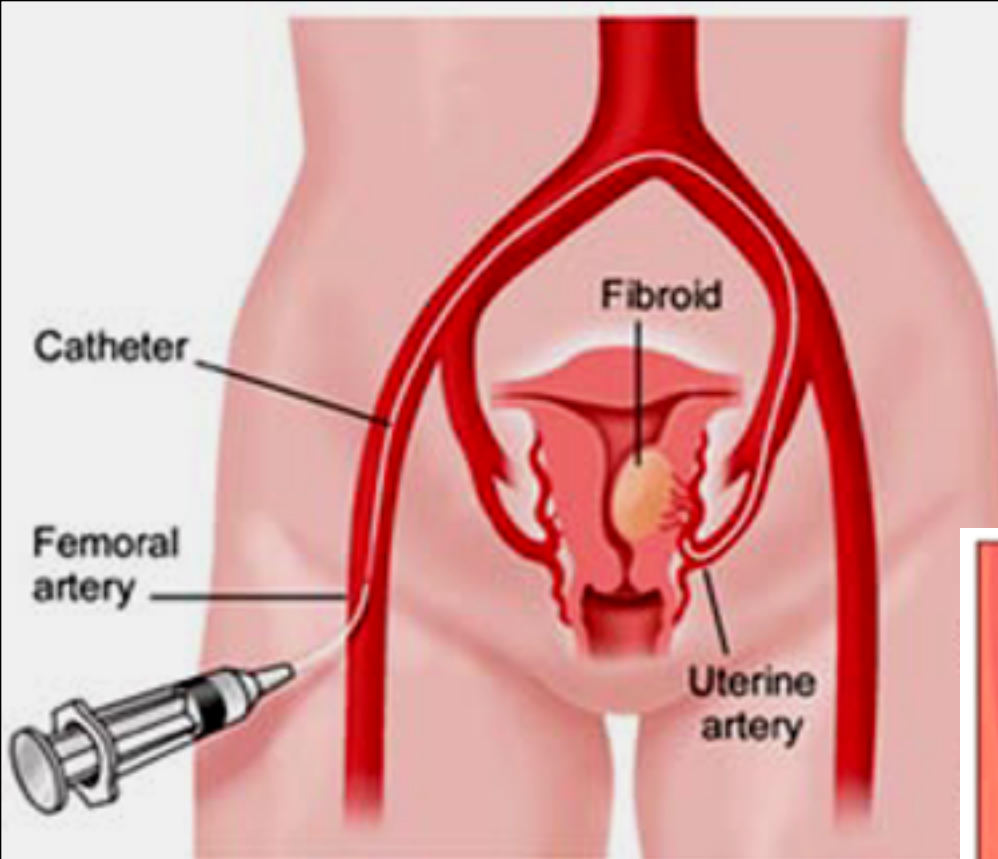
- For symptomatic Pt who wish to preserve fertility
- Open myomectomy
- Laparoscopic myomectomy
- Hysteroscopic myomectomy
- There is a 15% recurrence rate for fibroids and
- 10% of women undergoing a myomectomy will eventually require hysterectomy within 5 to 10 years
- Women should be counselled about the risks of requiring a hysterectomy at the time of a planned myomectomy.

Surgical Management

- **Hysterectomy**
 - **Vaginal hysterectomy**
 - **Abdominal hysterectomy**
- **Uterine artery embolization**

Uterine artery embolization

- Minimally invasive
- Low complication rates
- Effective
- Repeatable if necessary
- Uses proved technique of embolization, available for more than 30 years



PVA 300-500 microns

UAE--Complications

- Early or Acute Abdominal Pelvic Pain
- Infection
- Persistent or Chronic Pain
- Ovarian Dysfunction
- Transient and permanent amenorrhea have been reported in 15% and 3% of women, respectively.
- Hysterectomy

Post embolization Syndrome

- Up to 40% of women experience a :
 1. Diffuse abdominal pain,
 2. Generalized malaise,
 3. Anorexia,
 4. Nausea, vomiting,
 5. Low-grade fever, and
 6. Leukocytosis.

FIBROIDS IN MENOPAUSE

Fibroids will usually shrink to about half their original size after menopause.

Combined HRT, particularly using transdermal estrogen, can cause myoma growth, however, the myoma growth did not cause any clinical symptoms in these women

FIBROIDS AND UTERINE LEIOMYOSARCOMAS

- 50% of the women had experienced abnormal bleeding, more likely if the lesion was submucous.
- Other symptoms in descending order of frequency were pain, an enlarging abdomen, or abnormal vaginal discharge.
- A uterine mass increasing in size in a postmenopausal woman suggests a leiomyosarcoma rather than a benign leiomyoma.
- The masses tend to be softer due to tissue necrosis and internal cystic degeneration and hemorrhage.