Neurologic examination

Mai Bade, MD
Child Neurologist ☺

Components of the neurologic examination:

- EXAMINATION OF HIGHER CEREBRAL FUNCTIONS
- CRANIAL NERVE EXAM
- COORDINATION EXAM
- SENSORY EXAM
- MOTOR EXAM
- REFLEXES
- GAIT EXAM

- The neurological examination of the pediatric patient must be couched in the context of neurodevelopmental aspect including primitive reflexes.

- The infant and child are unable to fully cooperate for the standard neurological examination, SO the examination must be tailored to the child and their developmental level and temperament.

- The **first** part of the examination is to **stop, look, and listen**
- **Second: Make it a Game**
- **Third: Save the Worst for Last**

- **Mental status examination = observation in pediatric age group less than 2 years, after that it depends on the developmental milestone.**

- ✓ Level of consciousness
- ✓ Orientation, Memory
- ✓ Attention-working memory
- ✓ Judgment-abstract reasoning
- ✓ Set generation
- ✓ Receptive language
- ✓ Expressive language
- ✓ Praxis
- ✓ Gnosis
- ✓ Dominant parietal lobe function.
- ✓ Non-dominant parietal lobe function.
- ✓ Visual recognition.

Age	Evidence of normal cortical function
6 to 12 months	Awareness of surroundings
	Interaction with examiner (social smile, inquisitiveness, habituation)
	Cooing and gurgling, sometimes making of nonspecific "mama" and "dada" sounds
12 to 20 months	Six to eight word vocabulary
	Comprehends one-step commands
	Points to two or three body parts
24 months	Names two or three body parts
	Uses phrases and simple sentences
24 to 36 months	Concept of self (referring to self as "I", knowledge of name and age)
36 months	Counts three objects
	Understands prepositional concepts (eg, "over" and "under")
	Asks questions
	Names three colors
48 months	Copies a square and a cross
5 or 6 years	Spells monosyllabic words
	Counts to 10
6 years	Copies a triangle
6 or 7 years	Does simple addition and subtraction
	Reads polysyllabic words
7 years	Copies a diamond

Cranial nerves :

- in infants is often by observation for specific movements and responses.

- I (olfactory) : The sense of smell

- II optic nerve : test for visual field, acuity, color vision, pupillary reflex and optic disc:

Testing visual acuity :

- In an infant, visual acuity can be tested by observing the infant reach for objects of varying size.
- Infant older than six months of age will usually reach for scraps of paper less than 5 mm in size when they are placed on a dark background.
- Standard tests can be used in older children who can recognize objects, letters, or numbers. Beyond 4 years of age, the E test is useful.
- Finger counting can be used if acuity is grossly distorted

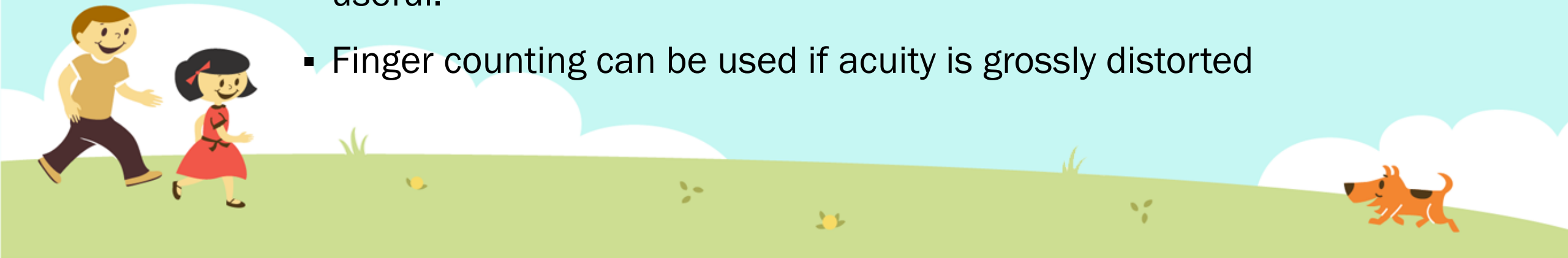

- Visual fields can be tested by introducing objects into the peripheral field of vision as the child focuses on an object held directly in front of him or her. The lateral and superior fields of vision can be assessed more easily than can the nasal fields
- Pupillary light response (direct and consensual) – A normal pupillary light reflex requires CN II and III.
- Color vision
- fundoscope

Visual responses mature with CA :

- At 26 weeks CA, infants consistently blink to light.
- At 32 weeks CA, infants begin to show signs of fixation.
- At 34 weeks CA, most infants can track a fluffy ball of red wool.
- At 37 weeks CA, infants will turn their eyes towards a soft light

pupillary light response, is consistently present by 35 weeks gestation



- III (oculomotor), IV (trochlear), and VI (abducens) for extraocular movements
- tested by assessing the child’s ability to track a brightly colored toy or soft light.

- The Doll's eye maneuver test can be performed as early as 25 weeks CA

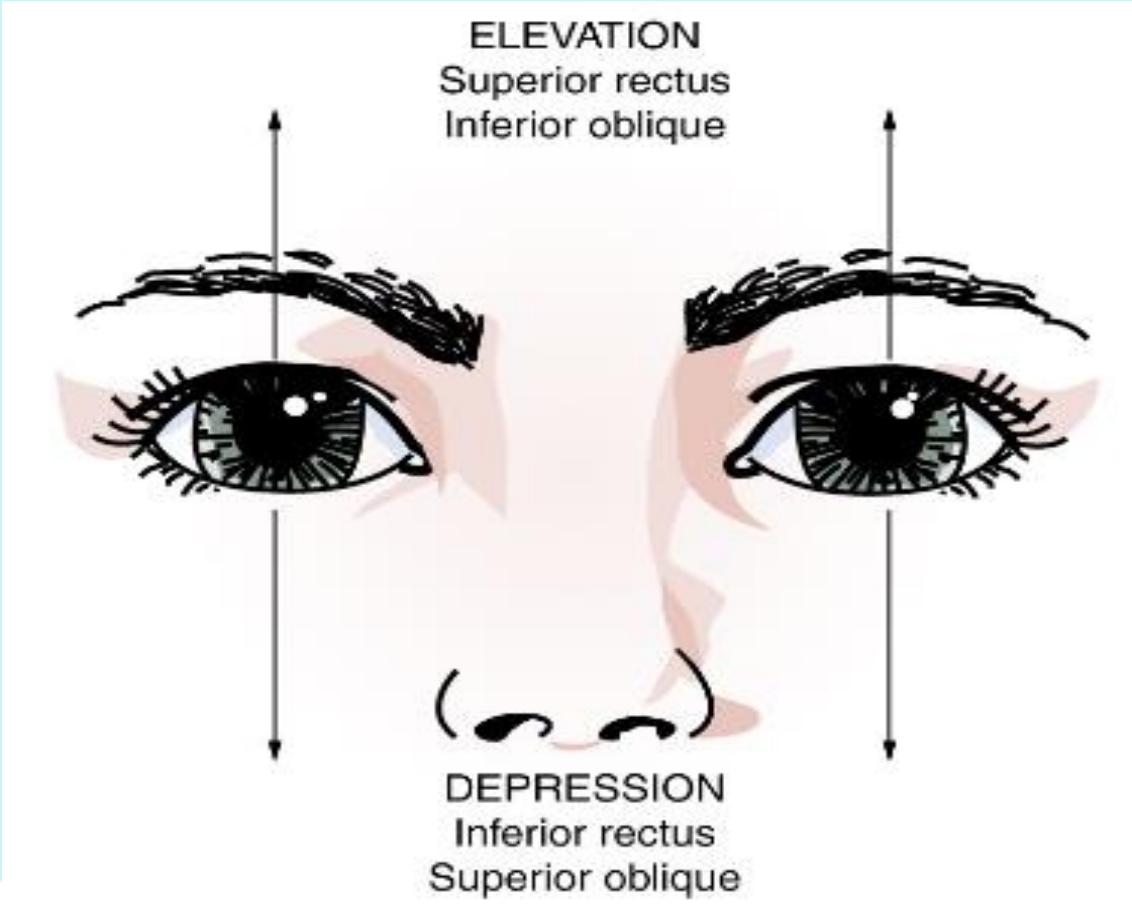
ELEVATION
Superior rectus
Inferior oblique
DEPRESSION
Inferior rectus
Superior oblique

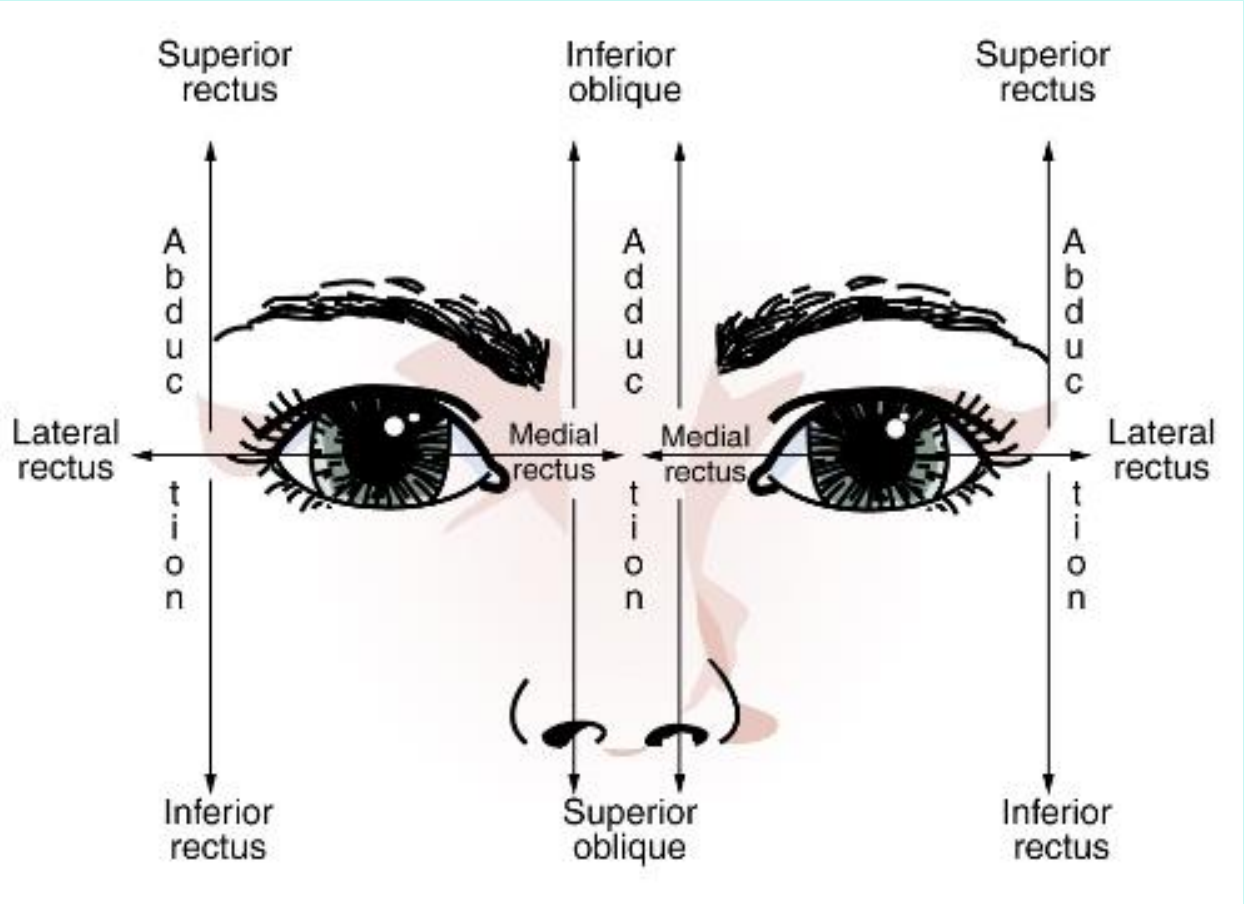
Superior rectus
Inferior oblique
Superior rectus
Abduction
Adduction
Abduction
Lateral rectus
Medial rectus
Medial rectus
Lateral rectus
Inferior rectus
Superior oblique
Inferior rectus

Paretic Muscle	Cranial Nerve	Eye Deviation
Inferior oblique	III	Down and out
Inferior rectus	III	Up and in
Lateral rectus	VI	Medial
Medial rectus	III	Lateral
Superior oblique	IV	Upward and outward (head tilted)
Superior rectus	III	Down and in

- V (trigeminal) — The sensory function of CN V can be tested by the response to light touch over the face (use a tissue) and by sensation on the cornea and conjunctiva, Motor function of CN V is tested by assessing masseter muscle strength

- VII (facial) — The function of CN VII can be assessed by observing for symmetry of the nasolabial folds, assessing eye lid muscle strength, and the ability to wrinkle the forehead symmetrically, taste sensation over the anterior two thirds of the tongue

- VIII (vestibulocochlear) :
- In infants, hearing is tested by making a soft sound close to one ear, such as from rustling of paper. The infant should show an alerting response. By the age of five to six months, the infant may also be able to localize the sound
- In cooperative school age children, speech discrimination can be tested by softly whispering
- Rinne and Weber tests can be used in older children

- IX (glossopharyngeal) and X (vagus)
- responsible for swallowing function, movement of the soft palate, and are often tested by eliciting a gag reflex. Salivary drooling or pooling of saliva also suggests dysfunction. Hoarseness of the voice can be caused by CN X dysfunction.
- XI (spinal accessory) — CN XI mediates motor function in the trapezius or sternomastoids
- XII (hypoglossal) :

Motor system:

Posture and movements

- Asymmetry at rest in infants
- Opisthotonus
- frog-legged” posture
- Tremor
- Myoclonus
- Athetosis
- Chorea
- Tics
- Muscle atrophy, pseudohypertrophy
- Fasiculation

- Tone
- Examining for truncal and extremity tone

✓ resting posture, arm recoil, scarf sign, leg recoil, popletial angel, heel to ear. Head control, ventral and vertical suspension

- Hypotonia
- Hypertonia : spasticity vs rigidity

Power :

- **Strength testing - Upper extremity :** C5 to T1

- C5 – Shoulder extension
  C6 – Arm flexion
  C7 – Arm extension
  C8 – Wrist extensors
  T1 – Hand grasp

- **Strength testing - Lower extremity :** L2 to S1
  L2 – Hip flexion
  L3 – Knee extension
  L4 – Knee flexion
  L5 – Ankle dorsiflexon
  S1 – Ankle plantar flexion

Grading

- 0 – No contraction
  1 – Slight contraction, no movement
  2 – Full range of motion without gravity
  3 – Full range of motion with gravity
  4 – Full range of motion , some resistance
  5 – Full range of motion, full resistance

- **Tendon reflexes —**

- **Upper extremity**
  Biceps – C5-6
  Brachioradialis – C5-6
  Triceps – C7
  Finger Flexors – C8

- **Lower extremity**

- Patellar or Knee – L2-4
  Ankle – S1-2

- **Grading DTR's**

- 0 – Absent
  1 – Decreased but present
  2 – Normal
  3 – Brisk and excessive
  4 – With clonus

- The plantar reflex (S1)

- The superficial abdominal reflexes (T8 – T 12)

- The cremasteric reflex (L1-2)

Coordination

For cerebellar function :

- Speech Rapid Alternating Movements
- Tremor
- Rebound
- Reflex
- Hand Rapid Alternating Movements
- Finger to nose
- Foot Rapid Alternating Movements
- Toe-to-finger
- Heel to chin
- Station
- Natural gait
- Tandem gait

- Cerebellar dysfunction :
- Dymetria which may manifest as nystagmus, intention tremor, scanning speech, truncal or gait ataxia, or rebound phenomenon
- Ataxia
- Altered rhythmic movement

Sensory system

- A sensory examination in young children is often imprecise, and only gross deficits can be detected
- In children older than five to six years, sensory function is evaluated in the same manner as in an adult.

The ST is examined by testing:

- Pain
- Temperature

The DCML is examined by testing:

- Vibratory sensation
- Position sense
- Discriminative sensation (must have intact DCML plus intact parietal cortex):
  - Tactile direction
  - 2-point discrimination
  - Graphesthesia
  - Stereognosis
  - Double simultaneous Stimulation

Gait

- Hemiplegic
- Spastic diplegic
- Neuropathic
- Myopathic
- Parkinsonian
- Chorea
- Ataxic

Reflex	Age at appearance	Age at resolution
Moro (startle)	34 to 36 weeks PCA	5 to 6 months
Asymmetric tonic neck reflex	38 to 40 weeks PCA	2 to 3 months
Trunk incurvation (Galant)	38 to 40 weeks PCA	1 to 2 months
Palmar grasp	38 to 40 weeks PCA	5 to 6 months
Plantar grasp	38 to 40 weeks PCA	9 to 10 months
Rooting	38 to 40 weeks PCA	2 to 3 months
Parachute	8 to 9 months of age	Persists throughout life

THANK YOU