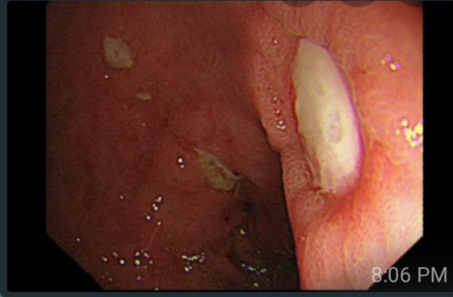


A 42 years old male patient , on NSAIDs presented with melena of 3 days duration

8:05 PM

This is his EGD 8:06 PM

Dr. Nadia khamees



8:06 PM

Dx? 8:06 PM

Dr. Nadia khamees

Dx?

Peptic ulcer 8:06 PM

Dr. Nadia khamees

What is its Forrest classification? 8:07 PM

3 8:07 PM

Dr. Nadia khamees

So forrest classification is made to predict risk of rebleeding and to guide your management 8:08 PM

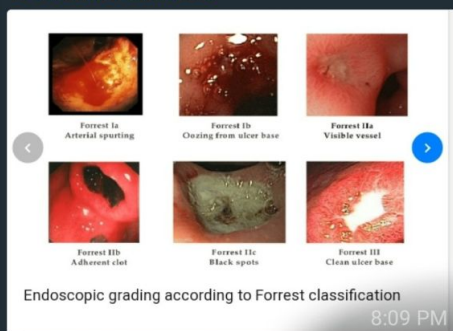Dr. Nadia khamees

Forrest classification	Rebleeding
Type 1 Active bleeding	
1a Spurting hemorrhage	90-100%
1b Oozing hemorrhage	80-85%
Type 2 Signs of recent bleeding	
2a Non-bleeding visible vessel	40-50%
2b Adherent clot on lesion	20-30%
2c Hematin-covered lesion	5%
Type 3 Lesion without bleeding (flat spot, clean base)	≤3%

8:09 PM

This is a case of clean based ulcer 8:09 PM

Dr. Nadia khamees



8:09 PM

Type 1 and 2a you should intervene endoscopically 8:10 PM

2c and 3 no endoscopic hemostatic intervention is needed 8:11 PM

2b is an area of controversy 8:11 PM

Another patient with melena 8:11 PM

**Dr. Nadia khamees**

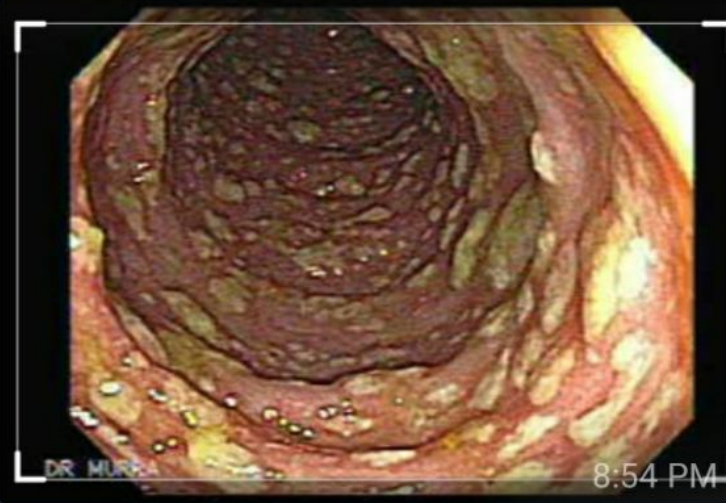A 56 years old female patient with diarrhea since 5 days

8:53 PM

Was on clindamycin during the last prior week

8:54 PM

**Dr. Nadia khamees**



Pseudomembranous colitis

8:54 PM

**Dr. Nadia khamees**

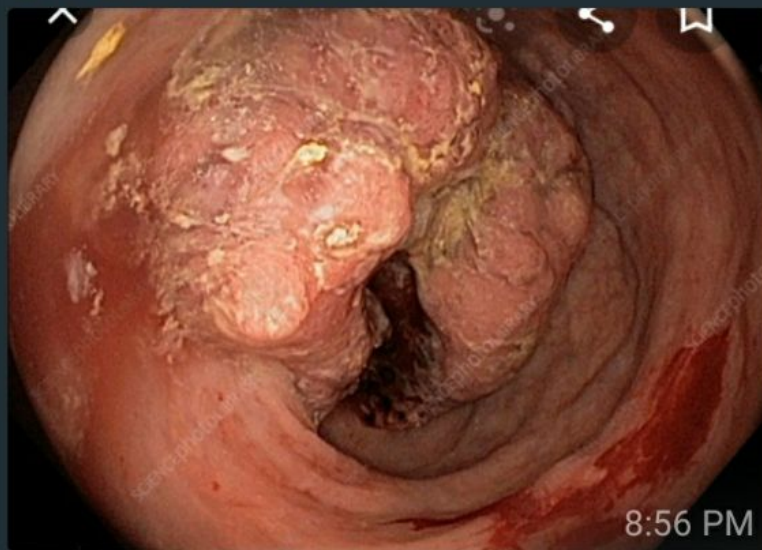A 65 years old man with weight loss and constipation

8:56 PM

This is his colonoscopy

8:56 PM

**Dr. Nadia khamees**

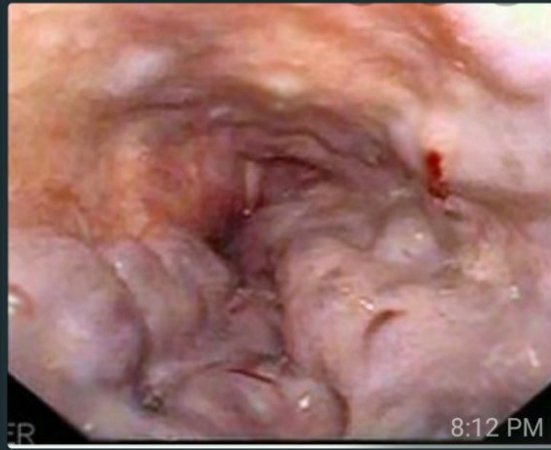

Colon cancer

8:57 PM

Another patient with melena 8:11 PM

Dr. Nadia khamees



Dx? 8:12 PM

Esophageal varices 8:12 PM

Dr. Nadia khamees

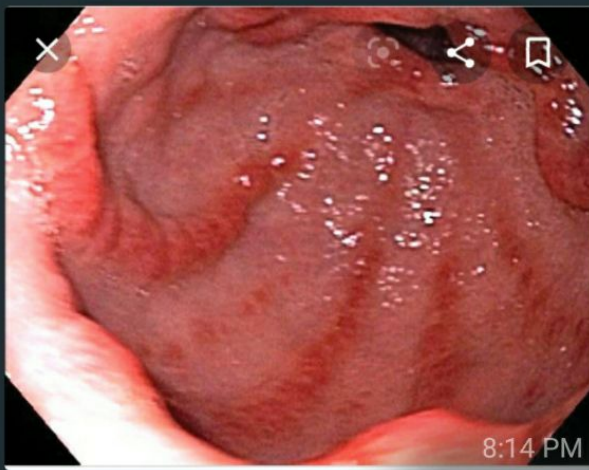
👍👍 8:12 PM

Best endoscopic rx ? 8:12 PM

👍  
Band ligation 8:13 PM

Dr. Nadia khamees  
Another melena case 8:14 PM

Dr. Nadia khamees



Gave 8:14 PM

Dr. Nadia khamees

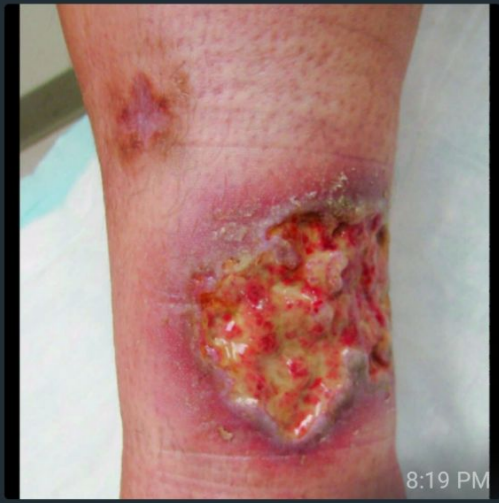👍 8:16 PM

Gastric antral vascular ectasia 8:16 PM

Water melon appearance 8:17 PM

A 24 years old female with this skin lesion , who has bloody diarrhea . 8:19 PM

Dr. Nadia khamees



Pyoderma gangrenosum 8:19 PM

IBD? 8:20 PM

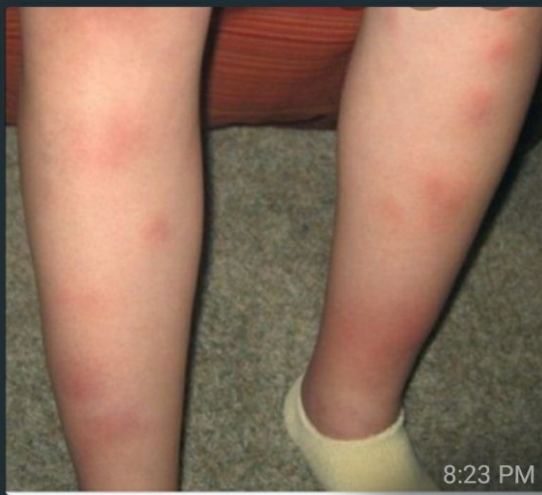Dr. Nadia khamees

Pyoderma gangrenosum to more associated with UC than CD 8:21 PM

Also the hx of bloody diarrhea is more consistent with UC 8:22 PM

A 37 years old male patient with chronic abd pain , who has this skin rash 8:23 PM

Dr. Nadia khamees



Eryhtema nodosum 8:23 PM

Dr. Nadia khamees

Eryhtema nodosum



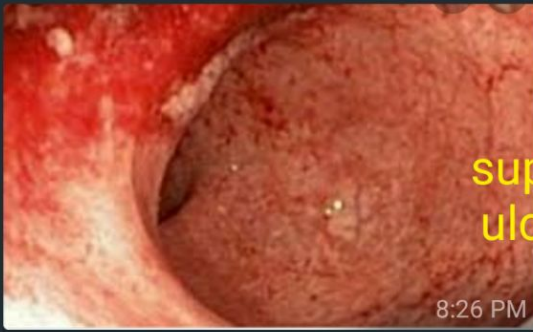8:24 PM

Mostly crohns disease 8:24 PM

Both of the above mentioned patients underwent colonoscopy . Both images are shown 8:26 PM

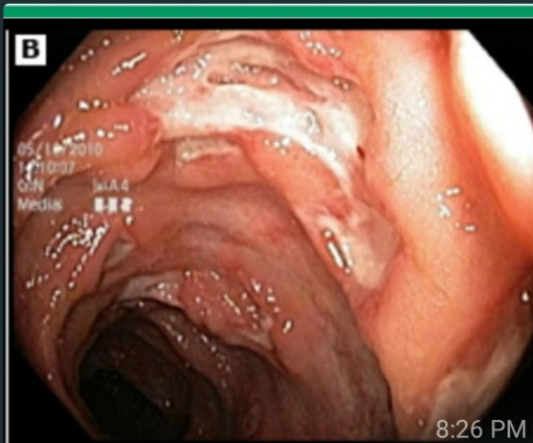Which one is for UC or CD 8:26 PM

Dr. Nadia khamees



UC  
superficial  
ulceration

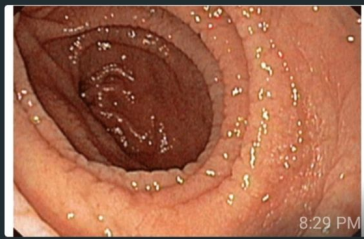Dr. Nadia khamees



CD

A 24 years old male patient with diarrhea of 2 years .Found to have iron def anemia . His EGD Is shown 8:29 PM

Dr. Nadia khamees



Celiac 8:29 PM

Dr. Nadia khamees

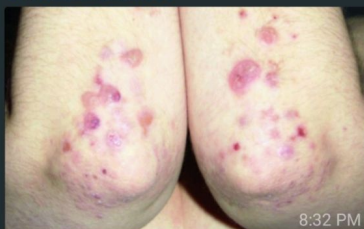What is the serology test to be send? 8:31 PM

Anti tissue transglutaminase IgA 8:31 PM

Dr. Nadia khamees

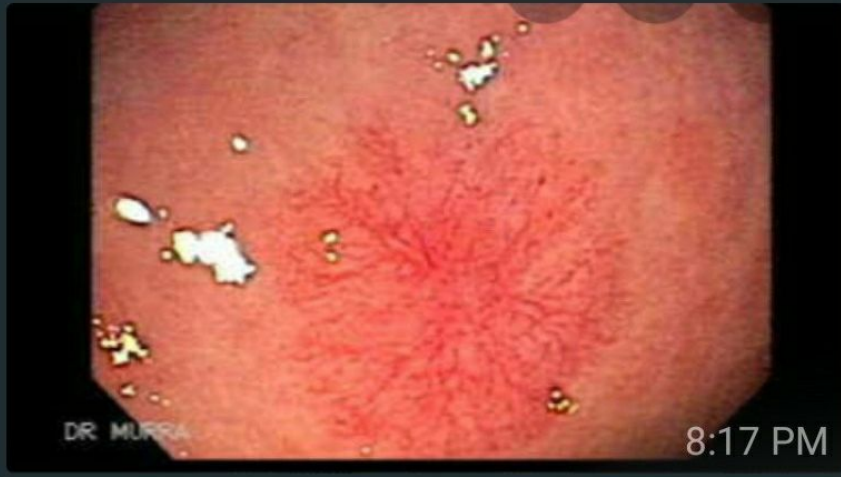He has also this skin rash 8:32 PM

Dr. Nadia khamees



Dermatitis herpetiformis 8:33 PM

Dr. Nadia khamees



What about this ? 8:17 PM

Angiodysplasia 8:17 PM

Dr. Nadia khamees



8:17 PM

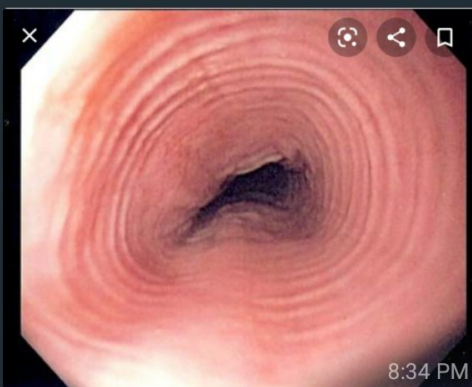Dr. Nadia khamees

A 16 years old male patient with dysphagia

8:34 PM

This is his EGD 8:34 PM

Dr. Nadia khamees



Eosinophilic esophagitis 8:35 PM

كيف منعرف من دون biopsy !!! 8:35 PM

Dr. Nadia khamees

كيف منعرف من دون biopsy !!!

Of course your definitive dx is by bx  
But this EGD shows trachealisation  
His age and gender

8:36 PM

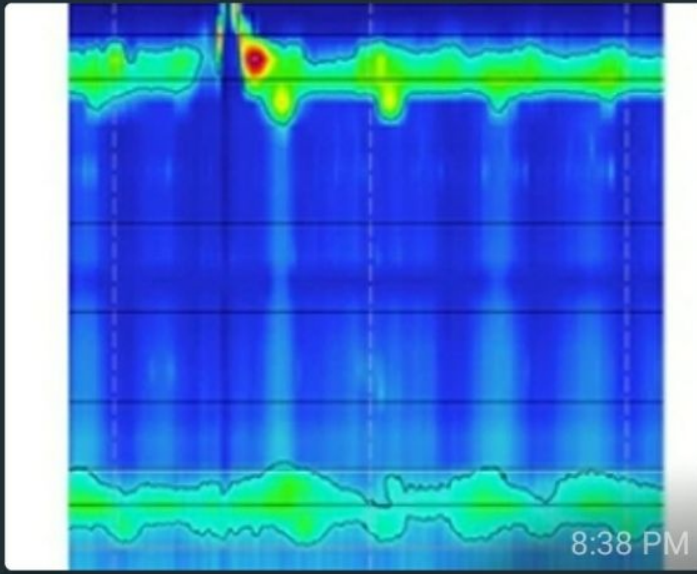
A 42 years old male patient with dysphagia

8:37 PM

Underwent manometry 8:37 PM

That is shown below 8:38 PM

Dr. Nadia khamees




Achalasia type 1

8:38 PM

Another manometry 8:39 PM

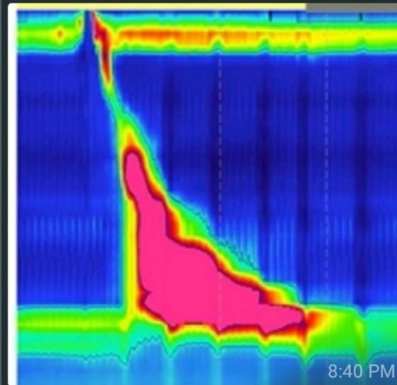
Dr. Nadia khamees



Achlasia type 2

8:40 PM

Dr. Nadia khamees



Type 3 achalasia

8:40 PM