

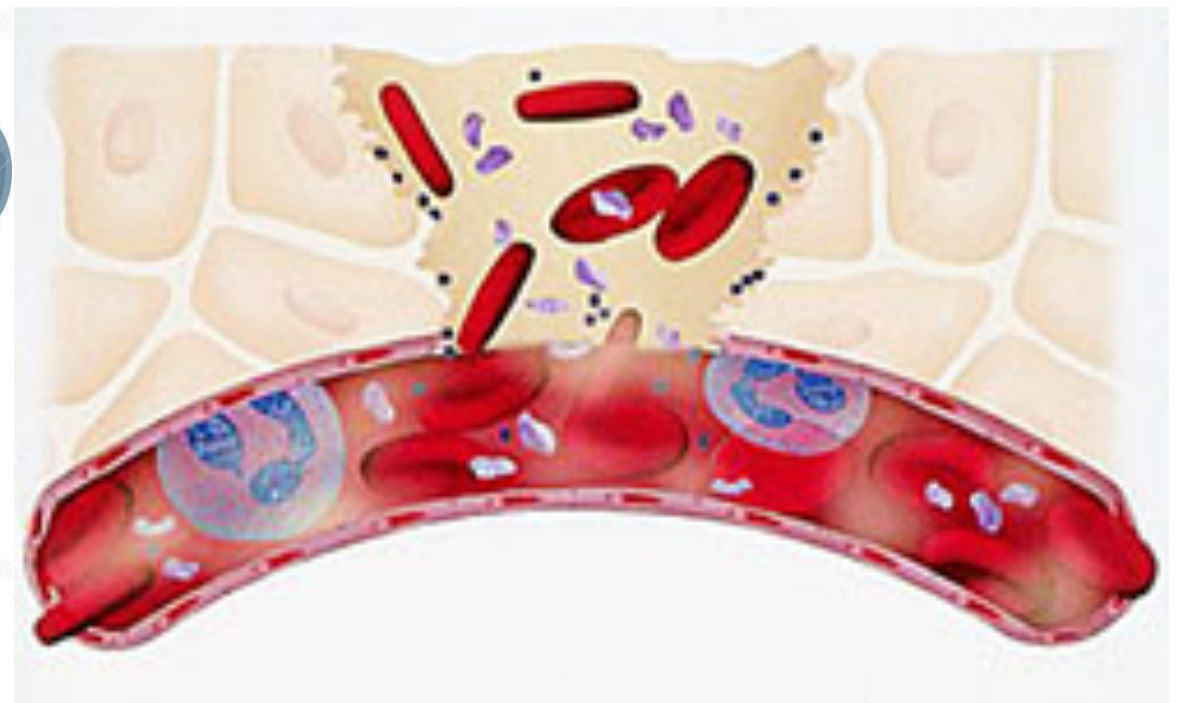
CNS pathology

Third year medical students

Dr Heyam Awad

brain haemorrhage

Traumatic vs non traumatic



Download from
Dreamstime.com

This watermarked comp image is for previewing purposes only.

ID 41750379

Brett Lamb | Dreamstime.com

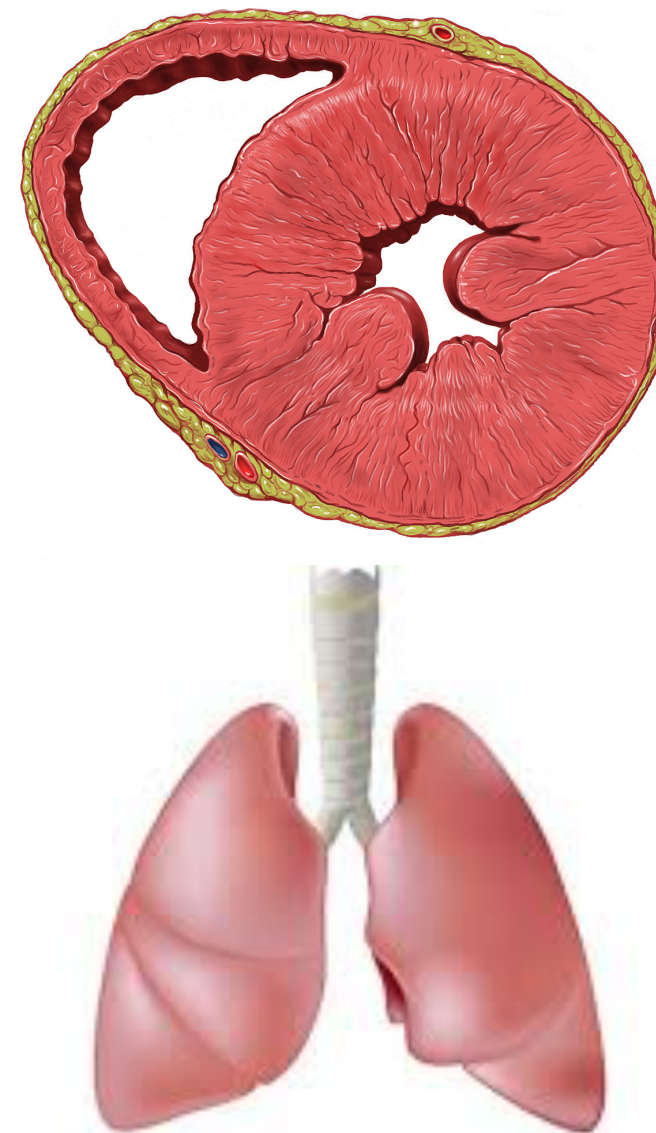
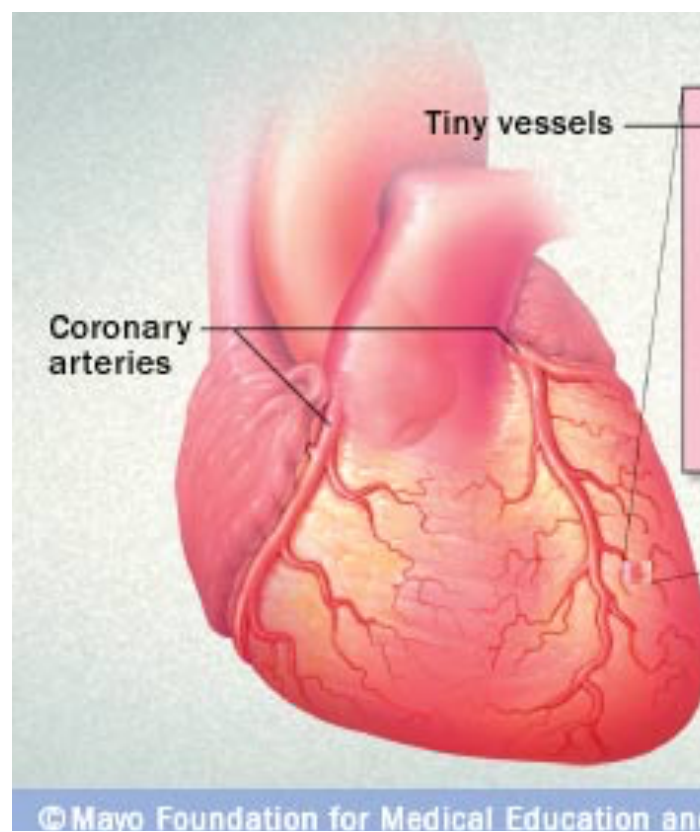
Case 1

- Mr H (65 years old) was enjoying a vacation in Hawaii with his wife to celebrate their 30th marriage anniversary. While having dinner he told his wife that he felt a sudden headache but continued eating!! a few minutes later he unfortunately died.

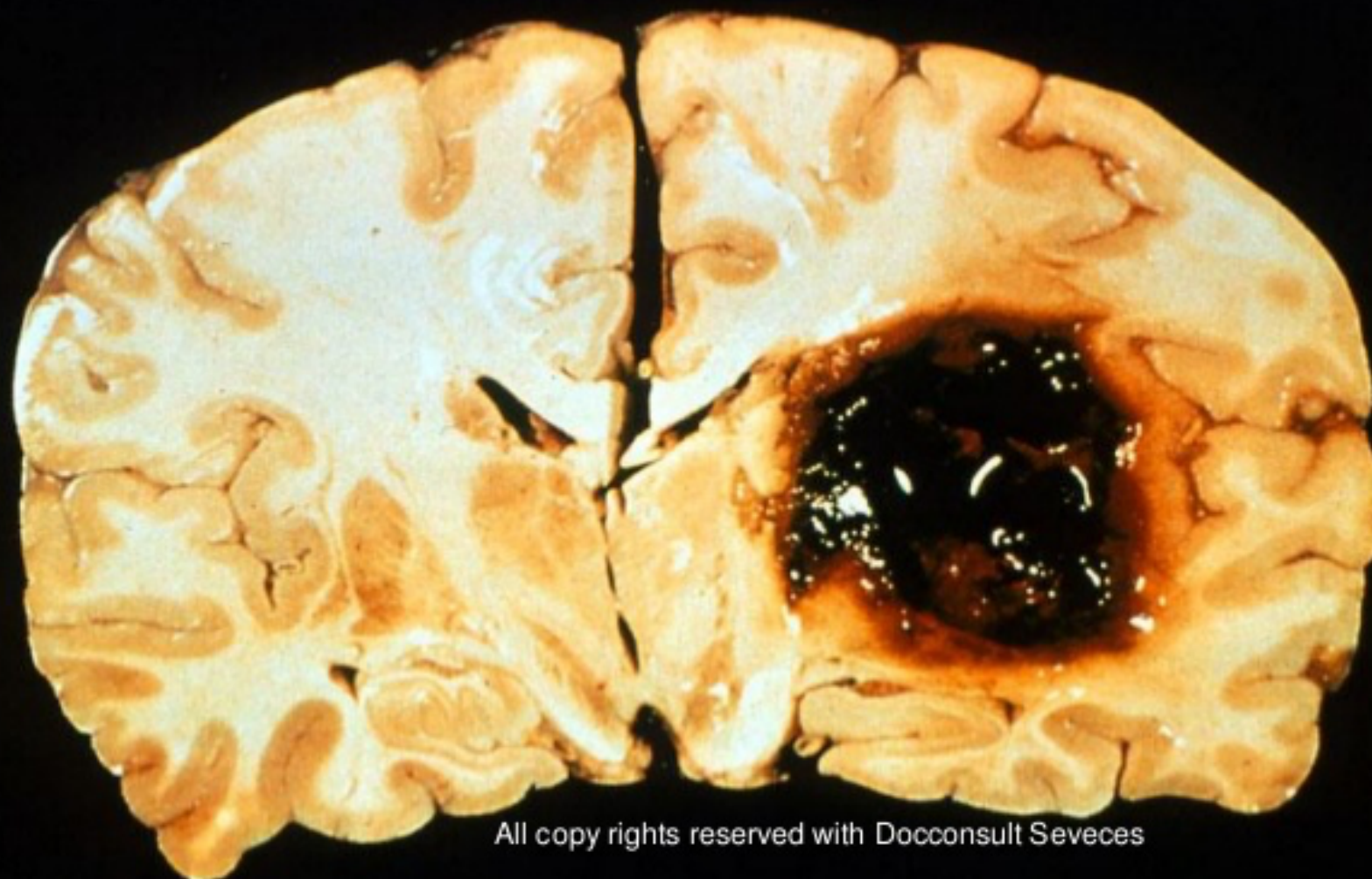


- Mr H was taken to hospital where death was confirmed.
- What's the next step doctors should take?

- An autopsy was performed.
- What organ systems must the pathologist focus on while undertaking the autopsy in this case?



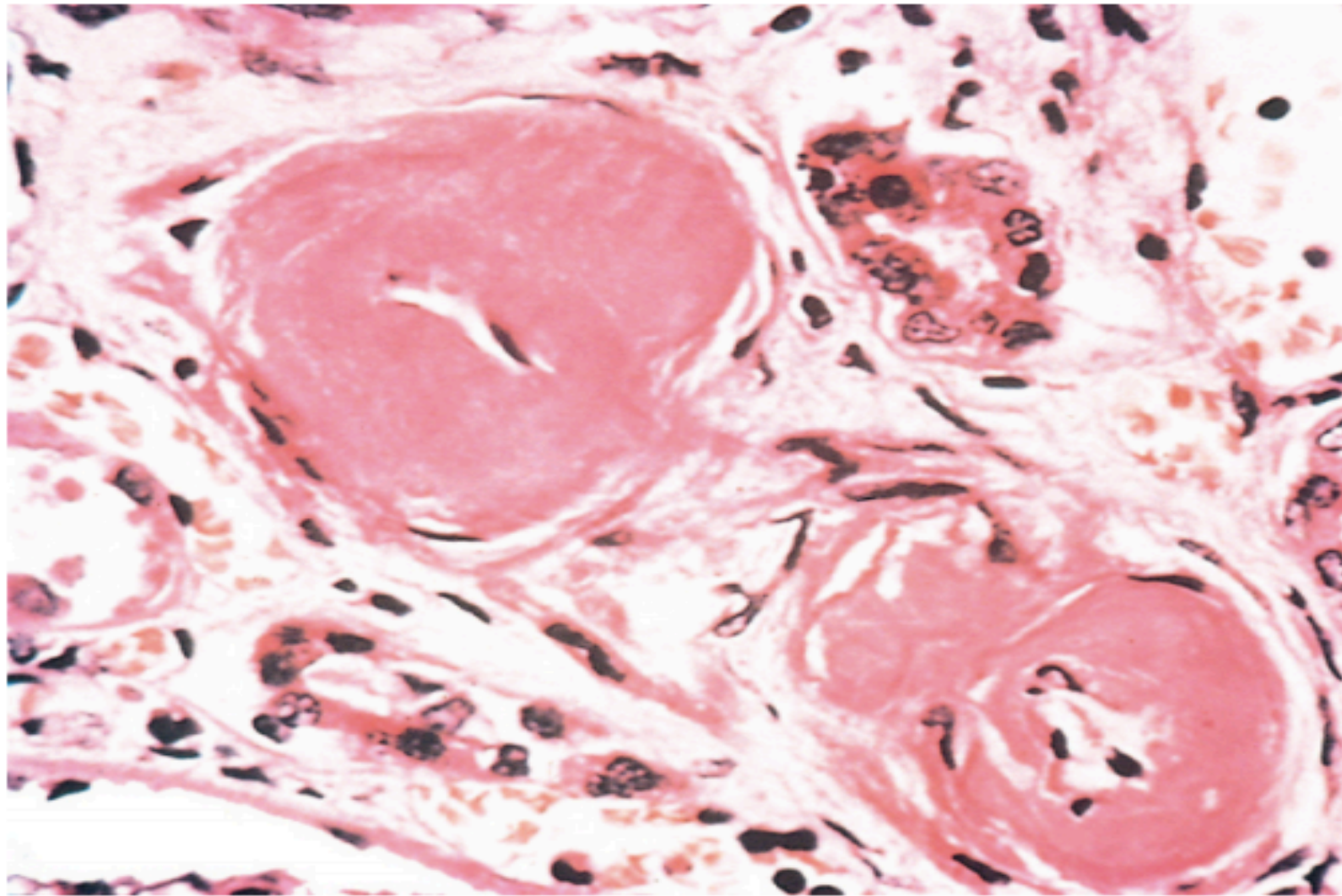
AUTOPSY OF INTRACEREBRAL HEMORRHAGE



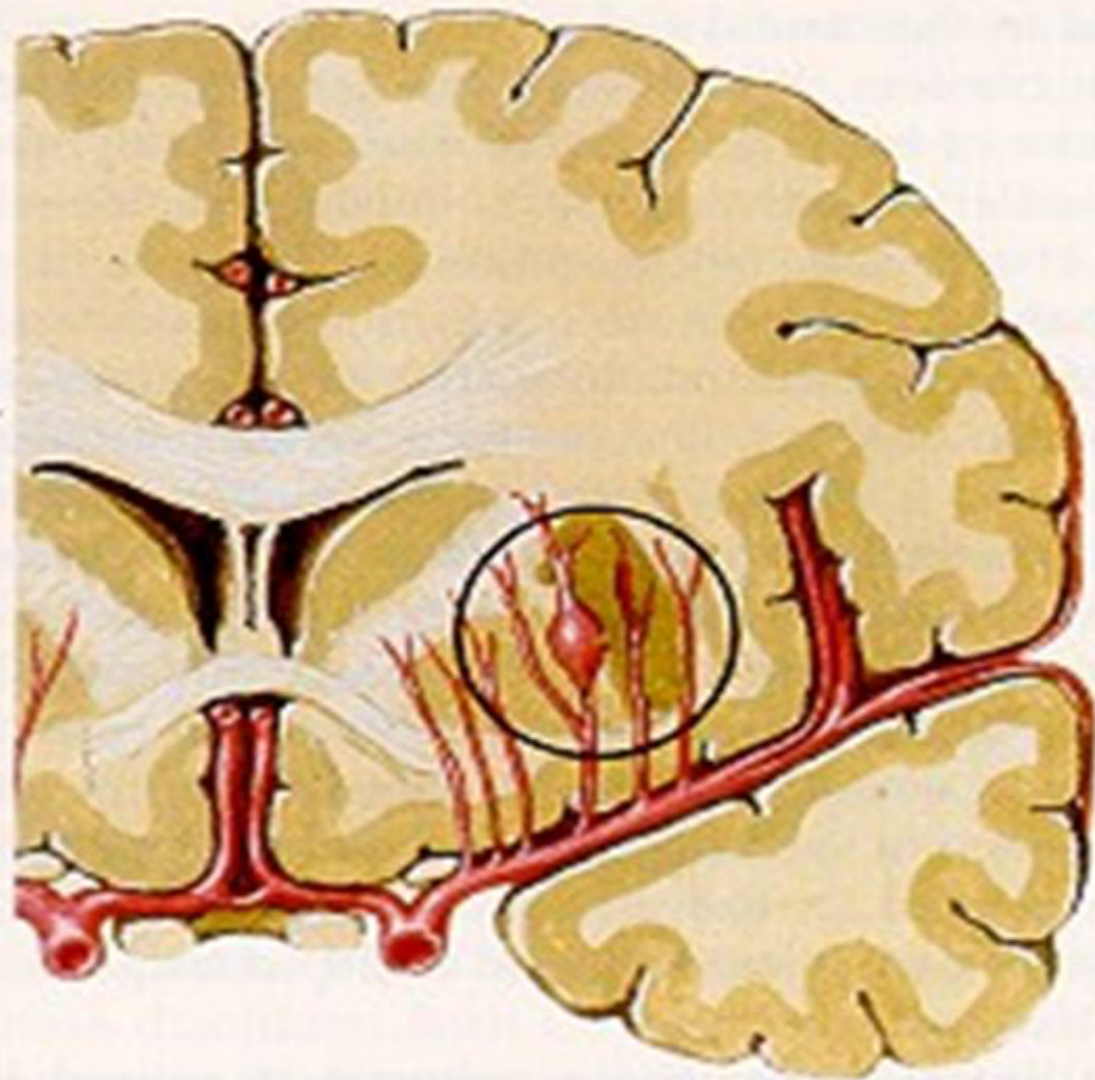
All copy rights reserved with Docconsult Seveces

- What is the cause of death.
- What is the underlying cause?
- How can hypertension cause haemorrhage?

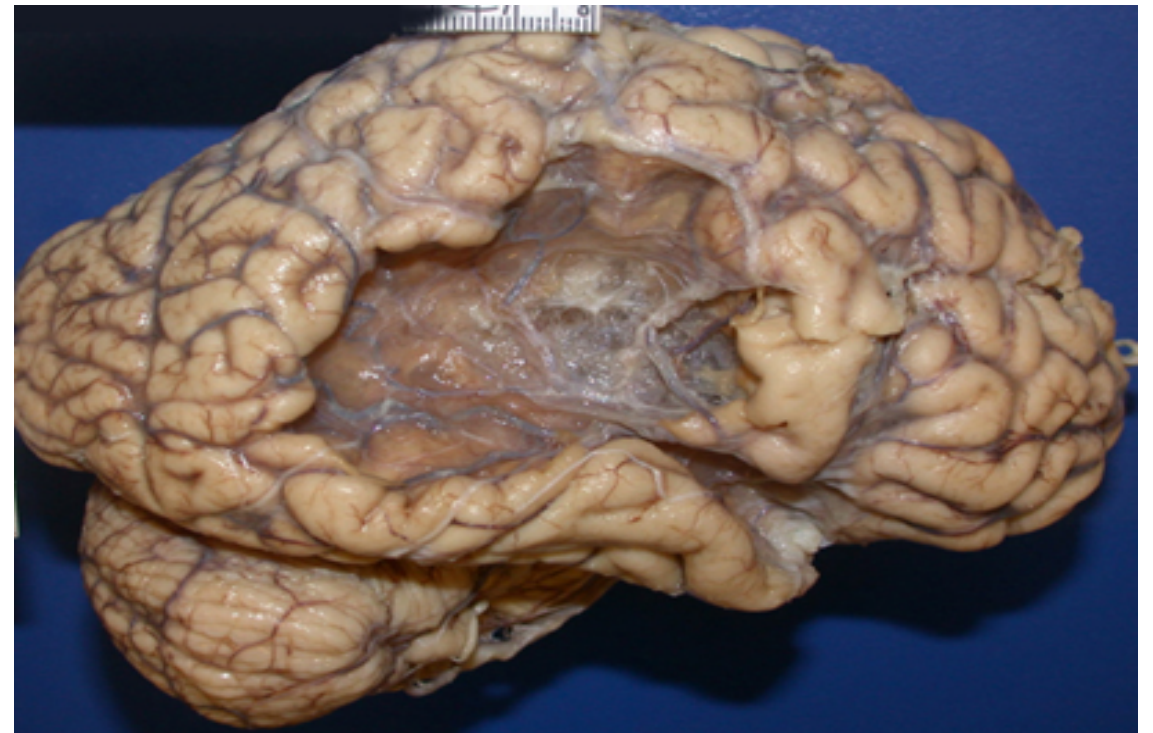
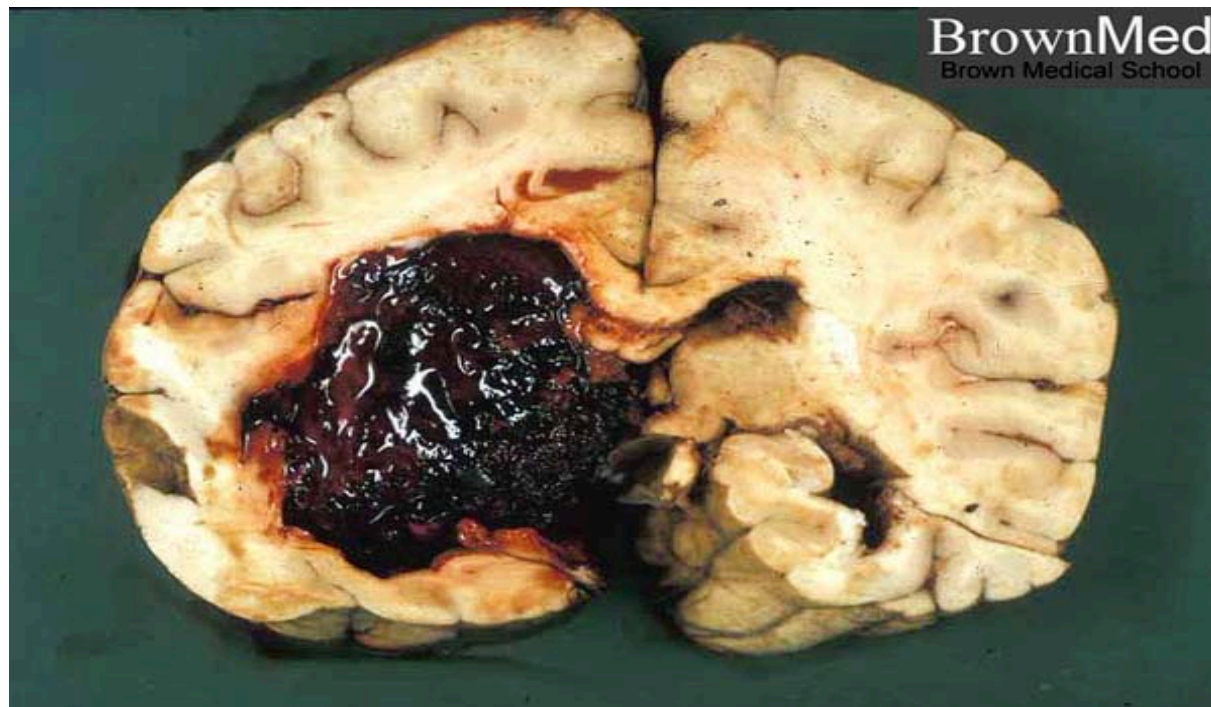
Hyaline arteriolosclerosis



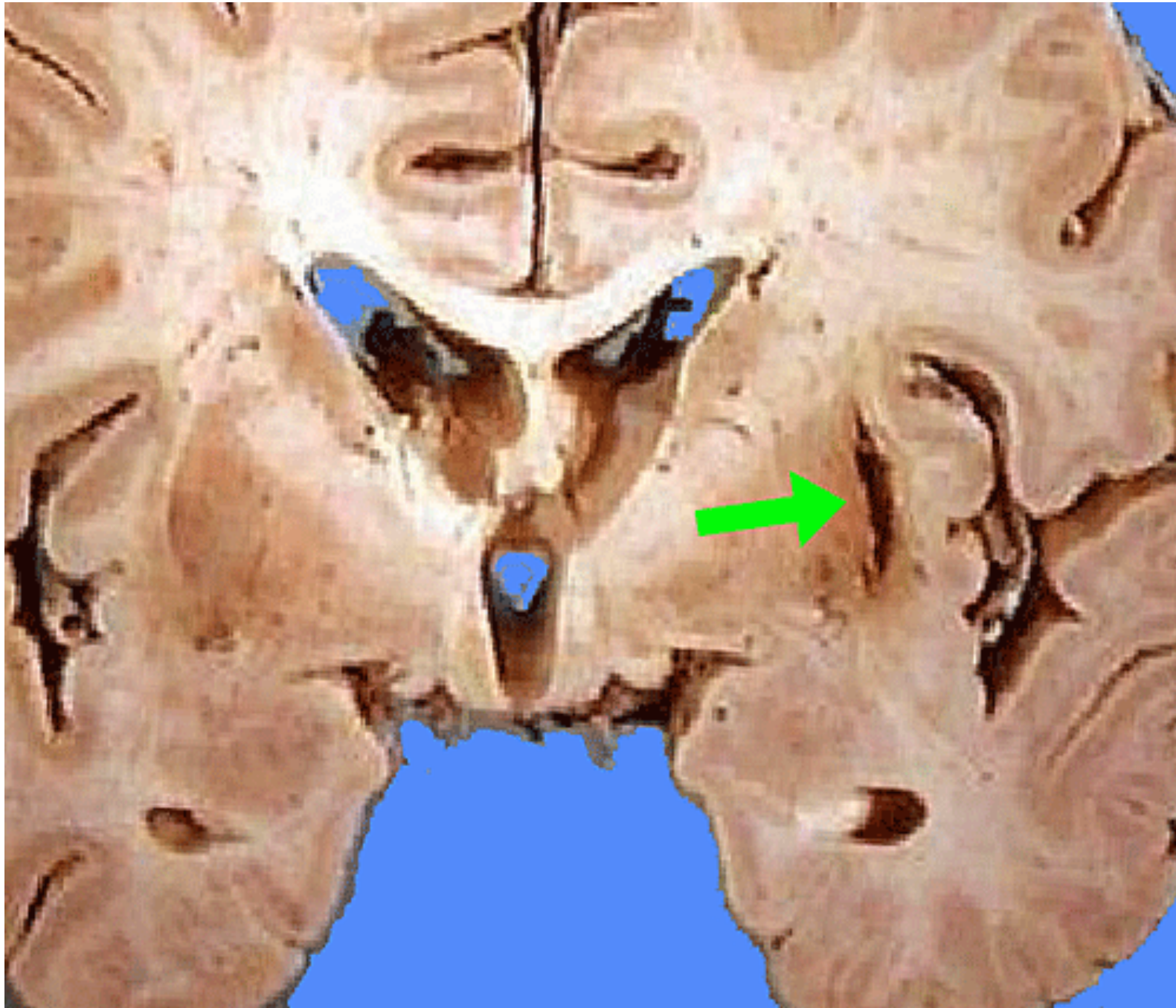
**Microaneurysms
in penetrating
arteries**



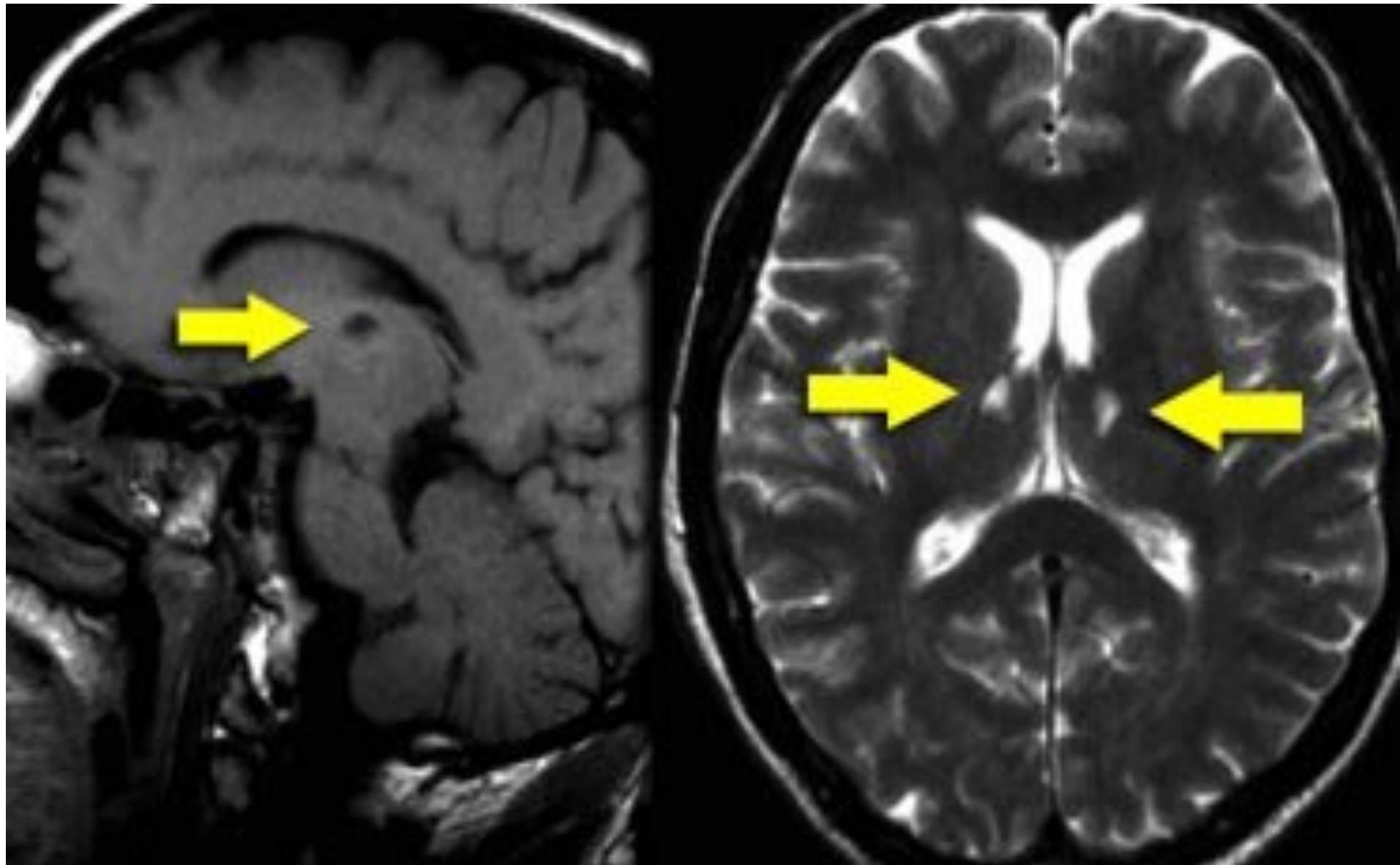
Brain haemorrhage



slit haemorrhage



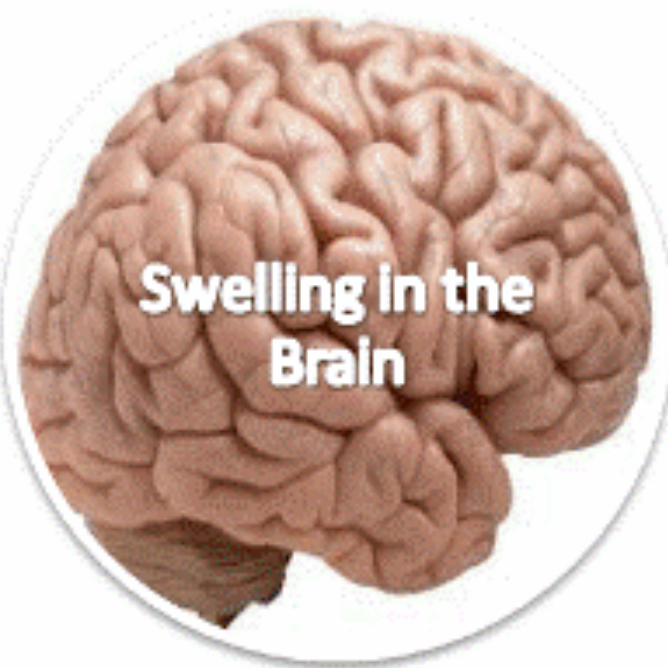
Lacunar infarct



**Hypertensive
Encephalopathy**



**Swelling in the
Brain**



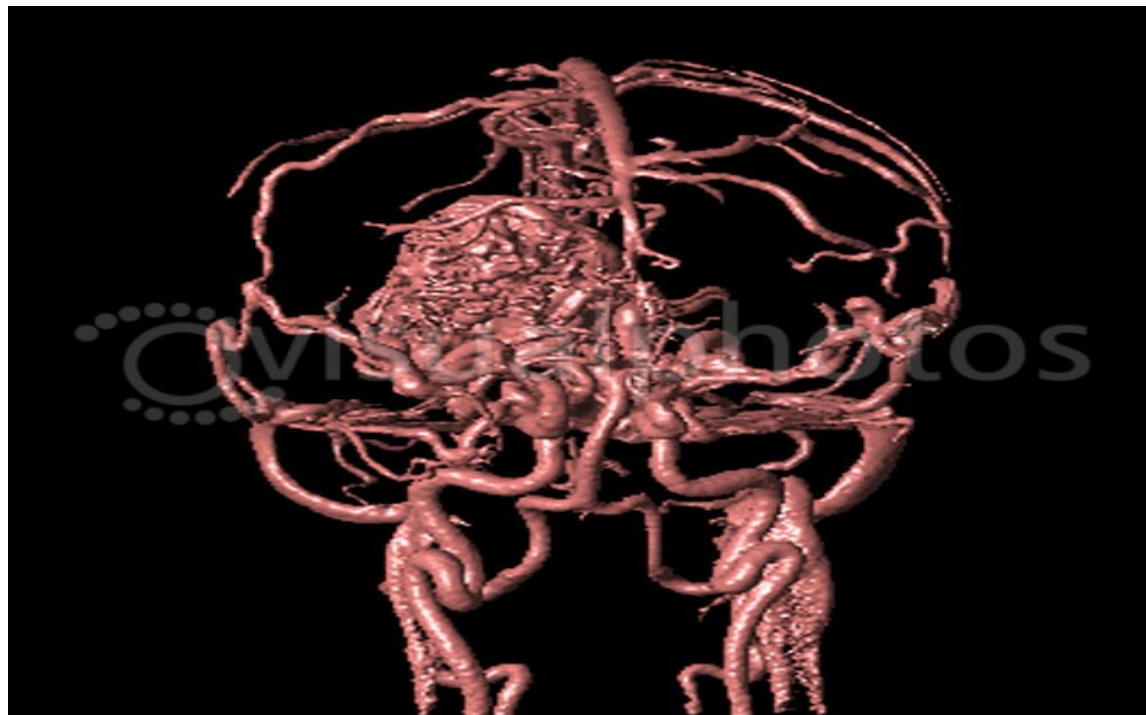<http://papahealth.com/>

Take home message

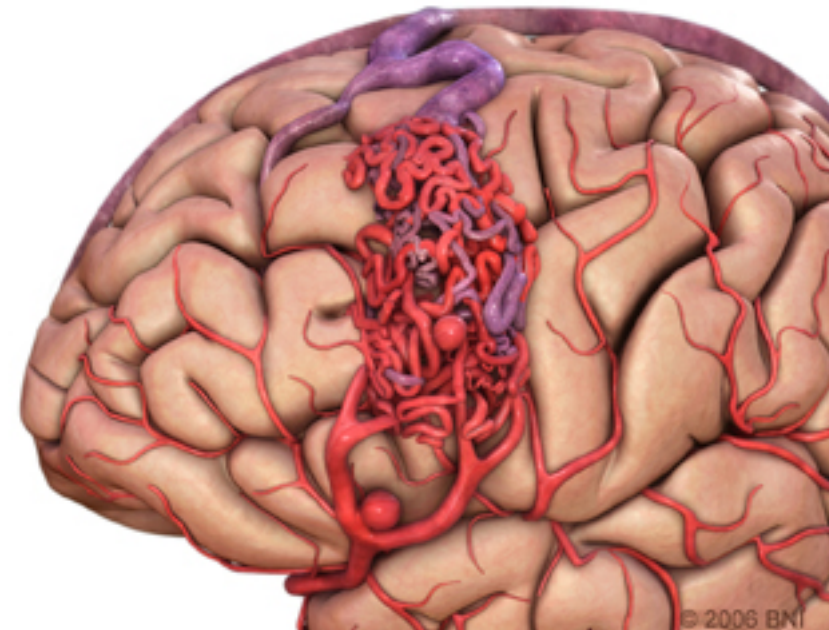


case 2

- A 16 year old boy had seizures for the past two years. The school called his mum to collect her son who had a **severe headache and then vomited**.
- His mother took him to the hospital and a CT scan was performed that showed an intracerebral haemorrhage
- What's the most likely cause ?



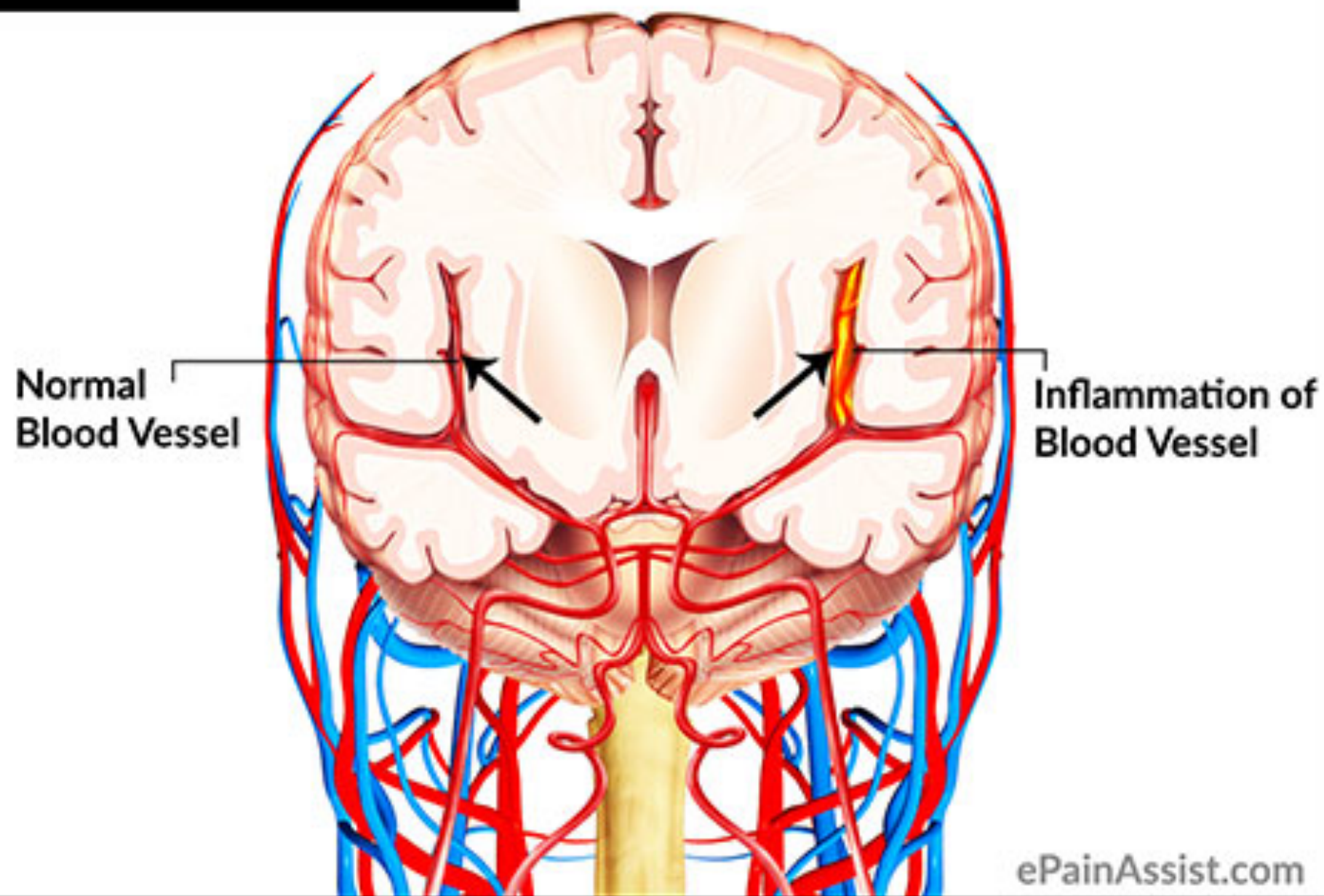
M1360300 [RM] (c) www.visualphotos.com



case 3

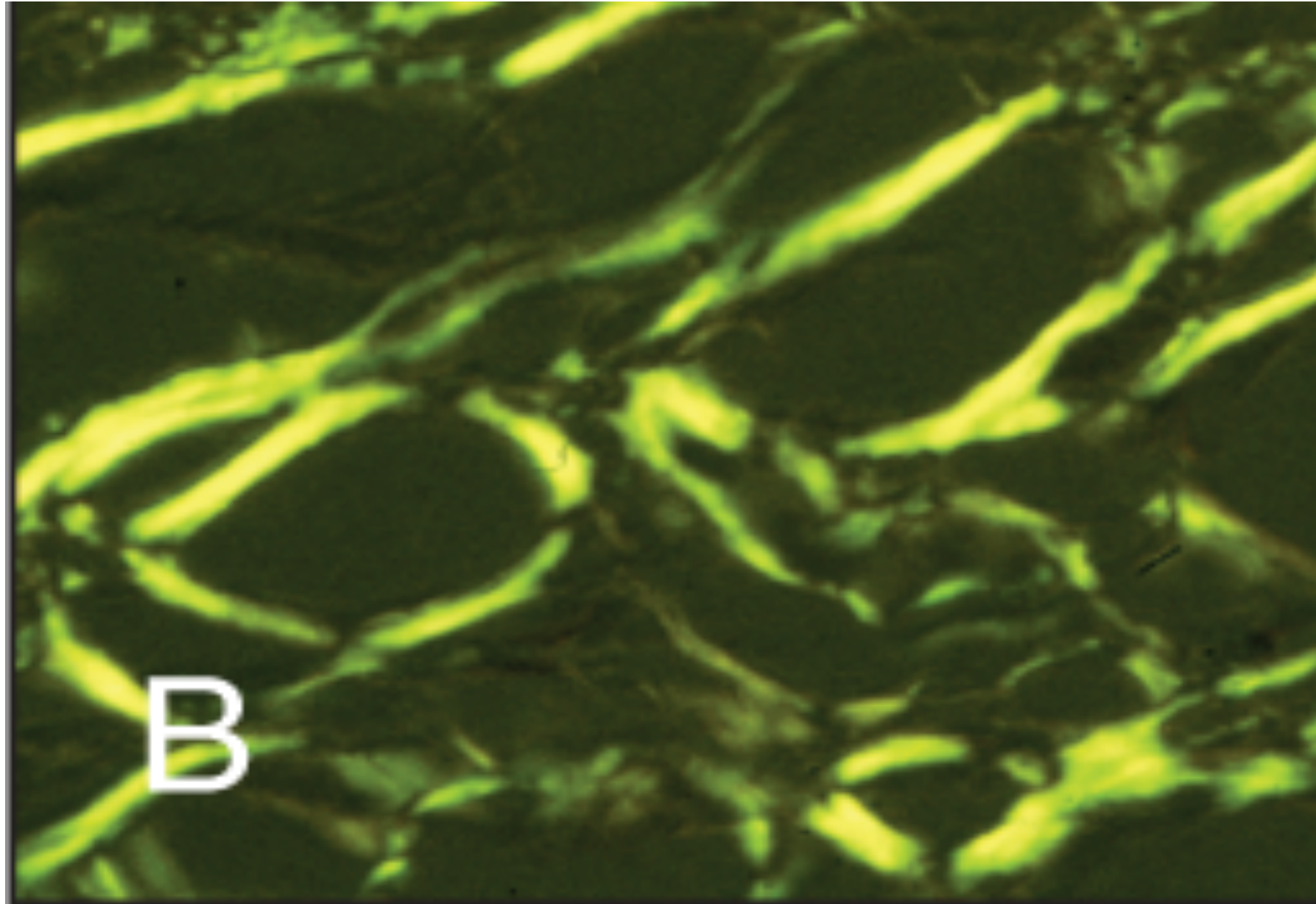
- A 32 year old male, known of having HIV infection, had neurological symptoms which on investigation were found to be due to an intracerebral haemorrhage
- ? Cause

Cerebral Vasculitis



case 4

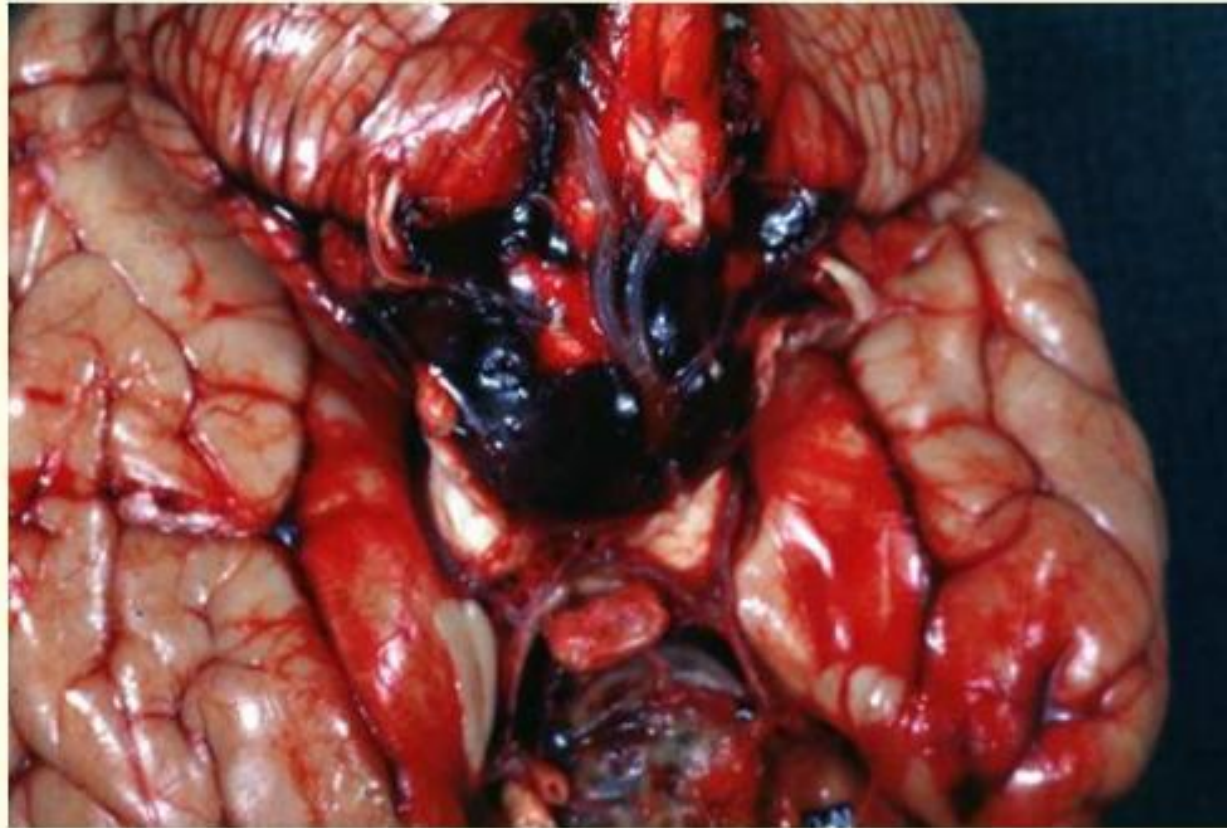- A 45 year old woman with a long standing history of rheumatoid arthritis developed weakness in her right leg which was followed by headache and vomiting. On examination her blood pressure was 180/95, heart rate 40/ minute and you noticed shallow breathing.
- CT scan showed an intracerebral haemorrhage, can you suggest a cause???



Case 5

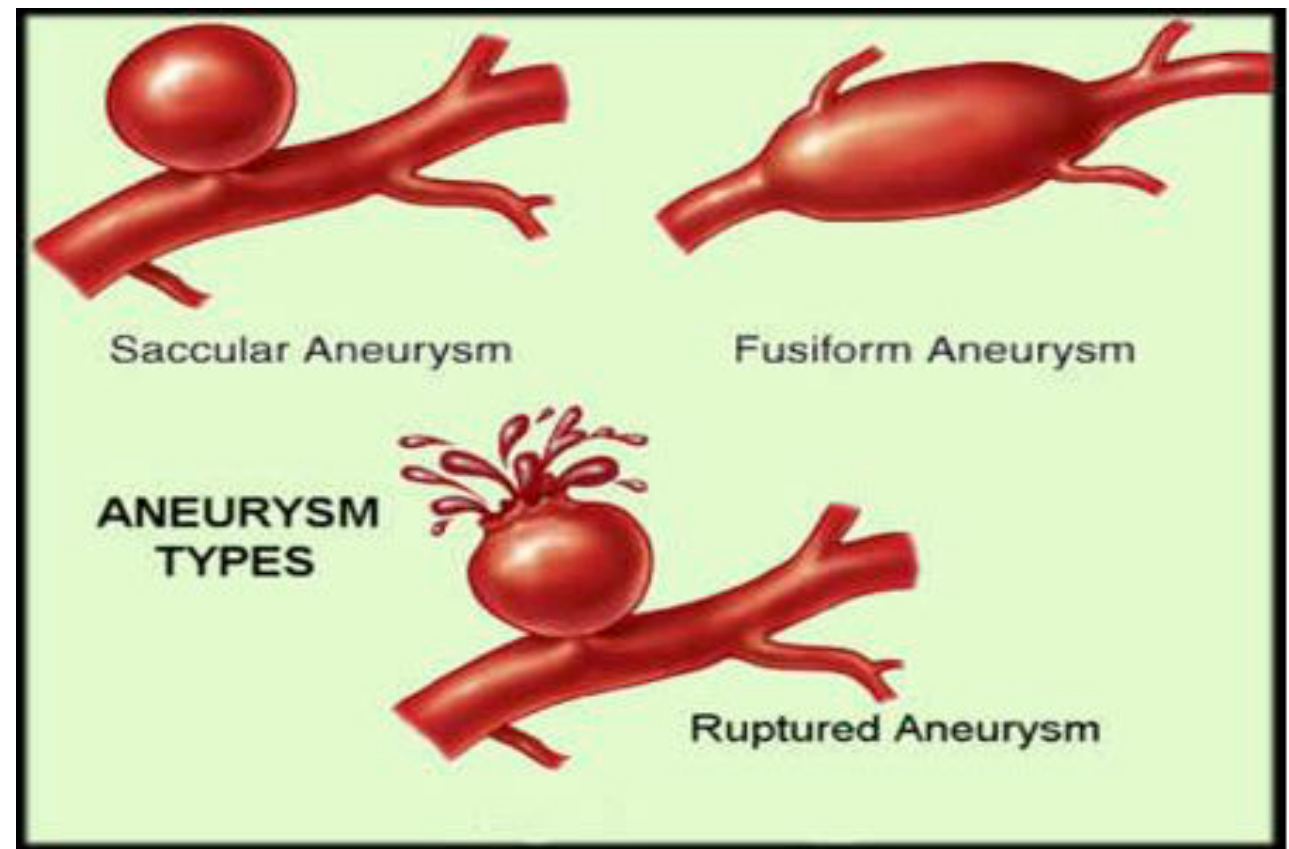
- A 77 year old woman who is known to be a diabetic and hypertensive suffered from sudden severe headache which she described as the worst headache in her life. She was rushed to hospital and CT scan showed subarachnoid haemorrhage.
- What is the most common cause of subarachnoid haemorrhage??

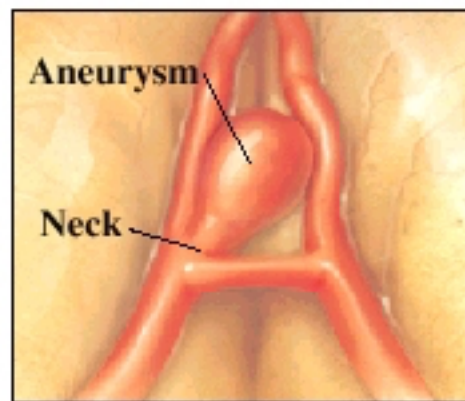
Subarachnoid Hemorrhage



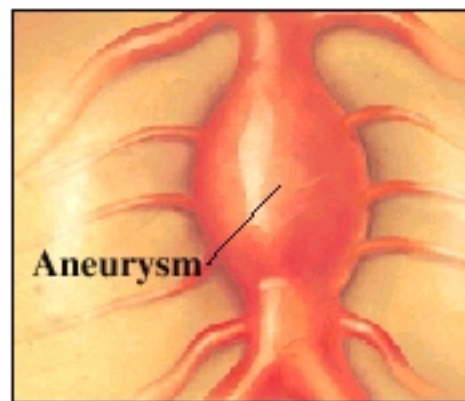
*** Restricted use. PEIR; University of Alabama at Birmingham, Department of Pathology**

Subarachnoid haemorrhage

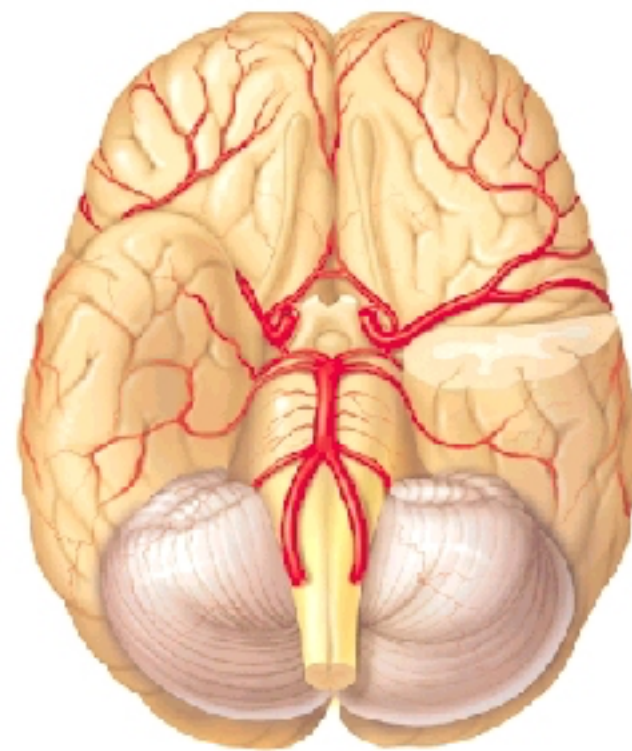




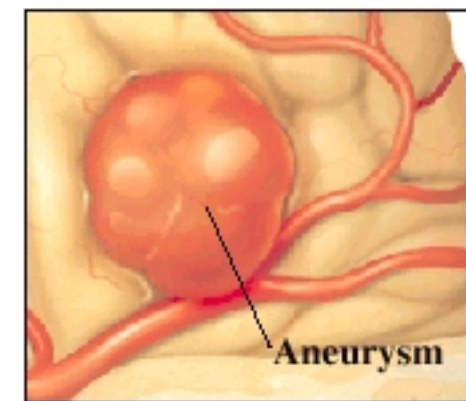
A **saccular (berry) aneurysm** bulges from one side of an artery. A neck leads to it.



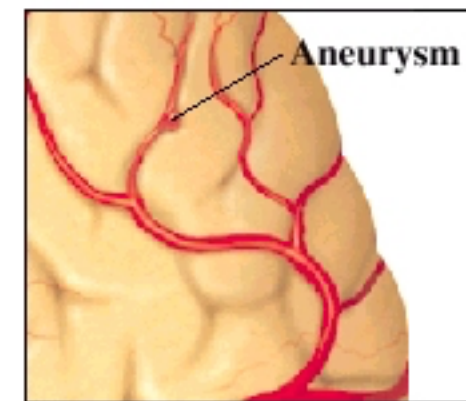
A **fusiform aneurysm** bulges from all sides of an artery. It rarely has a neck.



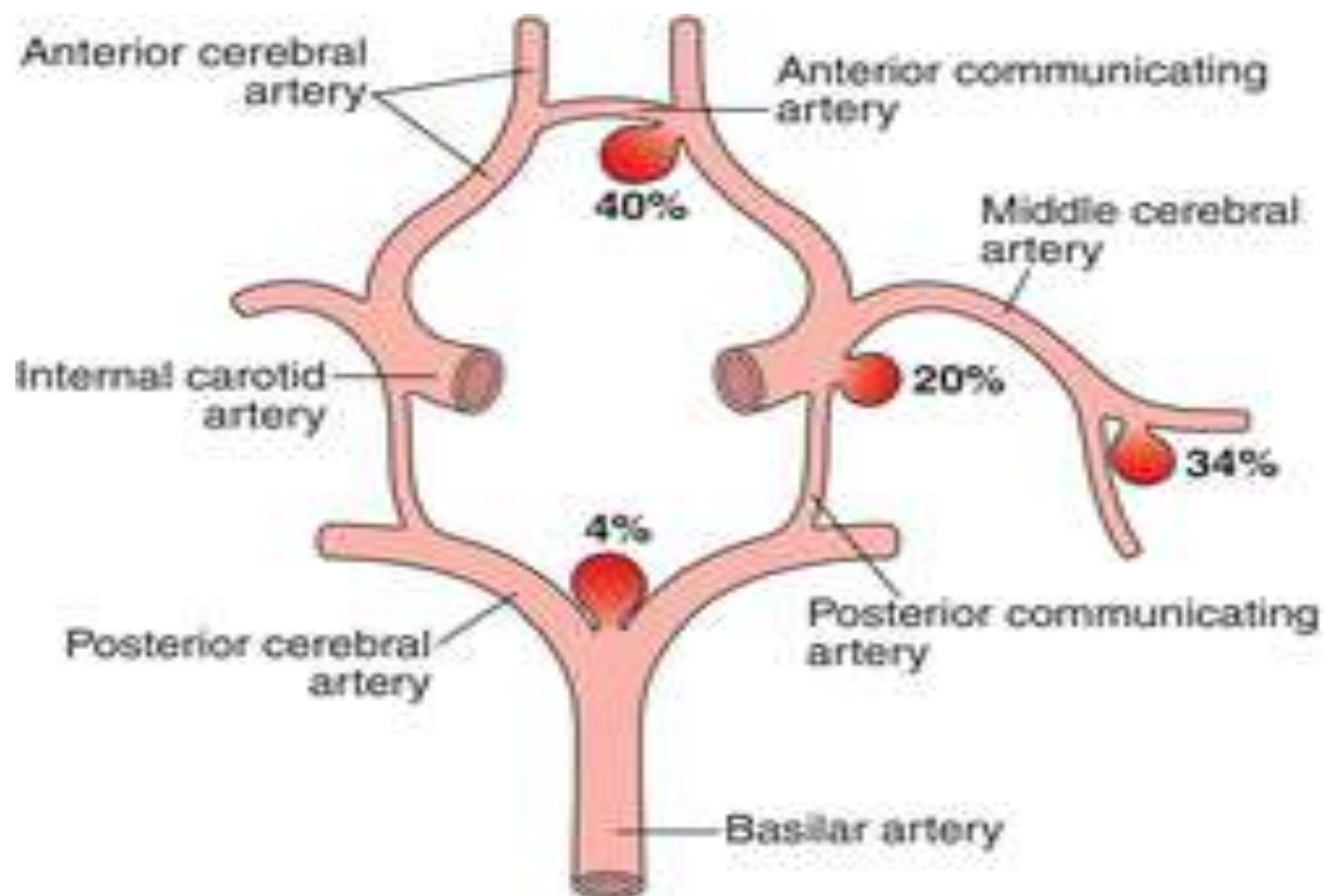
Using this picture, the surgeon may mark the site of the aneurysm.



A **giant aneurysm** can involve more than one artery. It is over 2.5 centimeters (cm) wide.



A **mycotic aneurysm** is caused by an infected artery wall. This type of aneurysm is fairly rare.



Traumatic haemorrhage

