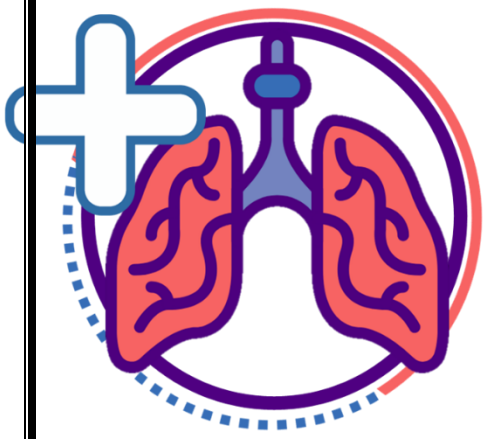

RESPIRATORY SYSTEM

Anatomy

Sheet Slide

Number:	-2 Histology
Done by:	-Abdulrahman Al-Hanbali
Corrected by:	-Marah Karablieh
Doctor:	-Mohammed Al-Muhtaseb

In the last histology lecture, we started talking about the respiratory tract and we talked about the upper respiratory tract (nasal cavity, nasal sinuses, trachea, bronchi and we started talking about bronchioles). In this lecture we will talk about the lower respiratory tract, which consists of:

- Bronchioles,
- Respiratory bronchioles,
- Alveolar ducts
- And Alveoli

We will talk also about the respiratory membrane, gas exchange across it, surfactants and pleura.

Bronchioles:

They are the continuation of the bronchi however there are some major differences between them;

- Unlike bronchi, bronchioles don't have any **cartilage** in the supporting layer.
- They don't have **glands** in their mucosa (initially, there might be 1-2 glands in the mucosa of a large bronchiole. However, as we proceed, there won't be any).
- The same thing applies on **goblet cells,** initial segments may contain scattered goblet cells, but they are absent distally.
- Bronchioles don't have **lymphatic nodules** (it's written "No lymphocytes "in the slides, the doctor said that's a mistake as lymphocytes are present in every part of the respiratory tract).

Additional:

Bronchioles are formed about the 10th generation of branching.

Bronchioles have small diameter; about 1mm in large bronchioles and may be as small as 0.5mm in small ones. (In the slides, it's written that bronchioles are 5mm or less; I think it's a mistake as the doctor said they are 1mm or less). Smaller bronchioles then divide into **terminal bronchioles,** these are the last component of the conducting zone of the respiratory tract.

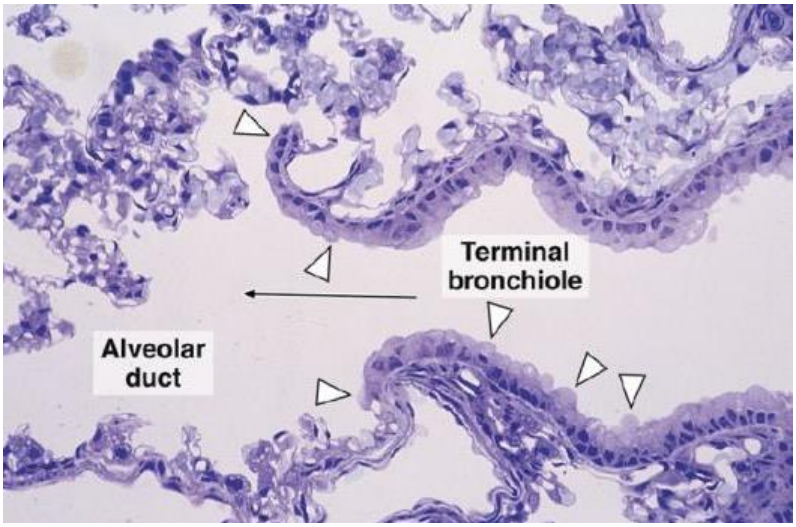

The lining epithelium of the initial (large) bronchioles is **ciliated pseudostratified columnar**, it will change gradually into **ciliated simple columnar** and finally it will become **simple cuboidal ciliated with Clara cells** in the terminal bronchioles.

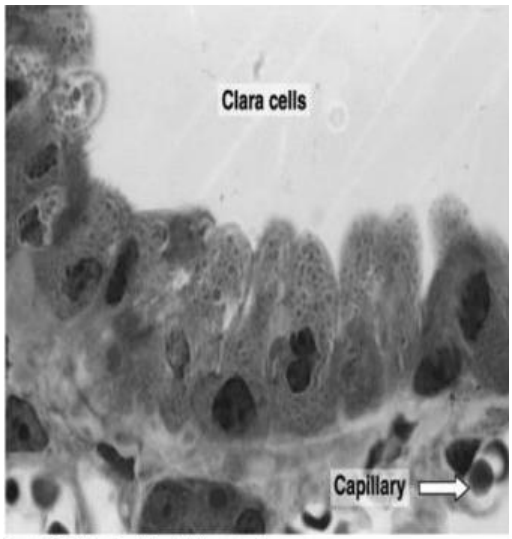

Clara cells: simple cuboidal non-ciliated cells.

- They're present in respiratory bronchioles in high number.
- They have secretory granules in their apex.
- known to secrete proteins that protect the bronchiolar lining against oxidative pollutants and inflammation.
- They produce one of the components of the surfactants and also act as reserve cells.
- They also seem involved in the reparative process of airway epithelial cell renewal after injury.

Bronchioles also exhibit specialized regions called **neuroepithelial bodies:**

- groups of cells (80-100) that contain secretory granules and receive cholinergic nerve endings.
- Their function is poorly understood, but they are probably chemoreceptors that react to changes in gas composition within the airway.

This part of the slides wasn't mentioned by the doctor

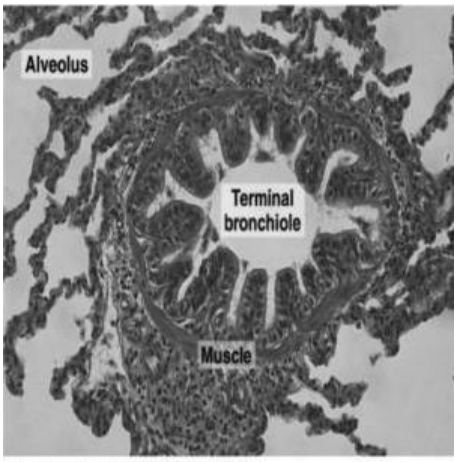

In bronchioles, **Lamina Propria** is composed largely of smooth muscle and elastic fibers with no cartilage, that's why it looks folded. **Smooth muscle cells** are organized in a circular/spiral shape in the lamina propria. These smooth muscles are of a great importance as they are the main contributor of bronchoconstriction in **Asthma** patients. This bronchoconstriction will cause **wheezing** in those patients.

These smooth muscles are under the control of the **Vagus nerve** (parasympathetic) [which will make them contract→ bronchoconstriction] and the **sympathetic nervous system** [which will make them relax→ bronchodilation], and that's why we use subcutaneous epinephrine to treat acute asthma attacks.

Additional:

A wheeze is a whistling sound due to an obstruction or narrowing of the respiratory airways.

https://www.easyauscultation.com/cases?coursecaseorder=4&courseid=201

Respiratory bronchioles:

Each terminal bronchiole subdivides into two or more respiratory bronchioles which serve as regions of transition between the conducting and respiratory portions of the respiratory system. They are always surrounded by **blood vessels**; either branches of pulmonary arteries or pulmonary veins tributaries.

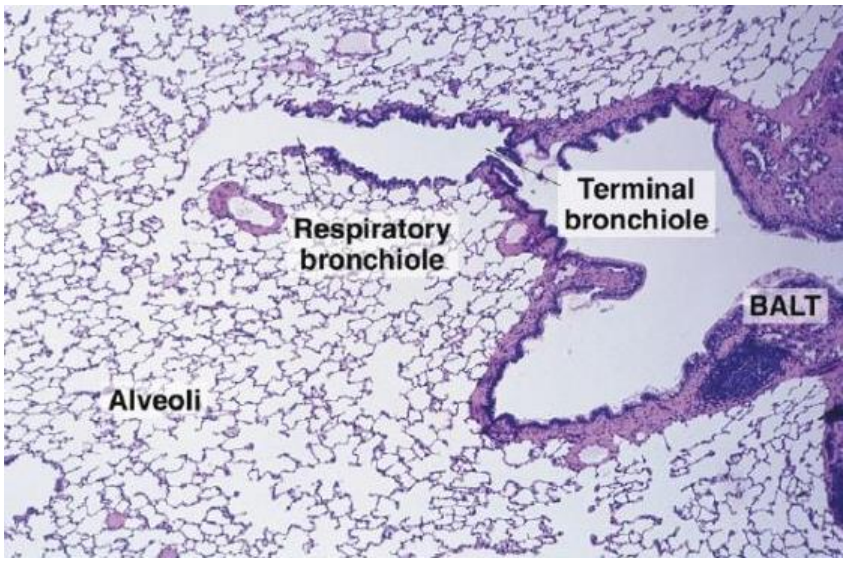

Its mucosa is structurally identical to that of the terminal bronchioles- ciliated simple cuboidal epithelial cells and Clara cells, but at the alveolar openings the bronchiolar epithelium becomes continuous with the squamous alveolar lining cells. Smooth muscle and elastic connective tissue lie beneath the epithelium.

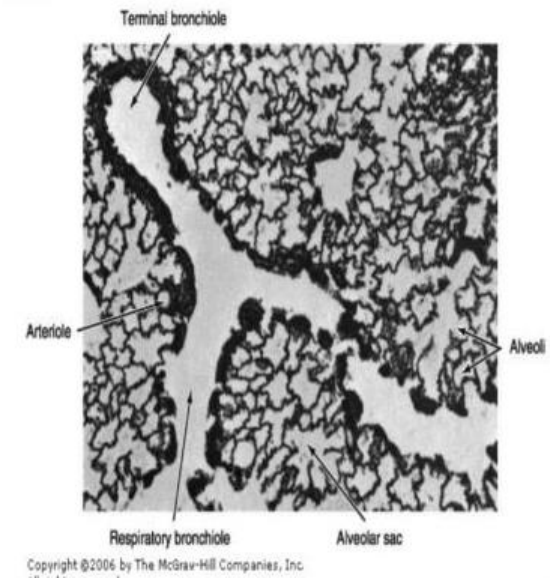

They open upon **alveolar ducts** (unlike terminal bronchioles which are closed), their walls are interrupted by numerous saclike alveoli where gas exchange occurs. (from slides): Between alveoli, the bronchiolar epithelium consists of ciliated cuboidal epithelium.

In respiratory bronchioles there isn't any cartilage nor mucosal glands/goblet cells.

They contain very little amount of smooth muscle cells which form **small knobs**.

As smooth muscles decrease, elastic and reticular fibers increase. Elastic fibers help in inflation of the lung, while reticular fibers maintain alveoli integrity and prevent rupturing of alveoli.

alveolar ducts:

Both the alveolar ducts and the alveoli are lined with **extremely attenuated squamous alveolar cells**.

In the lamina propria surrounding the rim of the alveoli is a network of smooth muscle cells,these sphincter-like smooth muscle bundles appear as **knobs** between adjacent alveoli. Smooth muscle disappears at the distal ends of alveolar ducts.

A rich matrix of **elastic and reticular fibers** provides the only support of the duct and its alveoli. The elastic fibers enable the alveoli to expand with inspiration and to contract passively with expiration.

Alveolar ducts open into atria that communicate with alveolar sacs.

Notice how the alveoli opens on the alveolar duct and pay attention to the knobs of smooth muscles on the gates of alveoli.

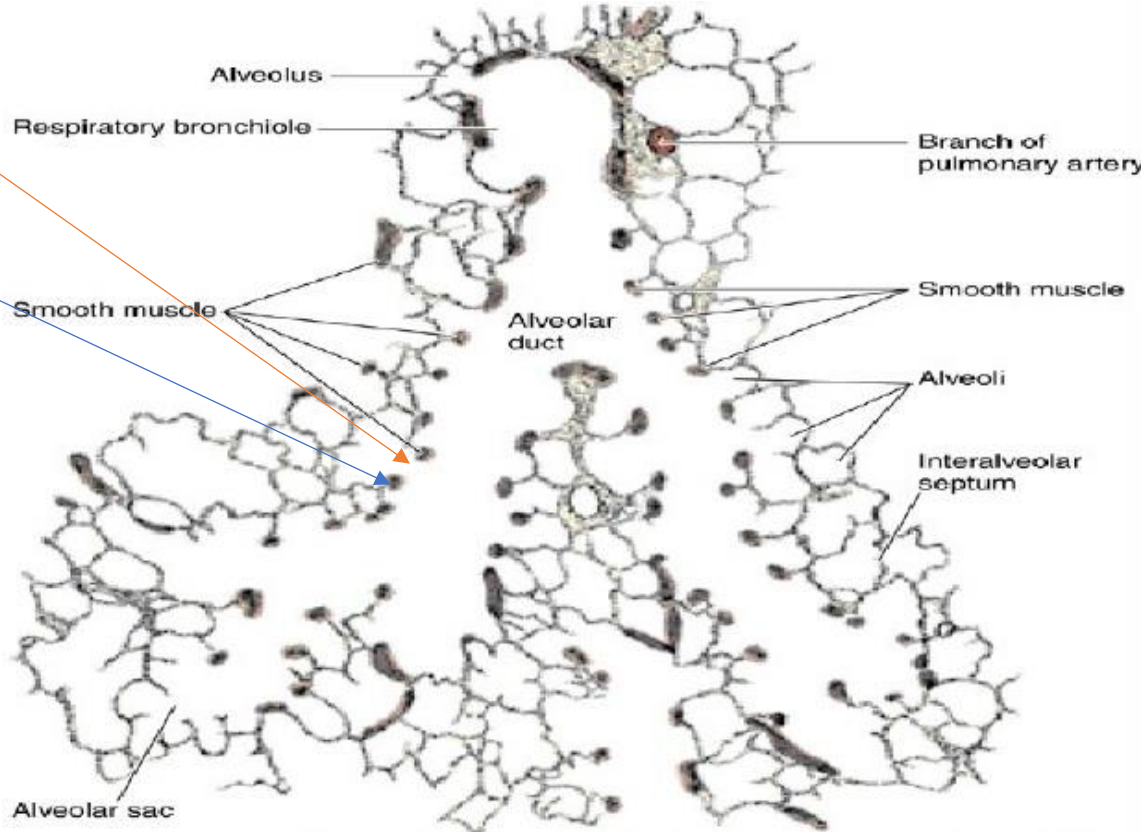

Alveoli:

Alveoli are saclike evaginations (about 200 um in diameter) that are responsible for the spongy structure of the lungs.

The structure of the **alveolar walls** is specialized for enhancing diffusion between neighboring alveoli (internal environments) and between the alveoli and capillaries (external environments). Each wall lies between two neighboring alveoli is called an **interalveolar septum, or wall.**

Interalveolar septum:

An interalveolar septum consists of two thin squamous epithelial layers (type I pnemocytes) between which lie capillaries, elastic and reticular fibers, and connective tissue matrix and cells. At the corners, you have type II pneumocytes, which are cuboidal and secrete surfactant from their lamellar bodies. (make sure you recognize the corners as the doctor kept talking about them)

The **interstituim** of the interalveolar septum is composed of two things:

- **Connective tissue**
- A heavy network of **capillaries** (Within the interstitium of the interalveolar septum is found the richest capillary network in the body).

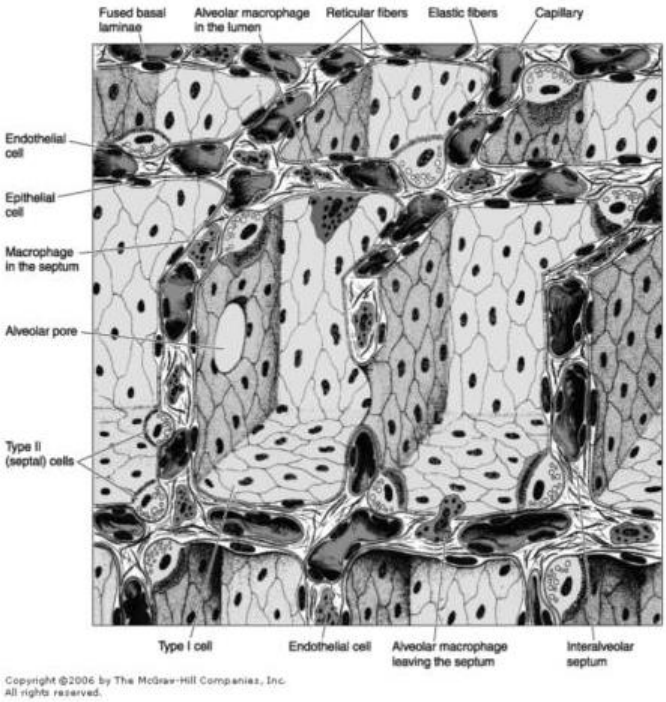

The interalveolar septum contains **pores** (10-15 um in diameter), that connect neighboring alveoli. These pores **equalize air pressure** in the alveoli and promote the **collateral circulation** of air when a bronchiole is obstructed.

Cells in the interstitium:

• Endothelial cells (capillaries) 30 %

• Fibroblasts and mast cells 36%

• Macrophages 10 %

• Type I cells 8 %

• Type II cells 16%

However, that's not the case in alveolar epithelium, as type I pneumocytes make about 97% of the alveolar lining and type II pneumocytes make only about 3%.

Within the interalveolar septum, anastomosing pulmonary capillaries are supported by a meshwork of reticular and elastic fibers. These fibers are arranged to permit expansion and contraction of the interalveolar septum. They are the primary means of structural support of the alveoli.

Here we can see the alveoli with a vein and artery.
Differences between alveolar veins and artery:

Arteries:

- Have thin walls
- Low pressure
- Carry deoxygenated blood

Veins:

- Have thick walls
- High pressure
- Carry oxygenated blood

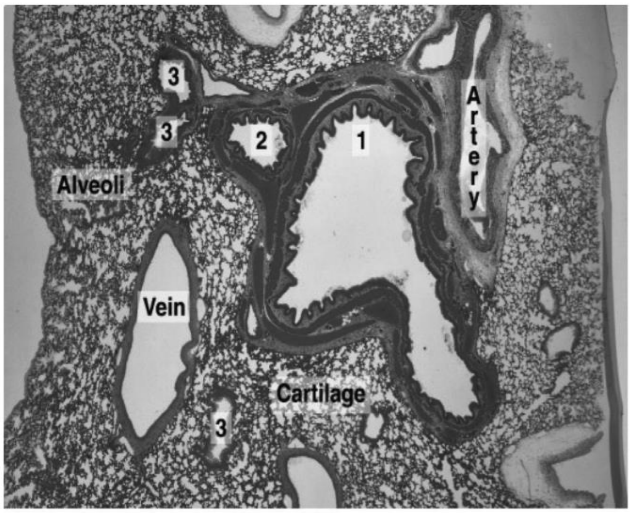

The basement membrane, leukocytes, macrophages, and fibroblasts can also be found within the interstitium of the septum.

The basement membrane is generally **thick** in the interalveolar septum except in the **respiratory membrane**, where two **thin** basal laminae of the endothelial cells and the epithelial (alveolar) cells of the interalveolar septum fuse to form the basement membrane.

Blood-air barrier (respiratory membrane):

Air in the alveoli is separated from capillary blood by three components referred to collectively as **the blood-air barrier** or **respiratory membrane** (because gas exchange happens across it)**.** The components of the blood-air barrier are:

1. the surface lining and cytoplasm of the **alveolar cells** (simple squamous epithelium).
2. **Endothelial cells** (also simple squamous).
3. The **fused basal laminae** of the previous two components lies in-between.
4. Although it's not a tissue component, the surfactant layer that lines the alveoli (called **the surfactant surface**) is considered as a part of this membrane.

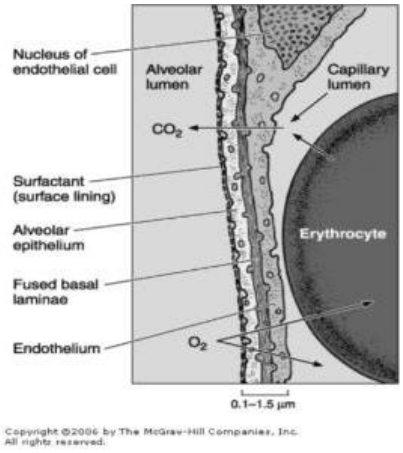

The total thickness of these layers varies from 0.1 to 1.5 um.

There are <u>no other structures</u>, and that's to ensure minimal thickness of the membrane.

Gas exchange across the respiratory membrane:

O2 from the alveolar air passes into the capillary blood through the blood-air barrier and CO2 diffuses in the opposite direction. Liberation of CO2 from H2CO3 is catalyzed by the enzyme ***carbonic anhydrase*** present in erythrocytes.

The approximately 300 million alveoli in the lungs considerably increase their internal exchange surface, which has been calculated to be approximately 140 m2.

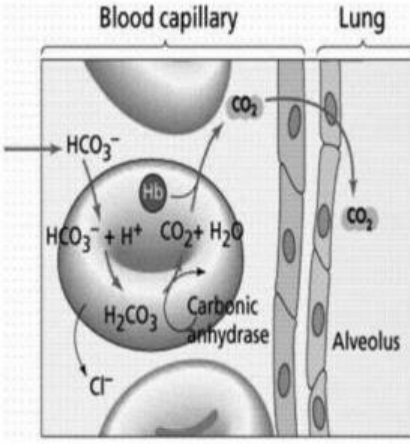

Capillary endothelial cells:

Extremely thin and can be easily confused with type I alveolar epithelial cells, we can differentiate between them by the presence of red blood cells in the capillaries. endothelial lining of the capillaries is continuous and not fenestrated.

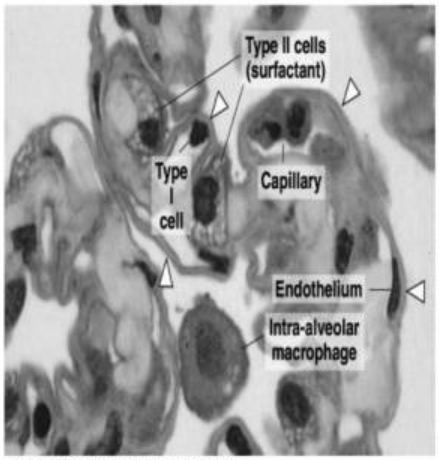

Clustering of the nuclei and other organelles allows the remaining areas of the cell to become extremely thin increasing the efficiency of gas exchange. The most prominent feature of the cytoplasm in the flattened portions of the cell is numerous pinocytotic vesicles.

Alveolar epithelial cells:

As we've mentioned, there are two types of alveolar epithelial cells:

1. **Type I Pneumocytes:**

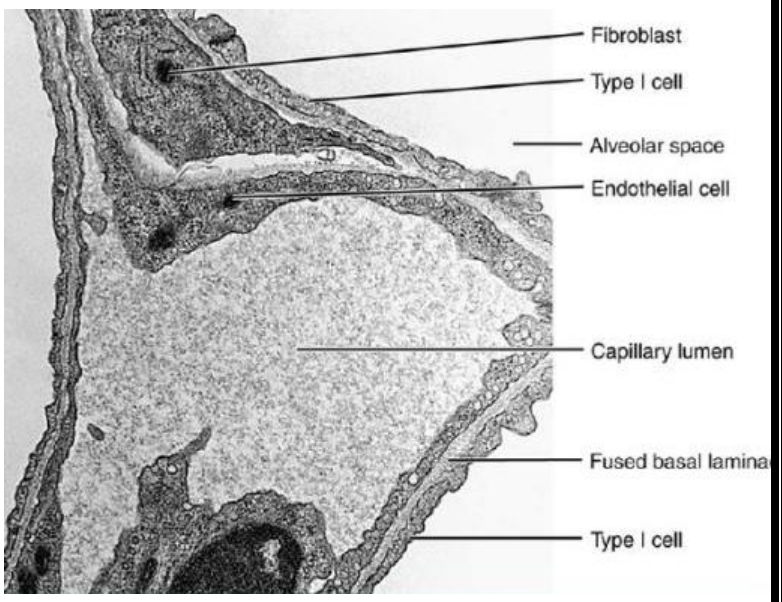

- Squamous cells, extremely attenuated, that line the alveolar surfaces.
- make up to **97%** of the alveolar surfaces.
- are so thin (sometimes only 25 nm) that the electron microscope was needed to prove that all alveoli are covered with an epithelial lining.
- Organelles such as the Golgi complex, endoplasmic reticulum, and mitochondria are grouped around the nucleus, reducing the thickness of the blood-air barrier and leaving large areas of cytoplasm virtually free of organelles.
- The cytoplasm in the thin portion contains abundant **pinocytotic vesicles**, which may play a role in the turnover of surfactant and the removal of small particulate contaminants from the outer surface.
- They have **renewal capacity** – they can undergo mitoses – but they **<u>only replace similar type I cells</u>**.

- They have many junctions between them – like **desmosomes** – to maintain their integrity.
- In addition to desmosomes, all type I epithelial cells have **occluding junctions** that prevent the leakage of tissue fluid into the alveolar air space.
- The main role of these cells is to provide a barrier of minimal thickness that is readily permeable to gases.

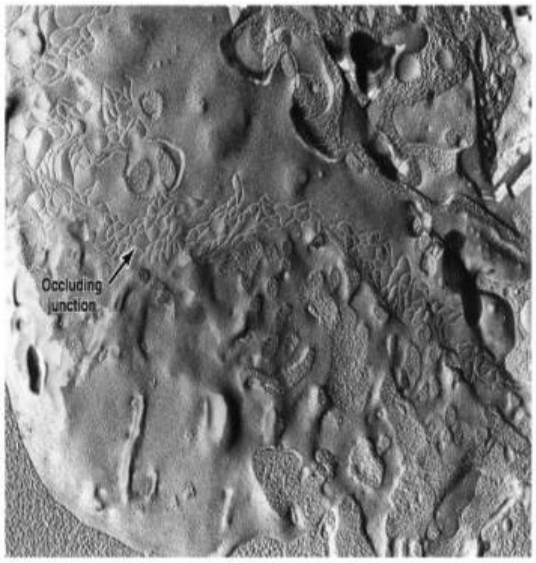

2. Type II pneumocytes:

- Interspersed among the type I alveolar cells with which they have occluding and desmosomal junctions.
- Make the remaining **3%** of the alveolar surface.
- They are found mainly on the **<u>corners of the interalveolar septum.</u>**
- Rounded (cuboidal) cells that are usually found in groups of two or three along the alveolar surface at points at which the alveolar walls unite and form angles.
- Rest on the basement membrane, are part of the epithelium, with the **same origin** as the type I cells.
- Divide by mitosis to replace **their own population** and **also the type I population.**

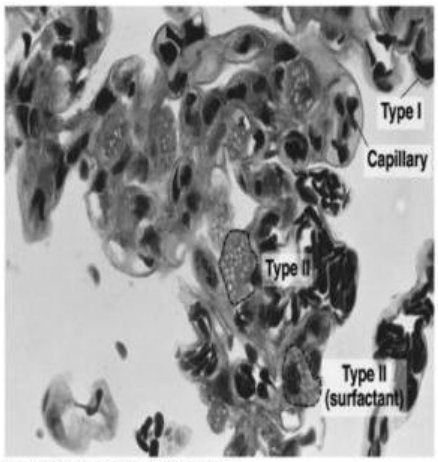

- They are also called: **great alveolar cells** or **septal cells.**
- They contain a **large central nucleus**.
- They exhibit a characteristic **vesicular** or **foamy cytoplasm**.

- They contain lamellar bodies which average 12um in diameter, contain concentric or parallel lamellae limited by a unit membrane and are responsible of the production of **surfactant**.
- These bodies, which contain phospholipids, glycosaminoglycans, and proteins, are continuously synthesized and released at the apical surface of the cells.

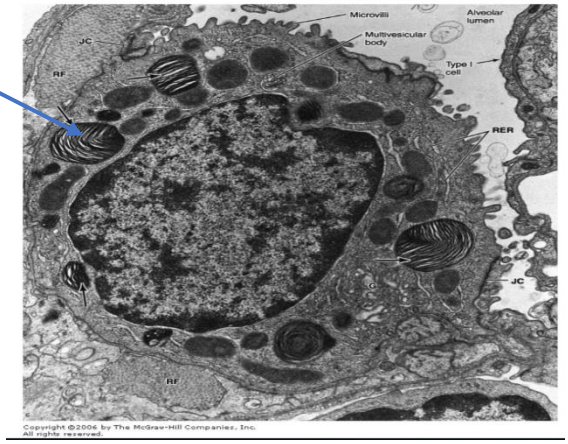

Pulmonary surfactant:

The doctor said that surfactant types and synthesis are not required in histology and we will take them in other subjects.

Pulmonary surfactant serves several major functions in the lung, but it primarily aids in reducing the surface tension of the alveolar cells. It also has a role in lubrication and in infants, it helps with the maturation of the lungs.

Surfactant also has a **bactericidal effect**.

In fetal development, surfactant appears in the last weeks of gestation –during 8th month- and coincides with the appearance of lamellar bodies in the type II cells. But it won't reach its normal level until the <u>end</u> of the **8th month** of gestation.

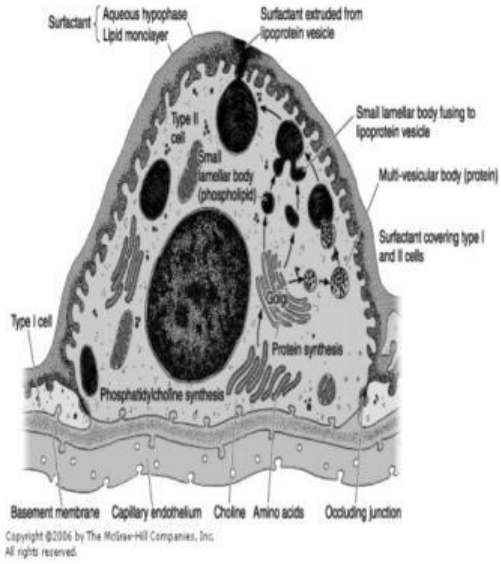

These days, we can measure the level of surfactant in the fetal lungs; if it's low, we give the mother hydrocortisone injections to enhance surfactant production in the fetus. However, if the baby was born with low level of surfactant, the lungs won't be able to inflate and alveoli will collapse; this condition is called **Infant respiratory distress syndrome**.

- The surfactant layer is not static but is constantly being turned over.

- The lipoproteins are gradually removed from the surface by the **pinocytotic vesicles of the squamous epithelial cells**, by **macrophages**, and by **type II alveolar cells**.
- Alveolar lining fluids are also removed via the conducting passages as a result of **ciliary activity**.
- As the secretions pass up through the airways, they combine with bronchial mucus, forming a **bronchoalveolar fluid**.
- The bronchoalveolar fluid contains several lytic enzymes (e.g., lysozyme, collagenase, glucuronidase) that are probably derived from the alveolar macrophages.
- bronchoalveolar fluid is then expelled as **sputum**.
- In infants who can't clear their own airway, we perform aspiration of sputum by an endotracheal tube.

Alveolar-Lining Regeneration:

• Inhalation of NO2 destroys most of the cells lining the alveoli (type I and type II cells).

• The action of this compound or other toxic substances with the same effect is followed by an increase in the mitotic activity of the remaining type II cells.

• The normal turnover rate of type II cells is estimated to be 1% per day and results in a continuous renewal of both its own population and that of type I cells.

Lung Macrophages:

- also called **dust cells**
- these are the **<u>most abundant cells in the lungs</u>** (more than type I/II or any other cells)
- are found in **all parts of the respiratory tract**, especially: the interior of the **interalveolar septum** and are often seen on the **surface of the alveolus** they are also found in the **pleura**.
- The phagocytosed debris within these cells was passed from the alveolar lumen into the interstitium by the pinocytotic activity of type I alveolar cells
- The alveolar macrophages that scavenge the outer surface of the epithelium within the surfactant layer converge in the **hilum**

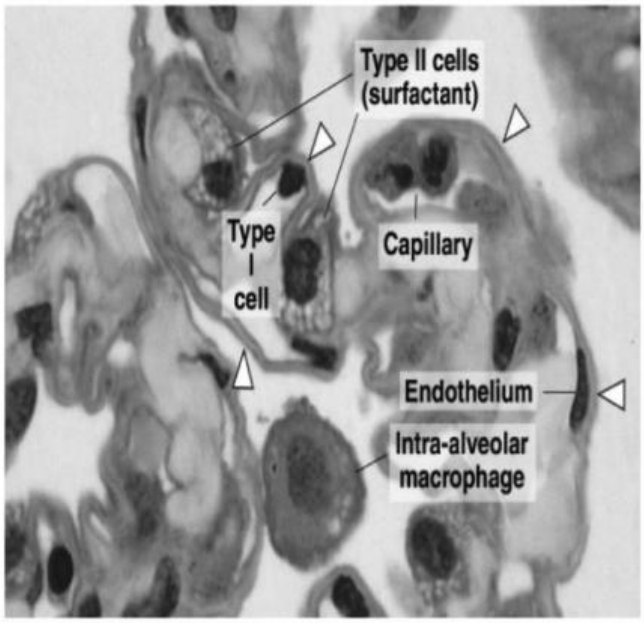

of the lungs and then they are carried with sputum to the **pharynx**, where they are swallowed or expelled.

- Numerous dust-laden macrophages in the connective tissue around major blood vessels or in the pleura probably are cells that have never passed through the epithelial lining.

Pulmonary Blood Vessels:

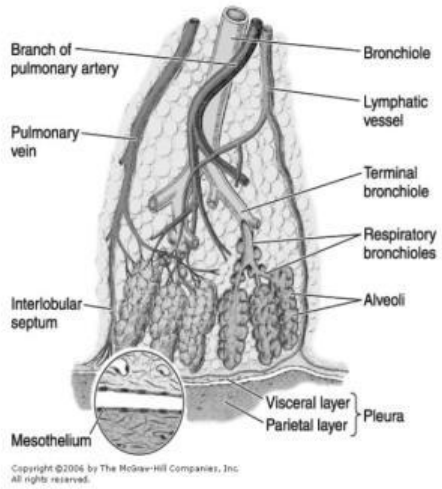

Thedoctor didn't talk much about the histology of vessels; instead, he started talking about the anatomy of pulmonary veins and arteries, which is completely covered in the previous lectures.

- Circulation in the lungs includes both nutrient (systemic) and functional (pulmonary) vessels

The image here shows you a lung segment, notice bronchioles, pulmonary arteries, veins, and lymphatics. Gas diffusion occurs through capillaries NOT pulmonary arteries nor veins.

Pulmonary arteries:

- are thin walled as a result of the **low pressures:** 25/5 mmHg.
- Within the lung the pulmonary artery branches, accompanying the bronchial tree
- Its branches are surrounded by adventitia of the bronchi and bronchioles.
- At the level of the alveolar duct, the branches of this artery form a capillary network in the interalveolar septum.
- The lung has the best-developed capillary network in the body, with capillaries between all alveoli, including those in the respiratory bronchioles.

Pulmonary veins:

- Thick wall, high pressure= 120/80 mmHg
- Venules that originate in the capillary network are found singly in the parenchyma
- supported by a thin covering of connective tissue and enter the interlobular septum.
- After veins leave a lobule, they follow the bronchial tree toward the hilum.

Nutrient vessels follow the bronchial tree and distribute blood to most of the lung up to the respiratory bronchioles, at which point they anastomose with small branches of the pulmonary artery.

Pulmonary Lymphatic Vessels:

- follow the bronchi and the pulmonary vessels; they are also found in the interlobular septum,

- they all drain into lymph nodes in the region of the hilum (**deep network**).
- The deep network then drains to: paratracheal lymph nodes→ tracheobronchial lymph nodes→ Broncho-mediastinal lymph nodes→ thoracic duct.
- **Superficial network** includes the lymphatic vessels in the visceral pleura.
- The lymphatic vessels of the superficial network drain toward the hilum. They either follow the entire length of the pleura or penetrate the lung tissue via the interlobular septum.
- Lymphatic vessels are not found in the terminal portions of the bronchial tree or beyond the alveolar ducts.

Nerves:

Both parasympathetic and sympathetic efferent fibers innervate the lungs and the visceral pleura. Those act mainly on bronchioles. Most of the nerves are found in the connective tissues surrounding the larger airways.

The parietal pleura is innervated by somatic nerves that are very sensitive to pain, touch and temperature.

Pleura:

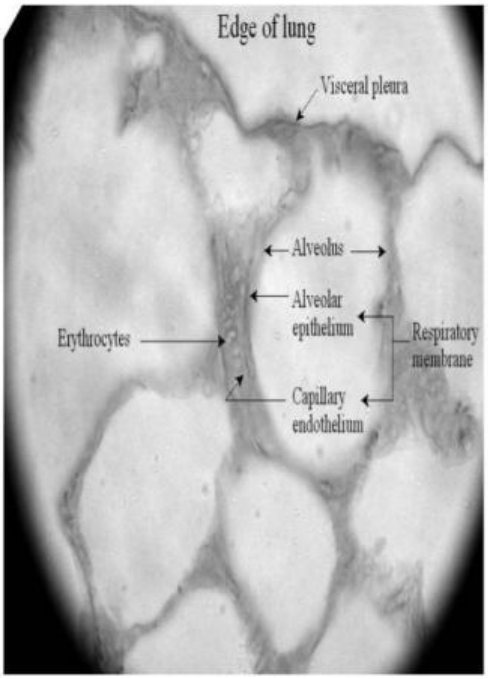

• It consists of two layers, parietal and visceral, that are continuous in the region of the hilum

• Both membranes are composed of <u>mesothelial cells</u> (simple squamous) resting on a fine connective tissue layer that contains collagen, reticular and elastic fibers. In addition to <u>dust cells</u>.

• The elastic fibers of the visceral pleura are continuous with those of the pulmonary parenchyma.

• Pleural cavity contains only a film of liquid that acts as a lubricant, facilitating the smooth sliding of one surface over the other during respiratory movements.

• This fluid is derived from the blood plasma by exudation

In the end, sorry about the long sheet, but I tried to include everything in the slides (even the pictures) so you don't have to go back to the slides.