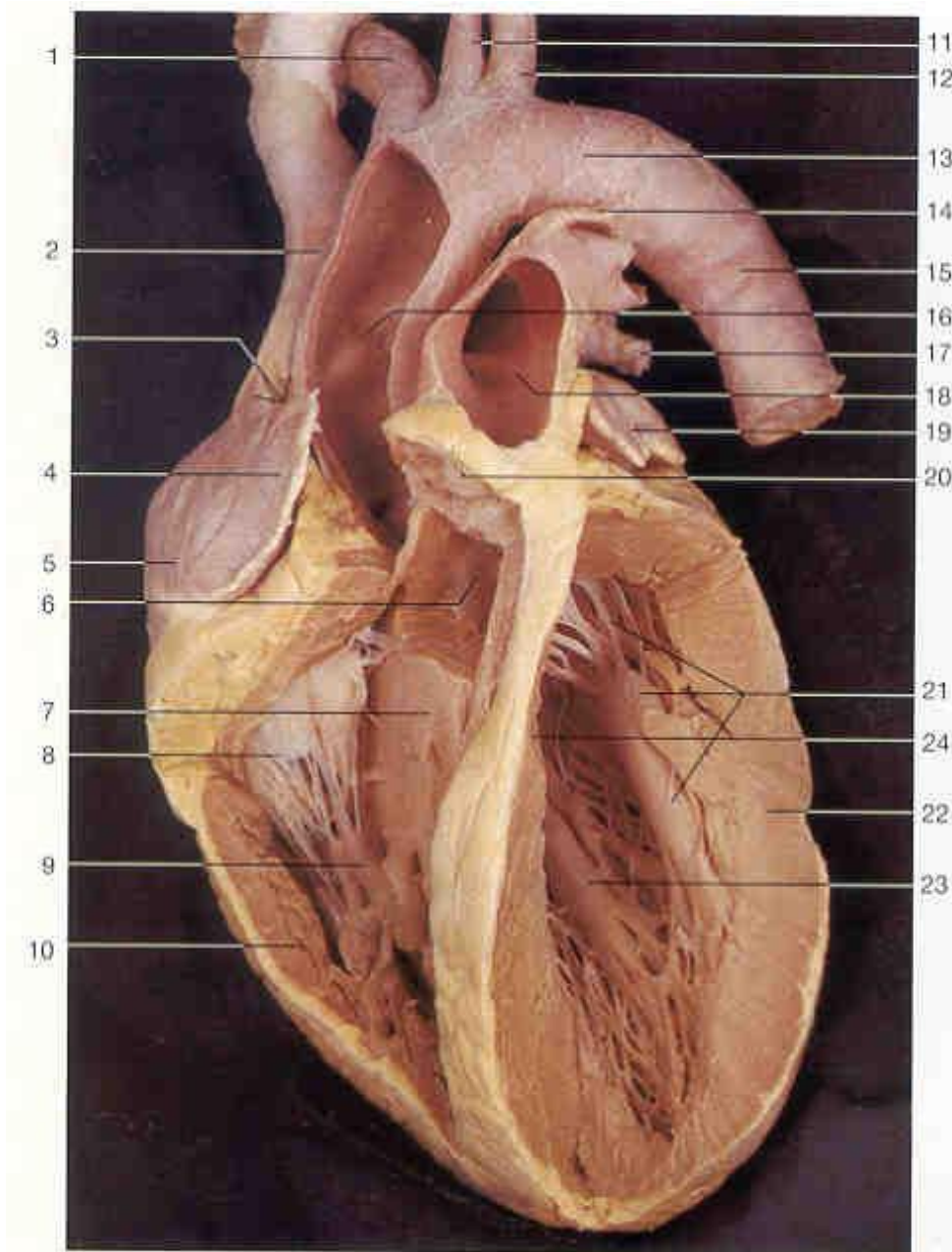


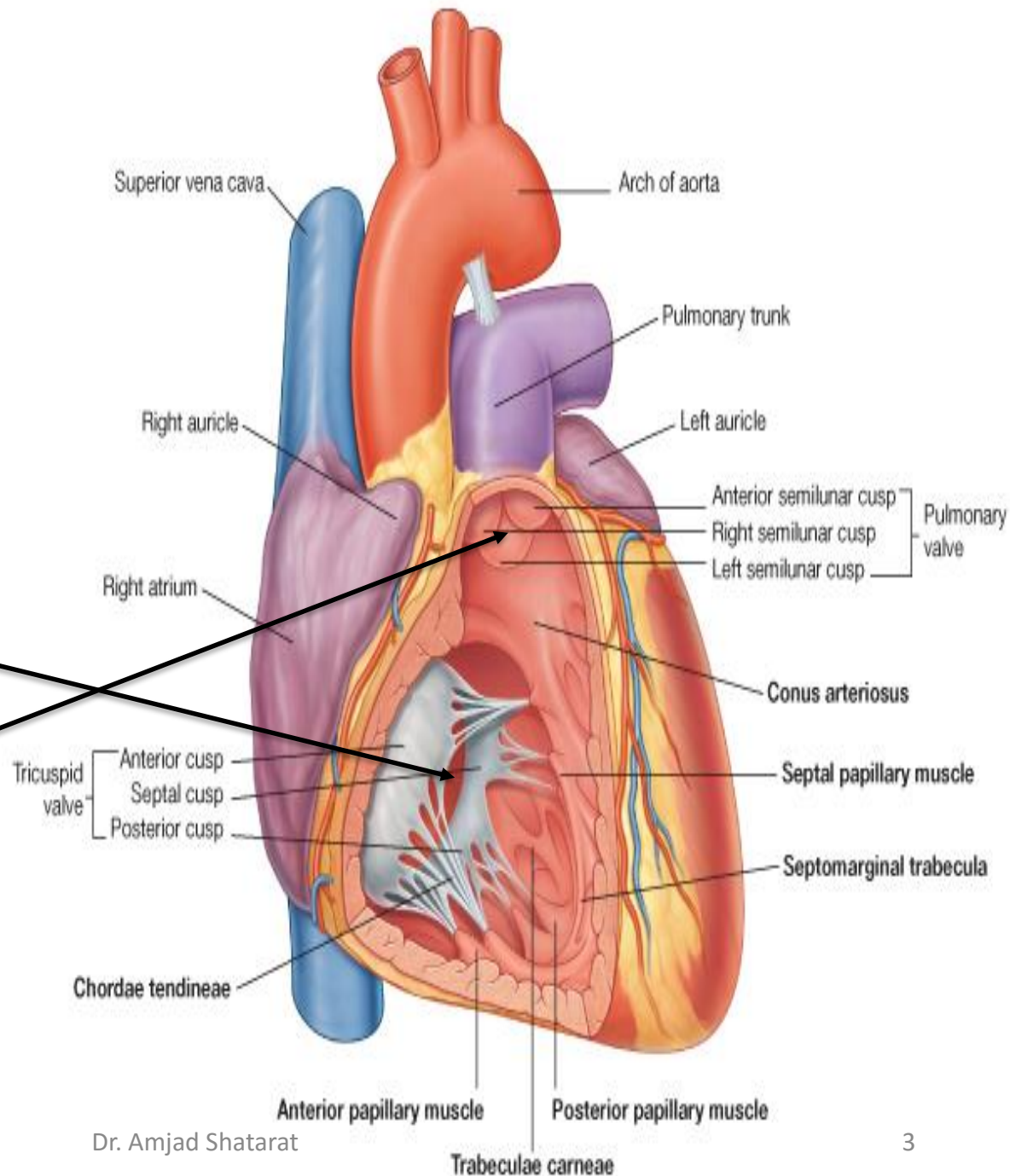
Right ventricle



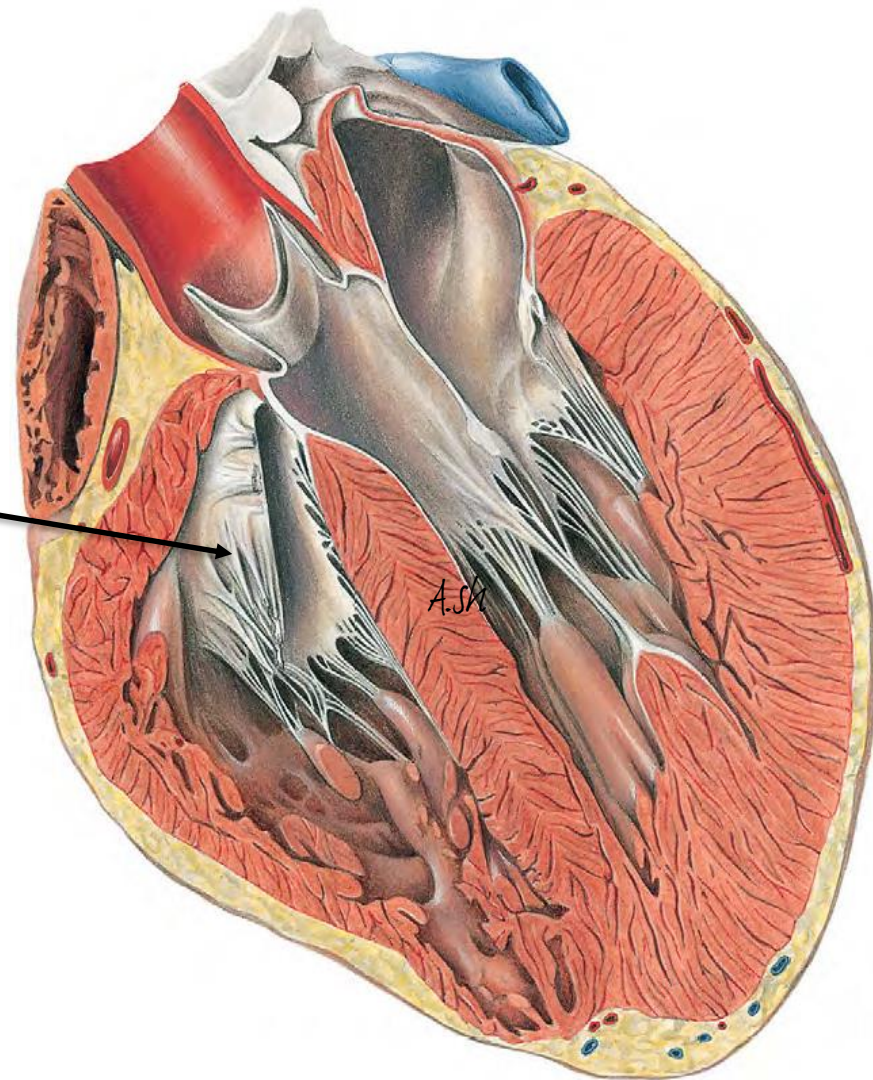
- 1:Brachiocephalic Trunk;
- 2:Superior Vena Cava;
- 4:Right Auricle;
- 5:Right Atrium;
- 6:Aortic Valve;
- 8:Tricuspid Valve;
- 9:Papillary Muscles;
- 10:Myocardium of Right Ventricle;
- 11:Left Common Carotid Artery;
- 12:Left Subclavian Artery;
- 13:Aortic Arch;
- 14:Ligamentum Arteriosum;
- 17:Pulmonary Vein;
- 18:Pulmonary Trunk;
- 19:Left Auricle;
- 20:Pulmonic Semilunar Valve;
- 21:Papillary Muscles;
- 22:Myocardium of Left Ventricle;
- 23:Papillary Muscles;
- 24:Interventricular Septum;

The right ventricle

communicates with
the right atrium through
THE RIGHT
ATRIOVENTRICULAR
ORIFICE
and with the pulmonary
trunk through
THE PULMONARY
ORIFICE



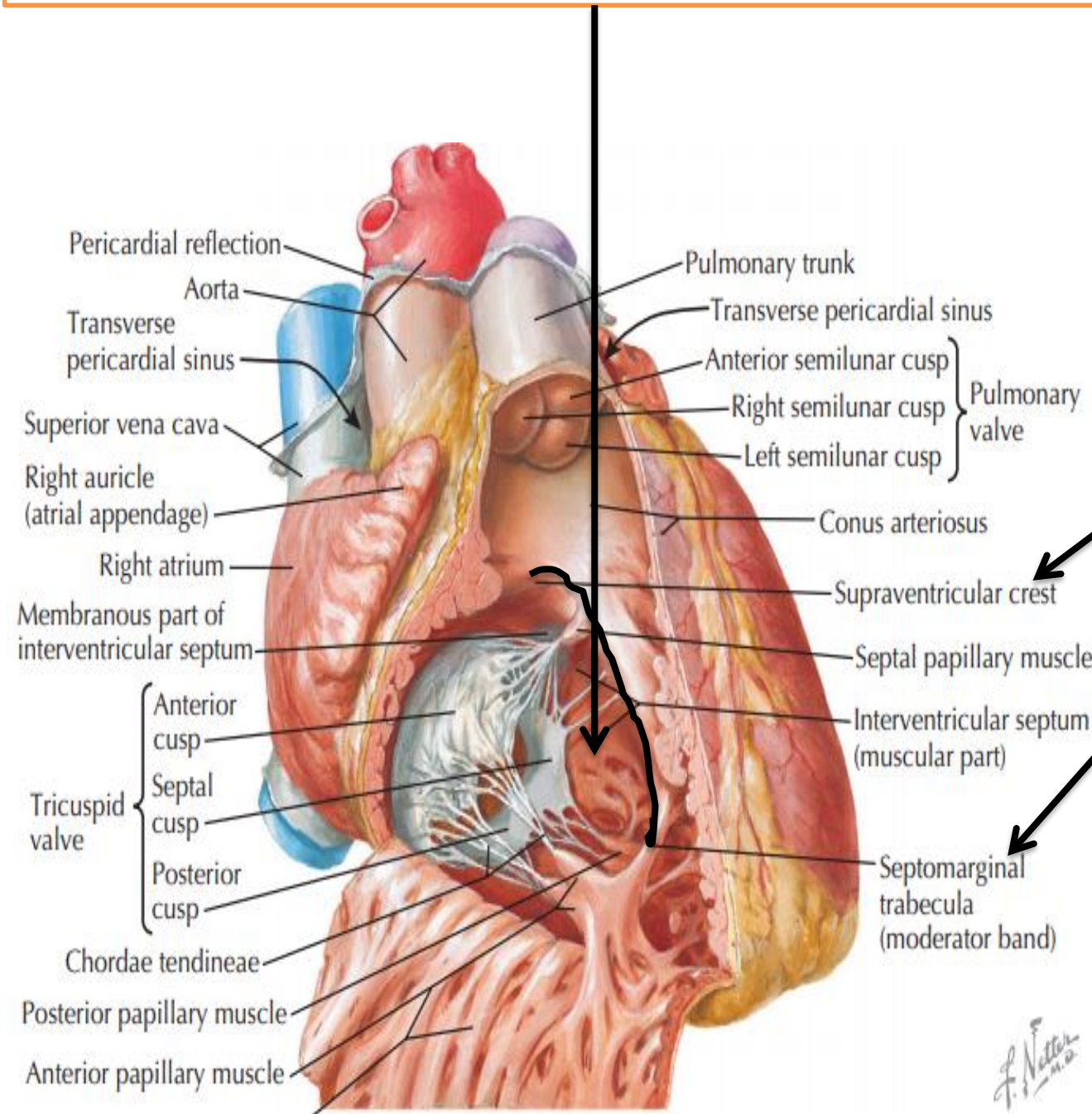
The tricuspid valve guards the right atrioventricular orifice and consists of **three cusps** formed by a fold of **endocardium** with some **connective tissue**



The right ventricle can be divided into



1- **inflow portion**, containing the tricuspid valve,



These two parts are separated by prominent muscular bands, including the parietal band the supraventricular crest (**crista supraventricularis**)

The septal band

The moderator band.

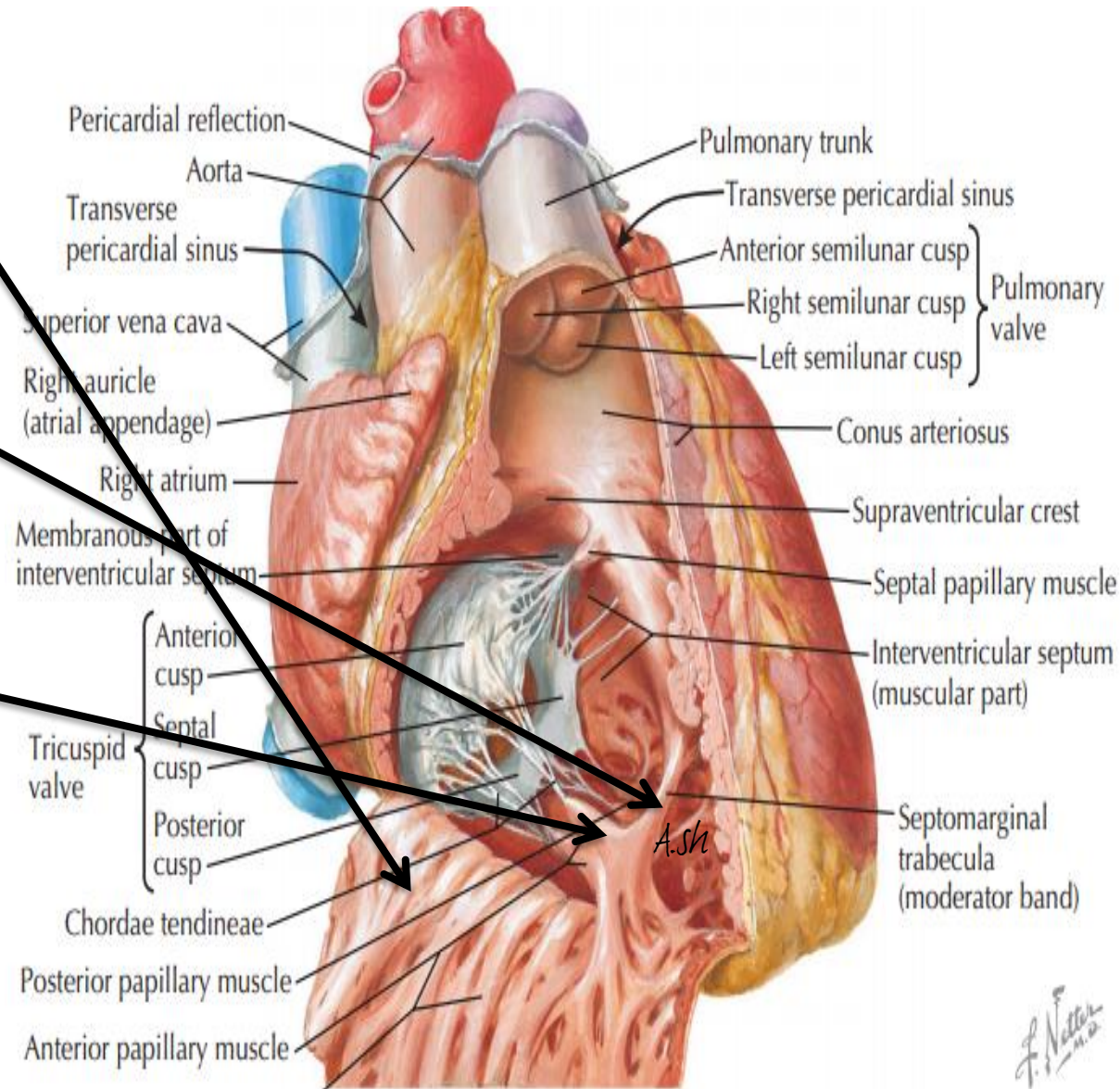
The walls of the inflow portion of the right ventricle have numerous muscular, irregular structures called **trabeculae carneae**

1-Prominent *RIDGES*

attached to the ventricular walls throughout their length.

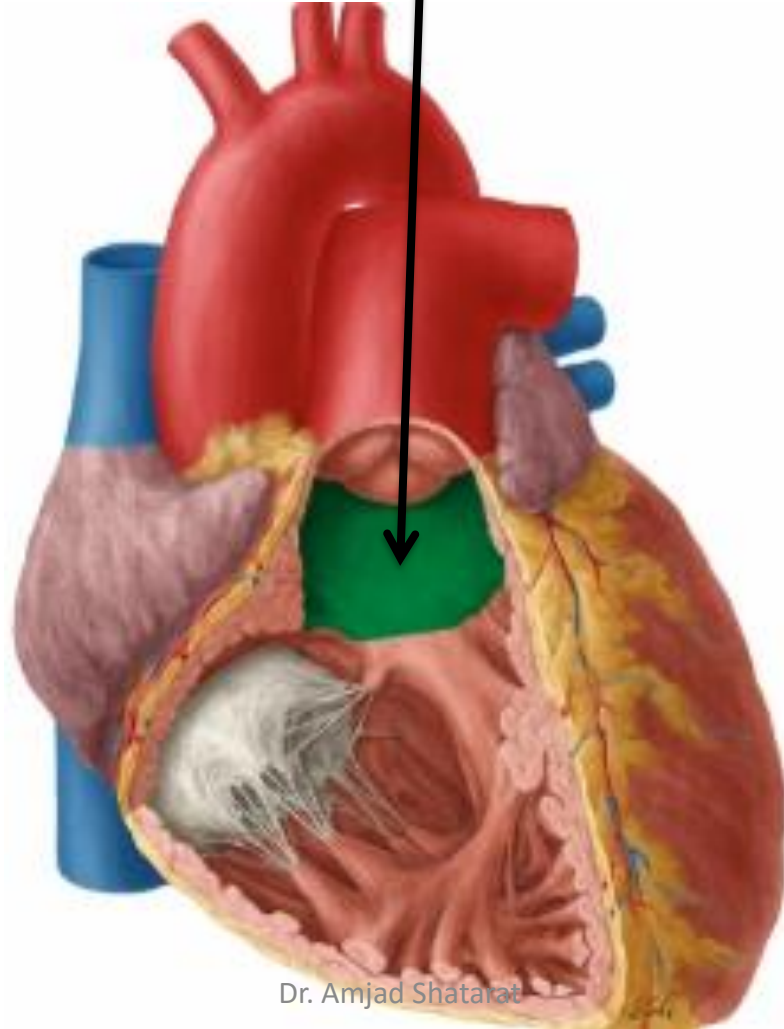
2-Attached at both ends, forming BRIDGES

3-The PAPILLARY muscles



2-The outflow tract of the right ventricle, which leads to the pulmonary trunk, is the **Conus arteriosus (infundibulum)**

This area has smooth walls and derives from the embryonic bulbus cordis



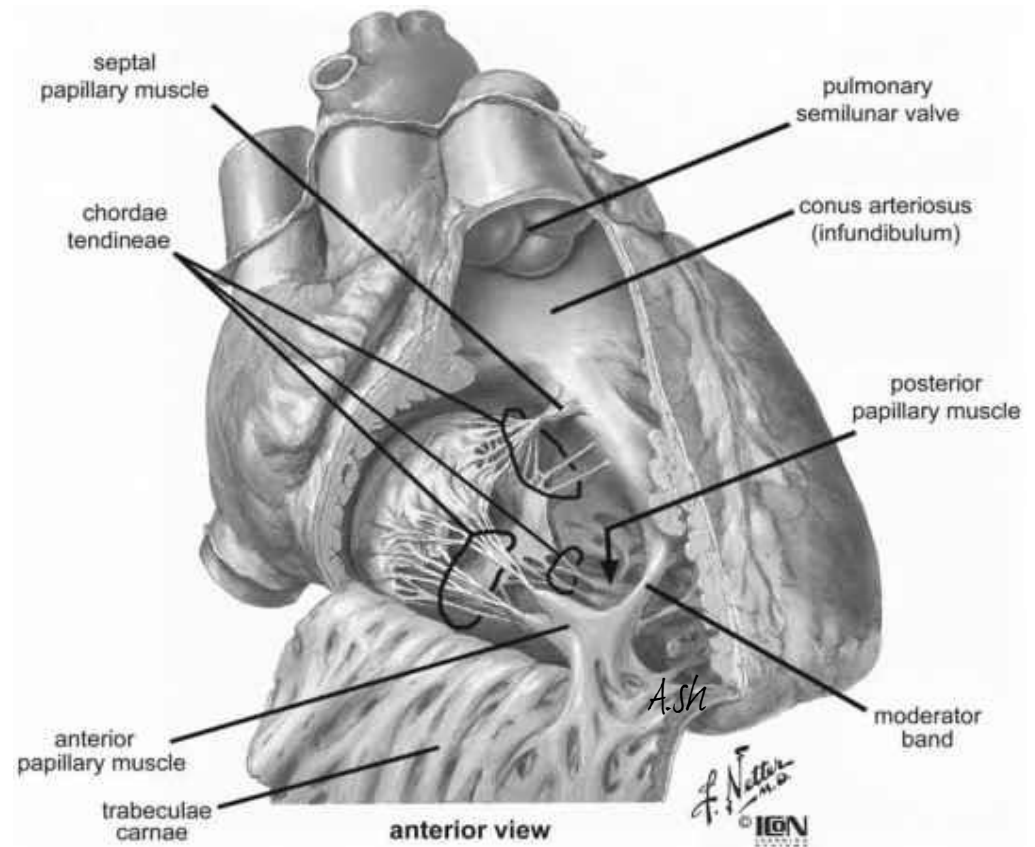
There are three papillary muscles in the right ventricle. Named relative to their point of origin on the ventricular surface, they are the **ANTERIOR, POSTERIOR, AND SEPTAL PAPILLARY MUSCLES**

THE ANTERIOR PAPILLARY muscle

is *the largest and most constant* papillary muscle, and arises from the anterior wall of the ventricle

The POSTERIOR PAPILLARY MUSCLE

may consist of one, two, or three structures, with some chordae tendineae arising directly from the ventricular wall

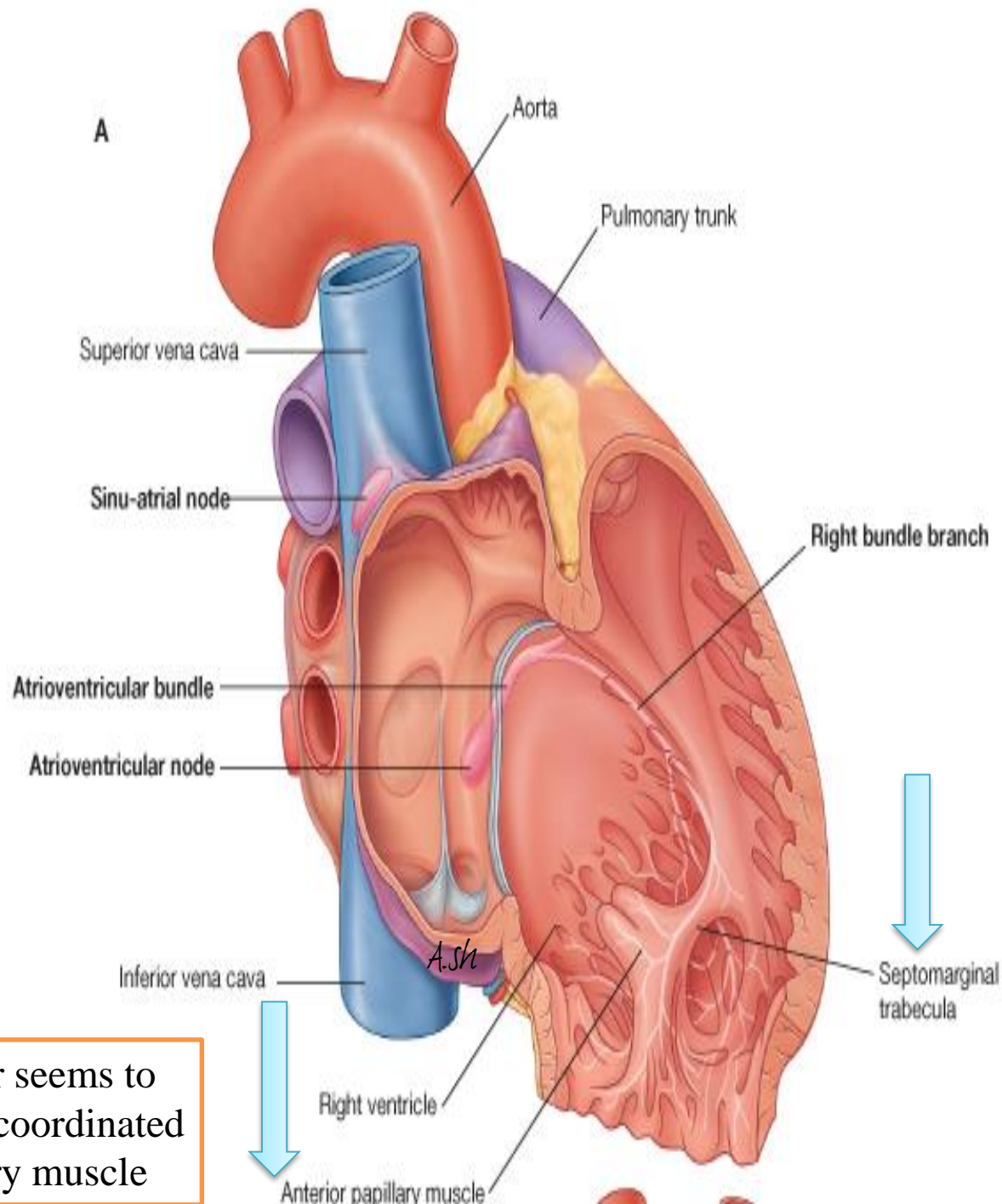


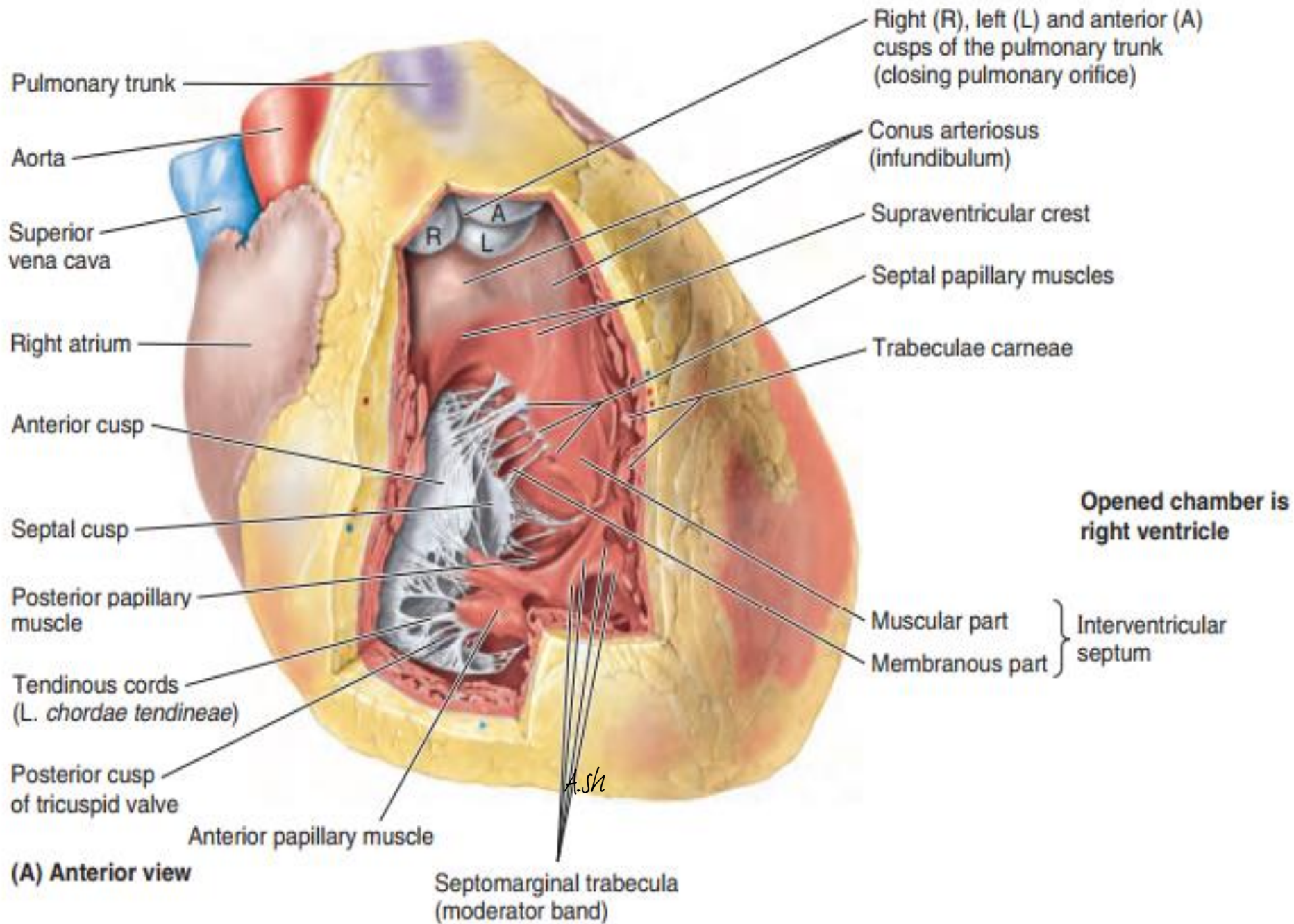
THE **septal papillary muscle** is the most inconsistent papillary muscle, being either small or absent, with chordae tendineae emerging directly *from the septal wall*.

A single specialized trabeculum, the **septomarginal trabecula (moderator band)**, forms a bridge between the lower portion of the **interventricular septum** and the base of **the anterior papillary muscle**.

The septomarginal trabeculum carries a portion of the cardiac conduction system, **RIGHT BUNDLE OF THE ATRIOVENTRICULAR BUNDLE**, to the anterior wall of the right ventricle

This “shortcut” across the chamber seems to facilitate conduction time, allowing coordinated contraction of the anterior papillary muscle





➤ The right atrium contracts when the right ventricle is relaxed

➤ Thus blood is forced into the right ventricle, pushing the cusps of the tricuspid valve aside *like curtains*

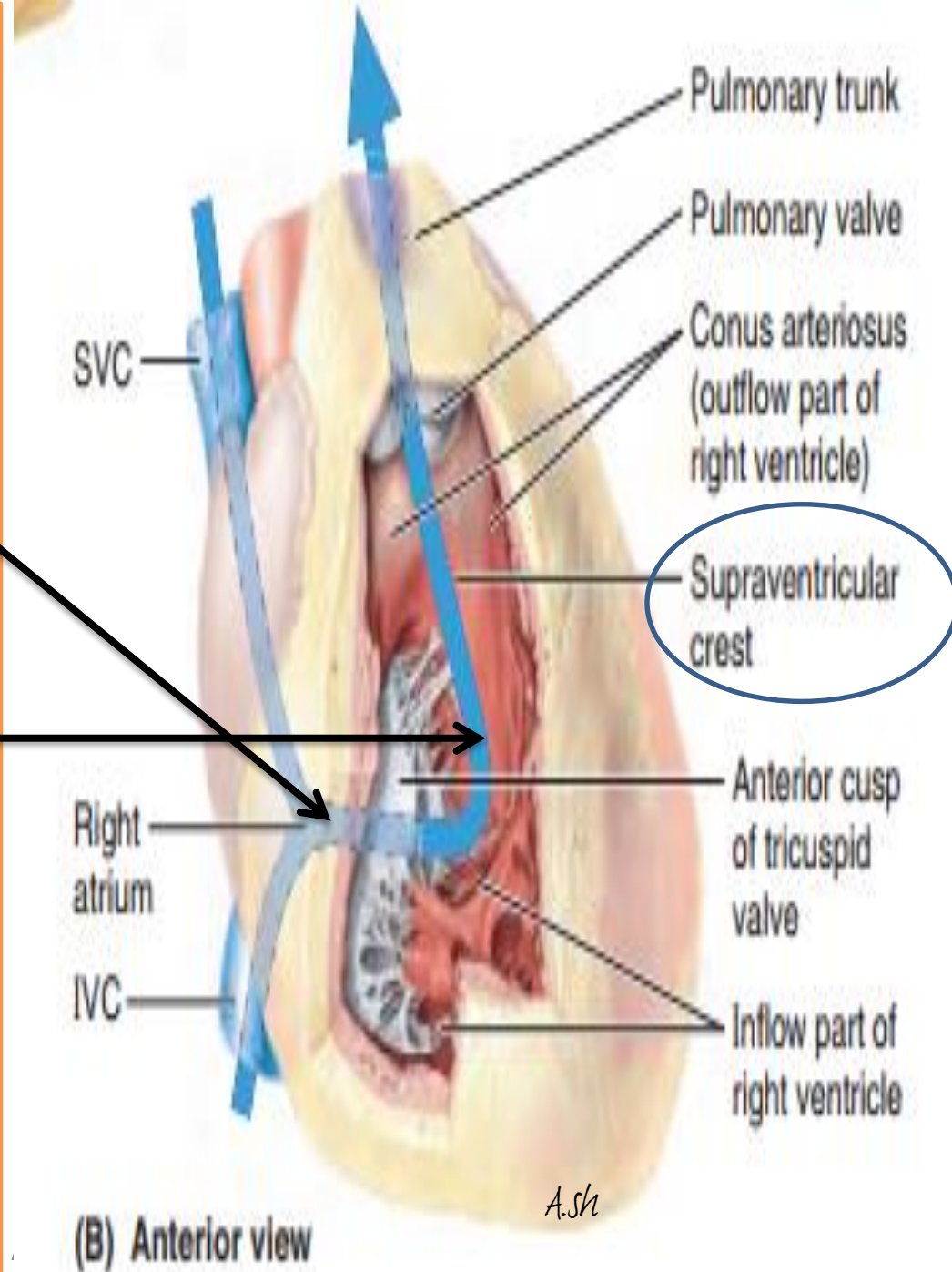
❖ The inflow of blood into the right ventricle (inflow tract) enters posteriorly

and when the ventricle contracts, the outflow of blood into the pulmonary trunk (outflow tract) superiorly and to the left

❖ Consequently, the blood takes a U-shaped path through the right ventricle, changing direction about 140° .

❖ This change in direction is accommodated by:

the supraventricular crest, which deflects the incoming flow into the main cavity of the ventricle, and the outgoing **flow into the conus arteriosus** toward the **pulmonary orifice**.



The interventricular or ventricular septum

The interventricular or ventricular septum

septum (IVS)

composed of :

MUSCULAR & MEMBRANOUS parts

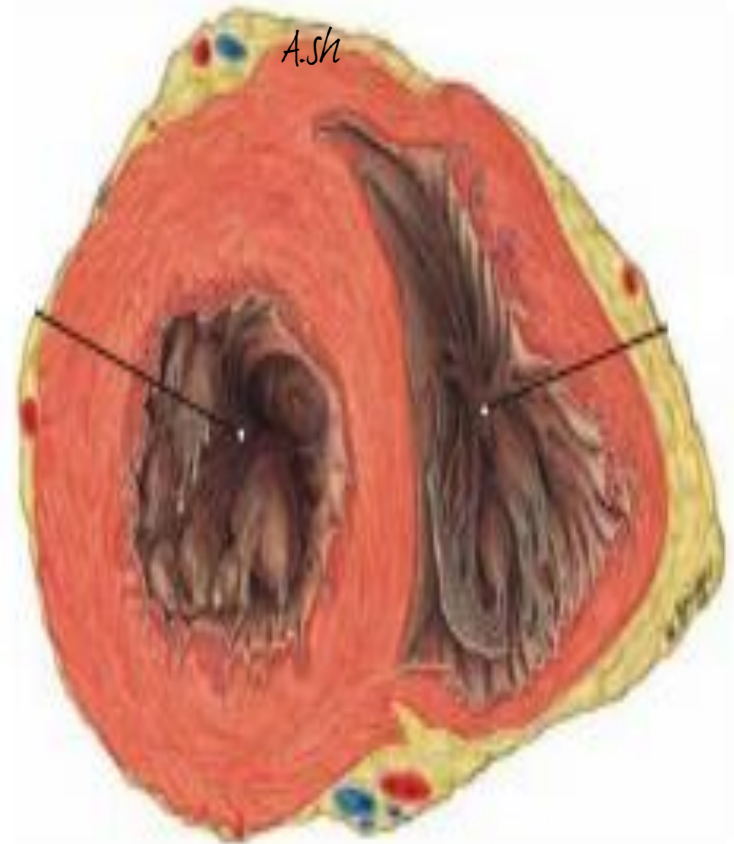- is a strong, *obliquely placed partition* between the right and left ventricles forming part of the walls of each.

Because of the much higher blood pressure in the left ventricle,

the muscular part of the IVS, which forms the majority of the septum, has the thickness of the remainder of the wall of the left ventricle

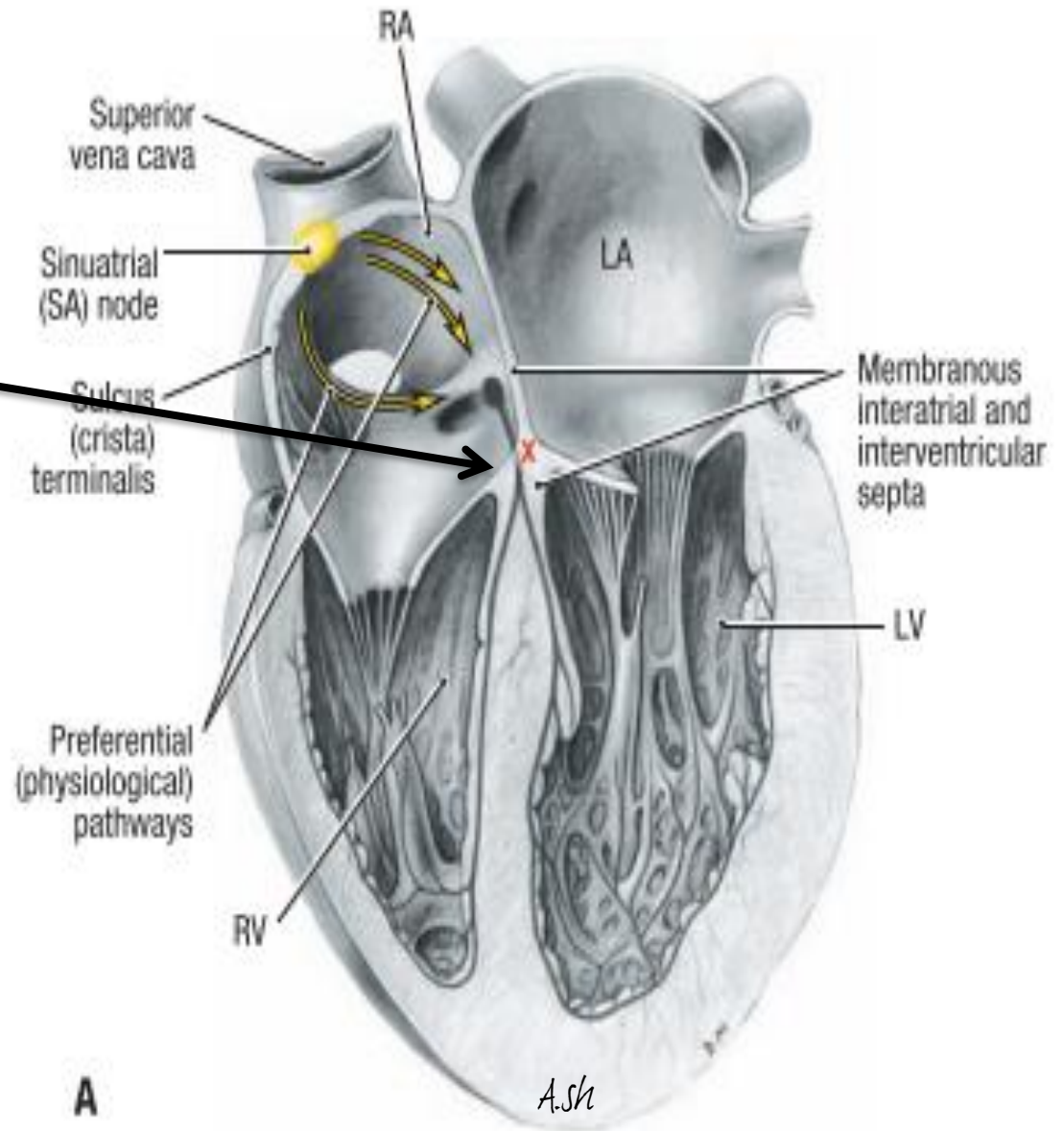
(two to three times as thick as the wall of the right ventricle)

- bulges into the cavity of the right ventricle.



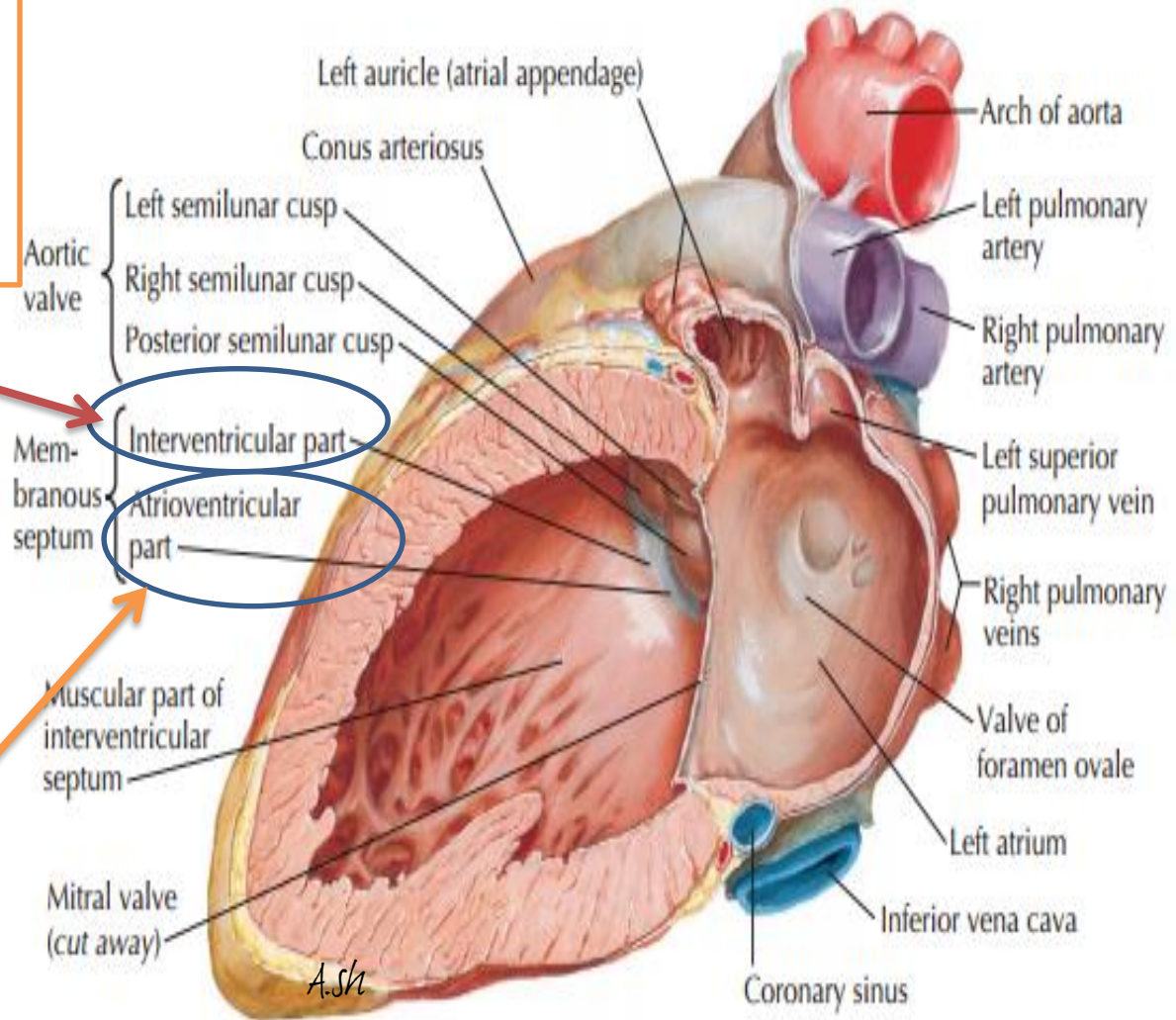
Superiorly and posteriorly, a thin membrane, part of the fibrous skeleton of the heart forms the much smaller membranous part of the IVS.

On the right side, the septal cusp of the tricuspid valve is attached to the middle of this membranous part of the fibrous skeleton.



This means that inferior to the septal cusp of the tricuspid valve ,
the **membranous part of the IVS** is
interventricular septum
(between the right and left ventricles)

However, superior to the septal cusp of the tricuspid valve it is
an **atrioventricular septum**
separating the right atrium from the left ventricle



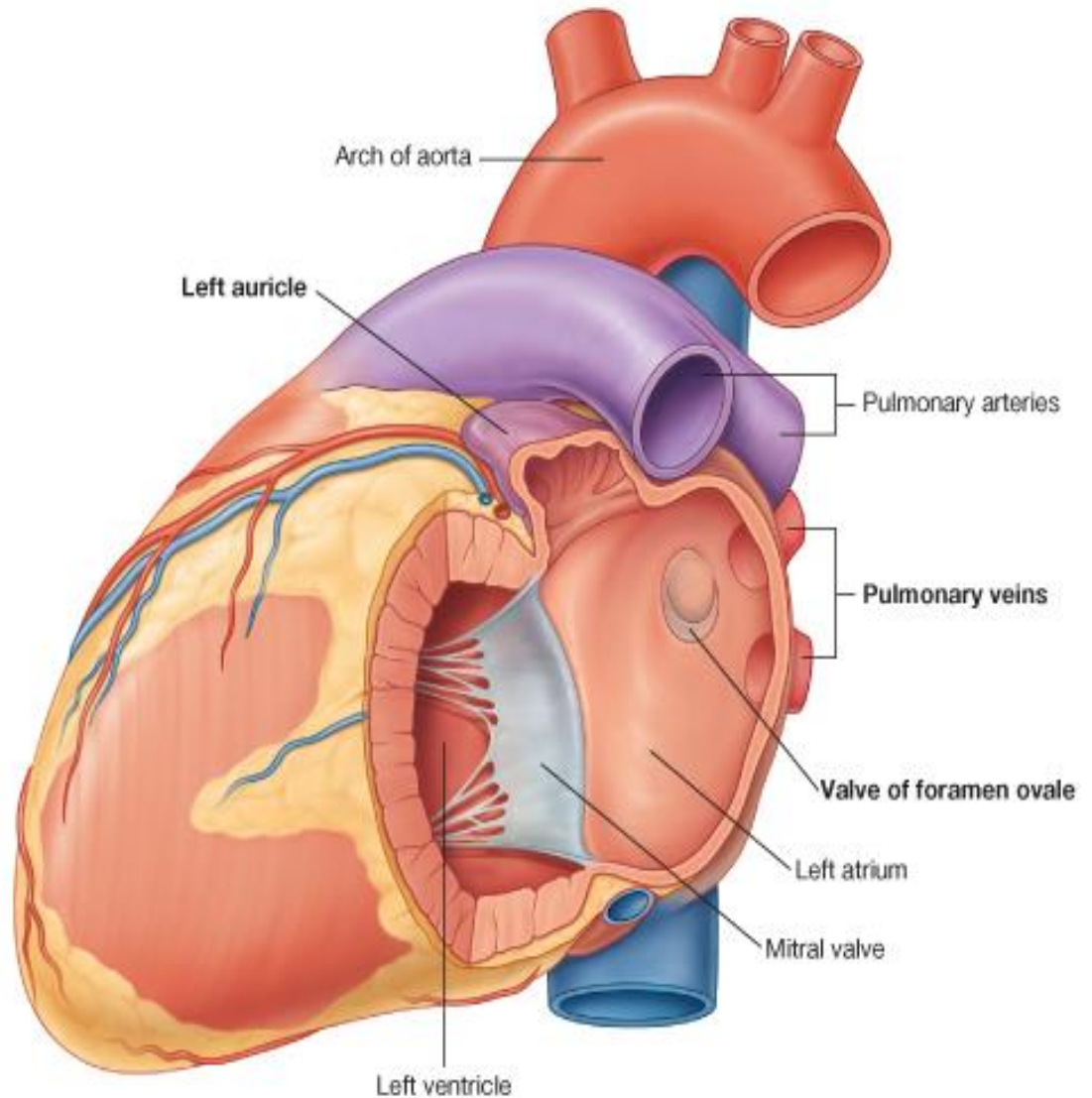
Section through left atrium and ventricle with mitral valve cut away

THE LEFT ATRIUM

Left Atrium

consists of a main cavity and a left auricle.

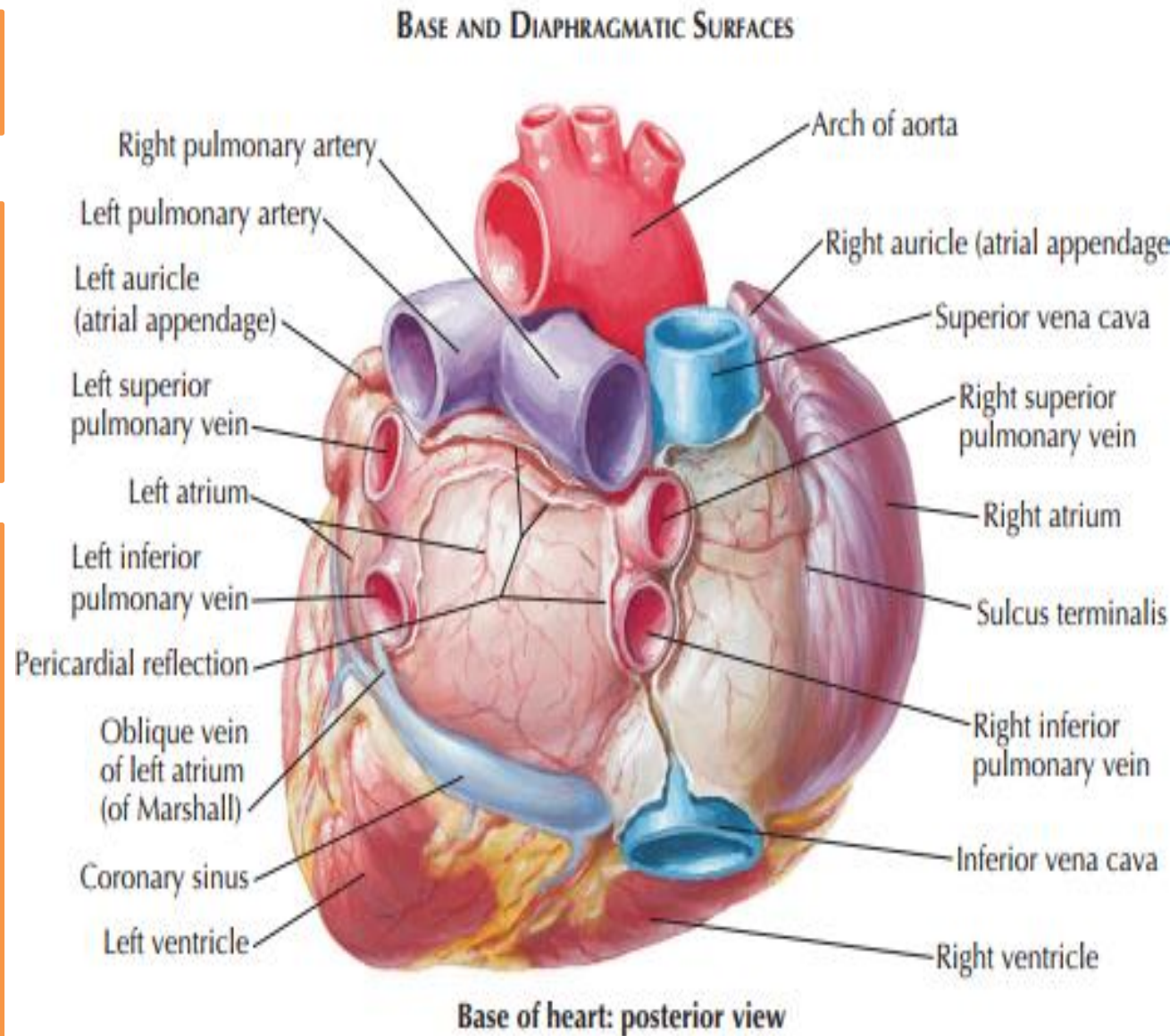
Behind it lies the fibrous pericardium separates it from the esophagus (**remember that the esophagus has a close relationship with the left atrium**)



The left atrium forms most of the base of the heart

- Although smaller in volume than the right, the left atrium has thicker walls (3 mm on average).

The left atrium is roughly cuboidal and extends behind the right atrium, separated from it by the obliquely positioned septum, **Thus the right atrium is in front and anterolateral to the right part of the left atrium.**



Rough part

The left auricle, it represents the remains of the left part of the primordial atrium and therefore, its wall trabeculated with pectinate muscles

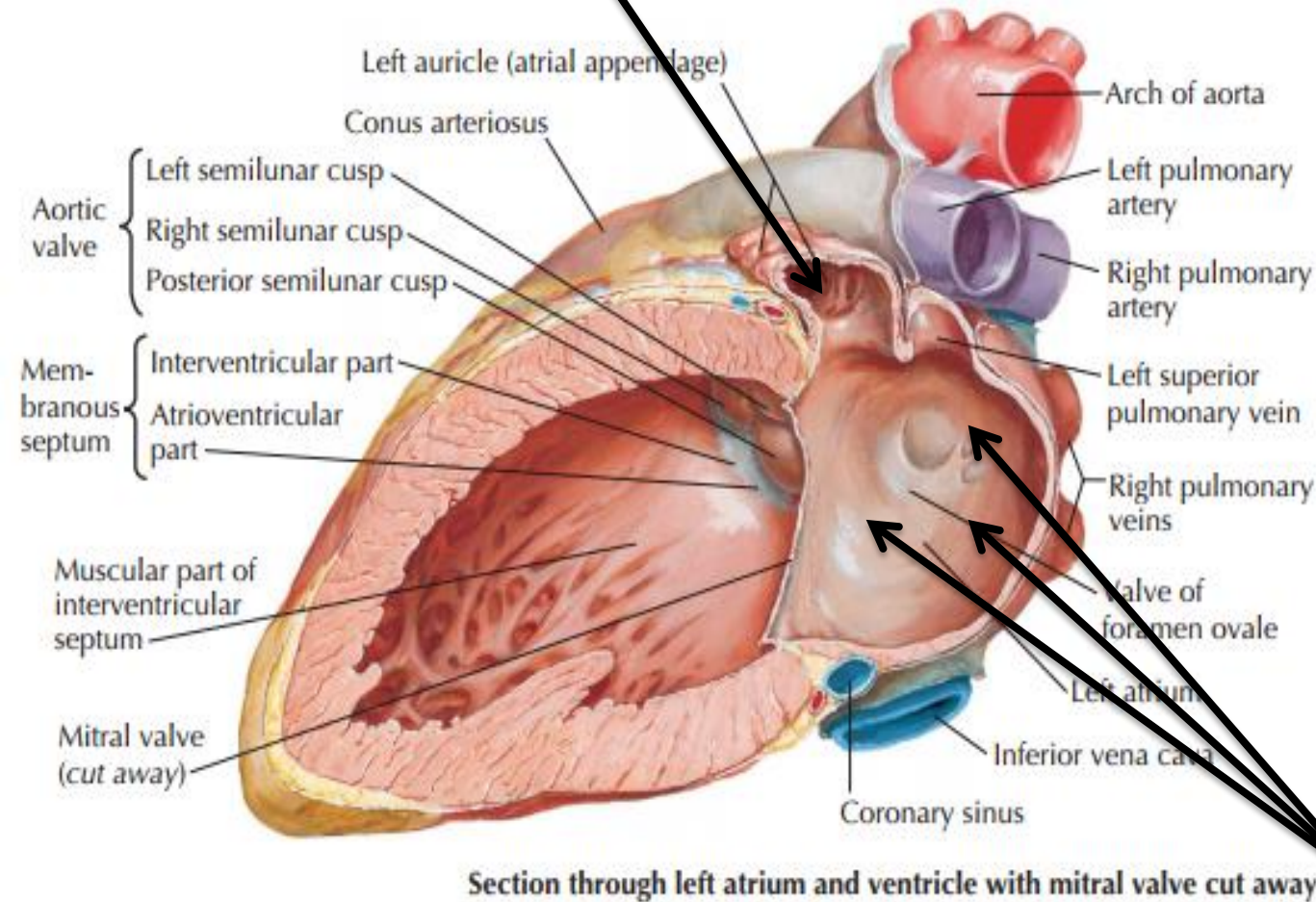
A larger smooth-walled part and a smaller muscular auricle containing pectinate muscles

Smooth part

In the embryo, there is only **one common pulmonary vein** with **four tributaries** (the future 4 pulmonary veins)

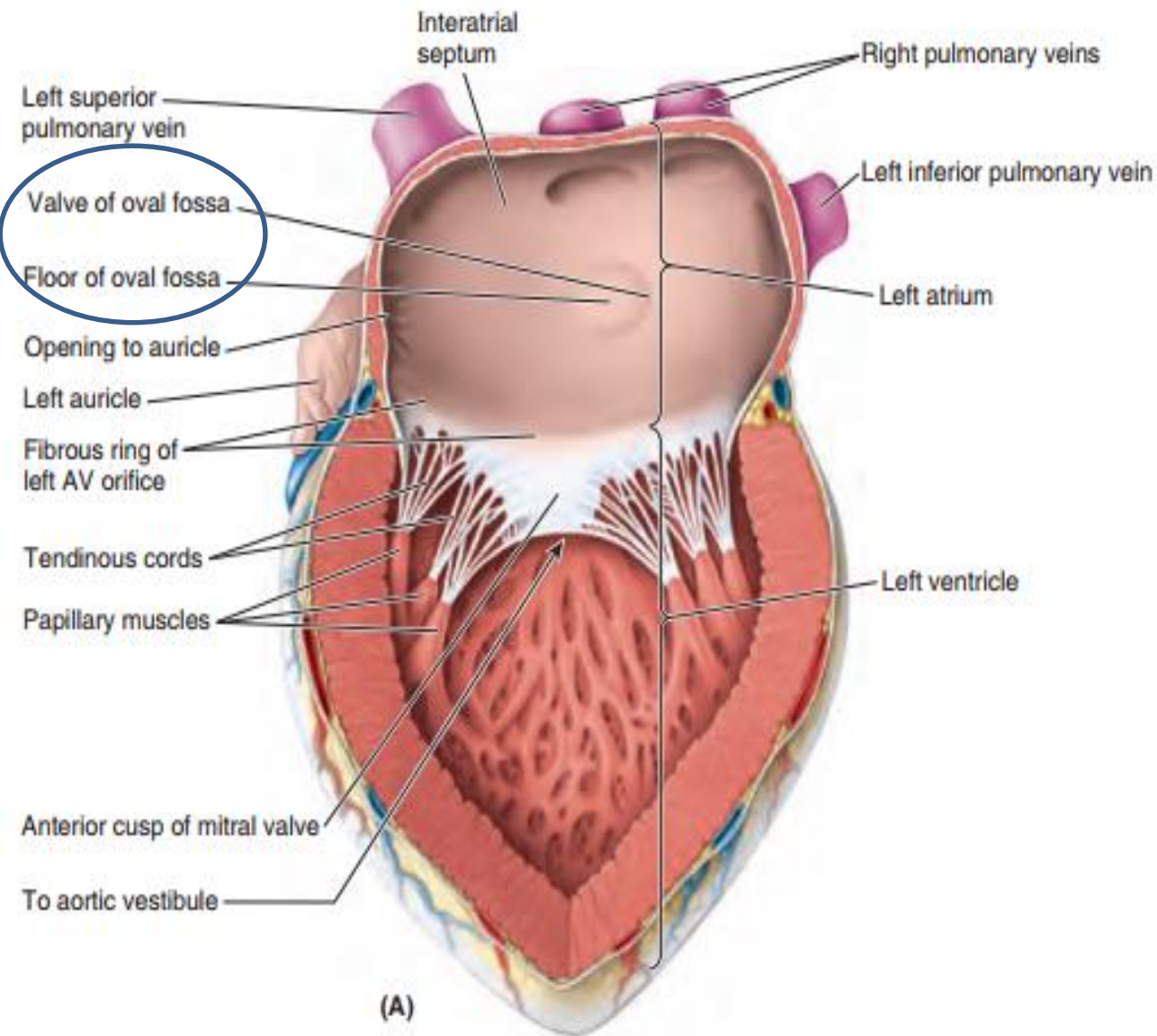
The walls of these veins were incorporated into the wall of the left atrium

(in the same way that the sinus venosus was incorporated into the right atrium) therefore, **this part is smooth.**

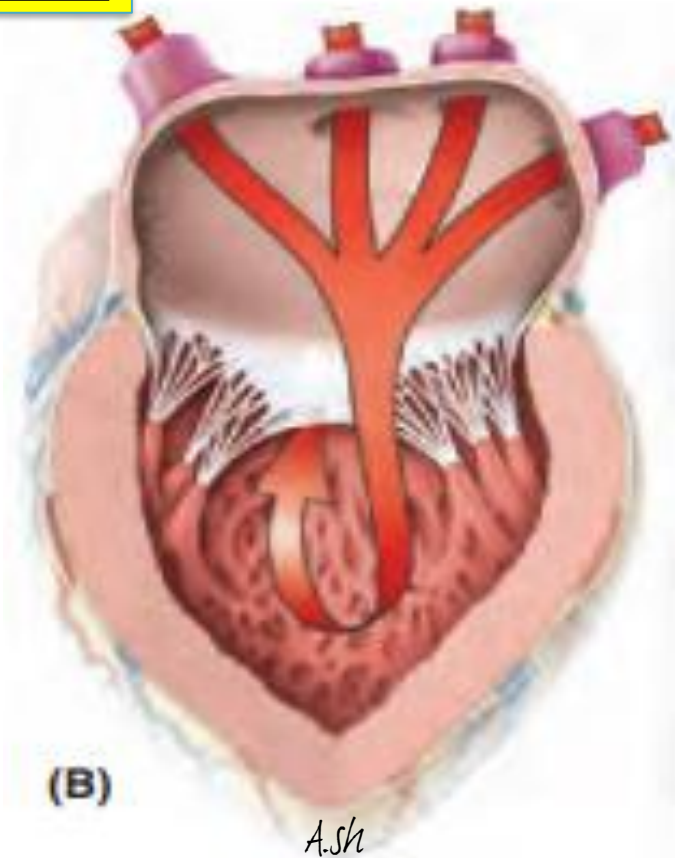
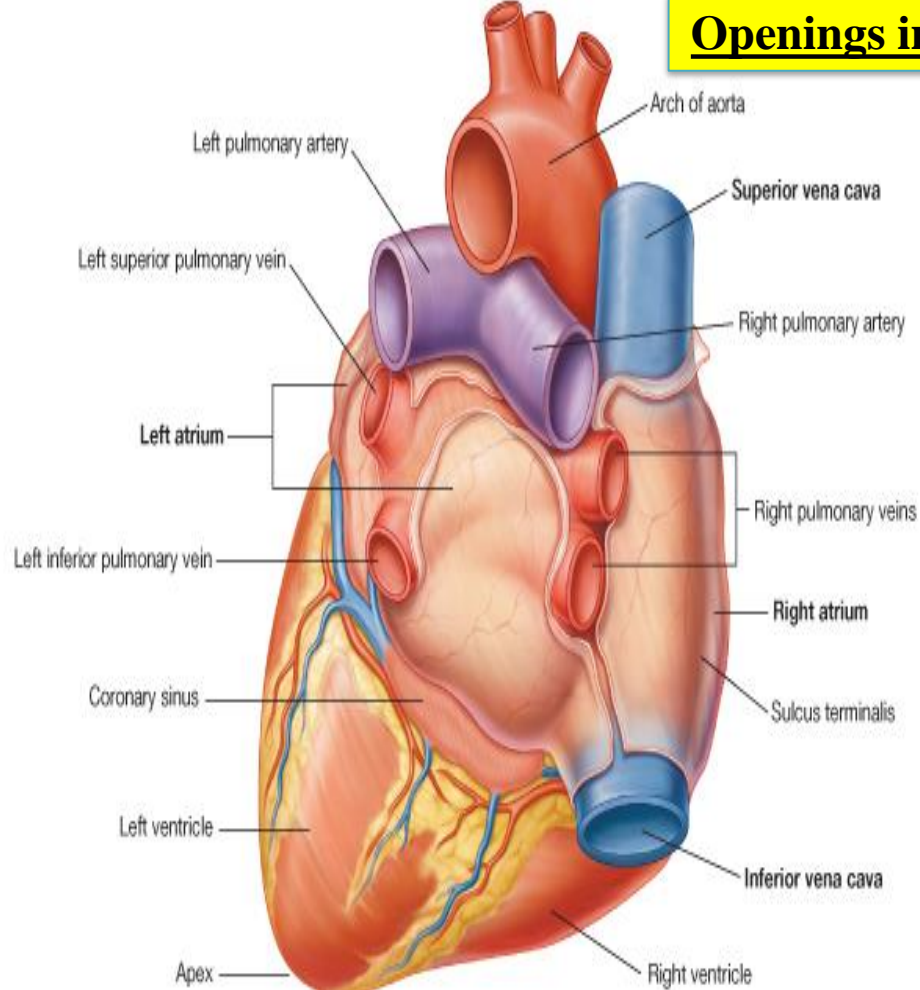


You would also identify

A semilunar depression in the interatrial septum indicates the floor of the oval fossa the surrounding ridge is the valve of the oval fossa



Openings into the Left Atrium



The valveless pairs of right and left pulmonary veins enter the smooth-walled atrium

A left AV orifice through which the left atrium discharges the oxygenated blood it receives from the pulmonary veins into the left ventricle

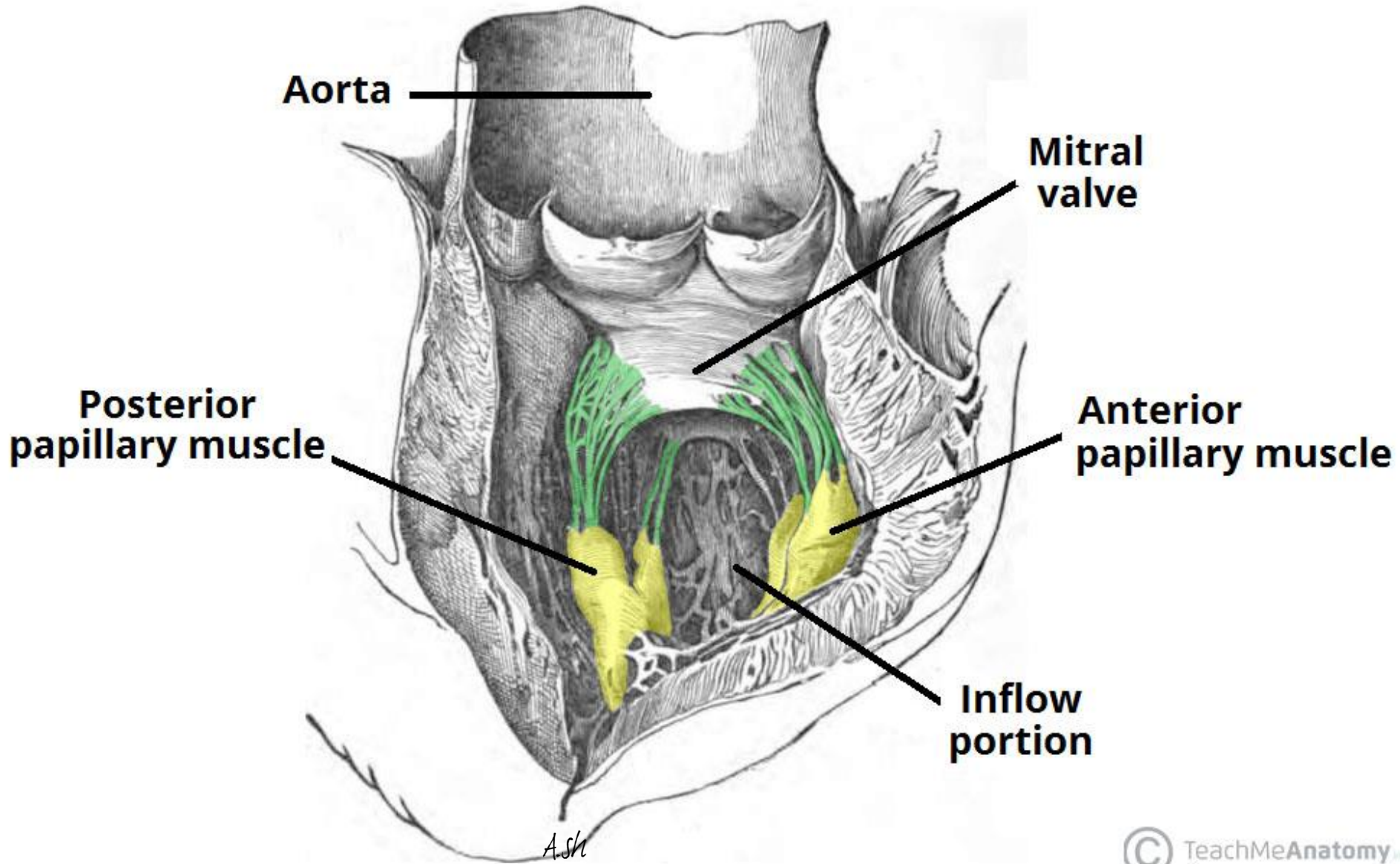
The Left Ventricle

The left ventricle has:

1-An inlet region, guarded by the mitral valve (ostium venosum)

2-An outlet region, guarded by the aortic valve (ostium arteriosum)

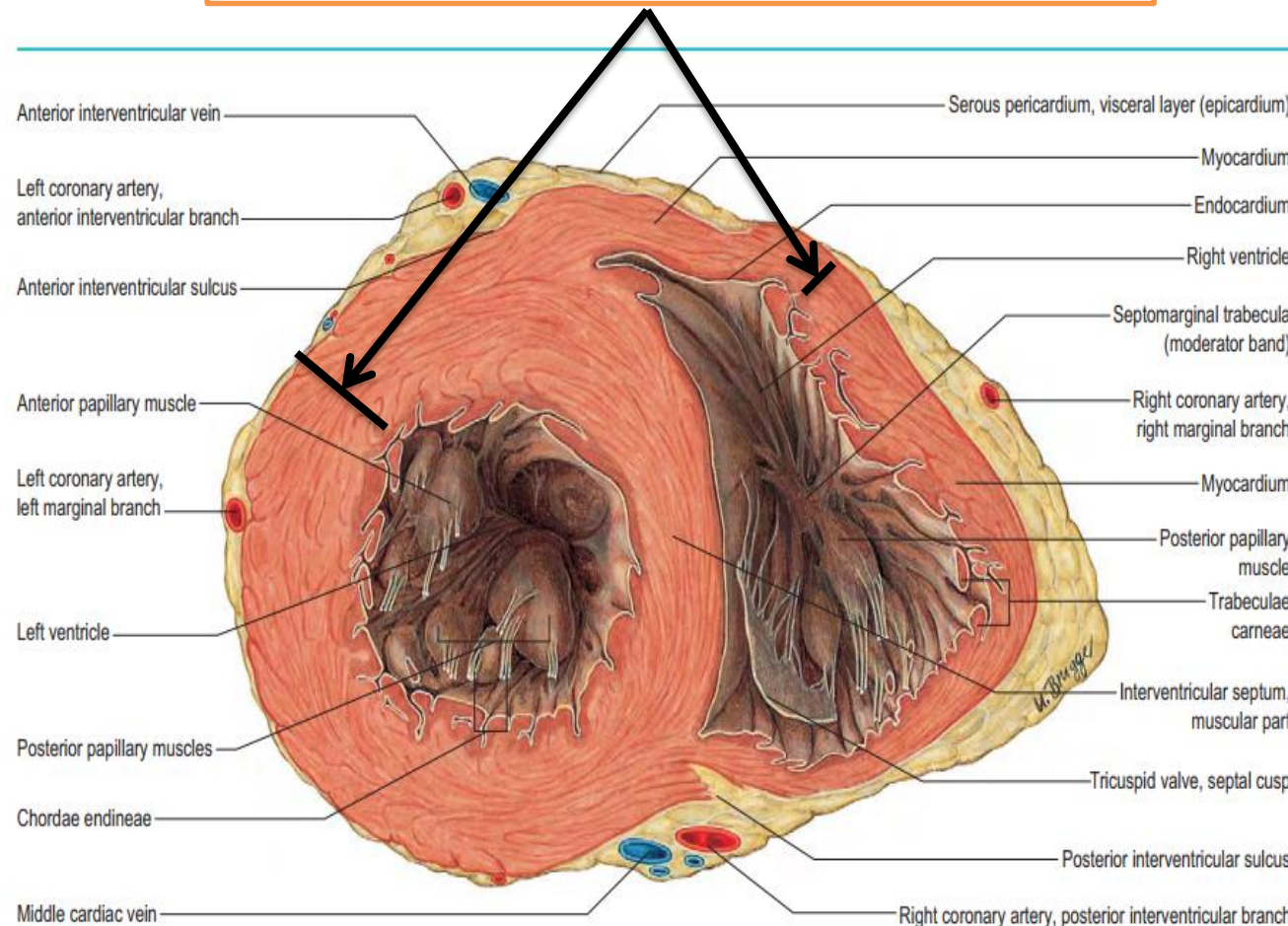
3-An apical trabecular component.



- The left ventricle forms the apex of the heart, nearly all its left (pulmonary) surface and border, and most of the diaphragmatic surface

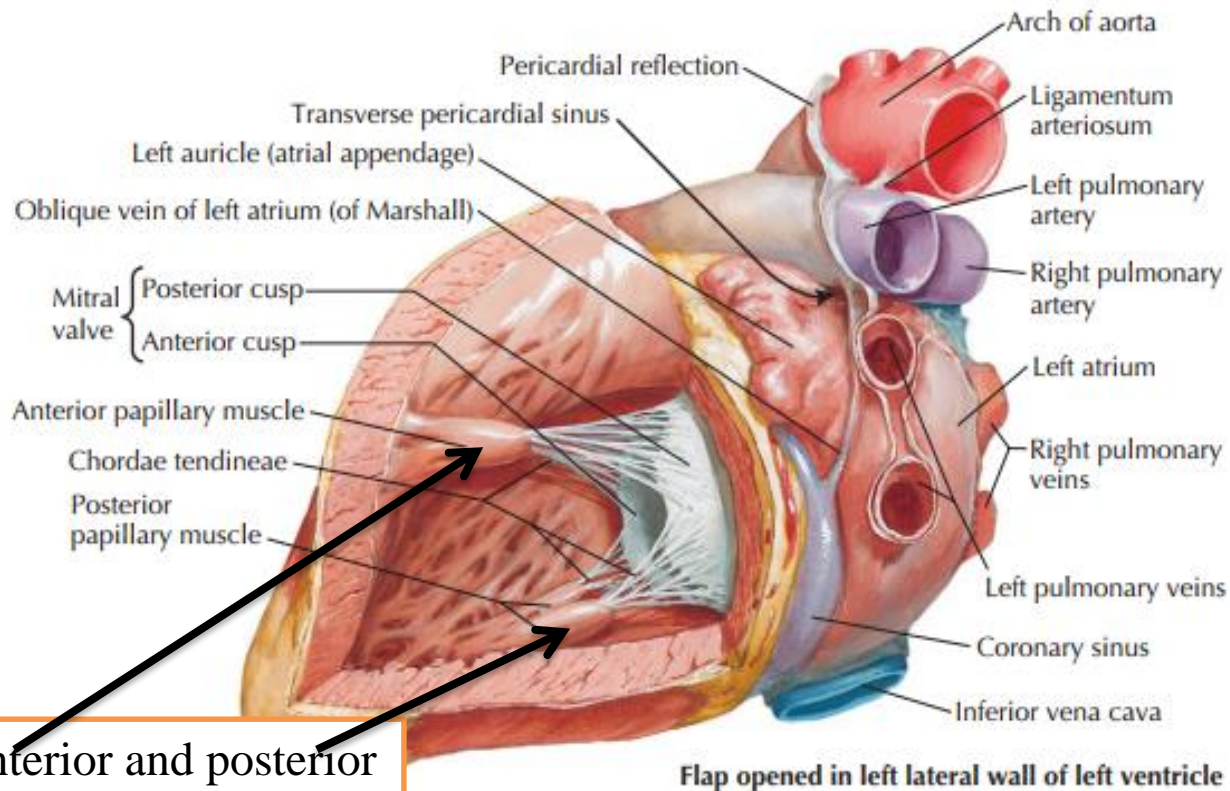
The walls of the left ventricle ***are three times thicker than those of the right ventricle***. (The left intraventricular blood pressure is six times higher than that inside the right ventricle.)

The left ventricle is a conical cavity that is longer than that of the right ventricle



LEFT ATRIUM AND LEFT VENTRICLE

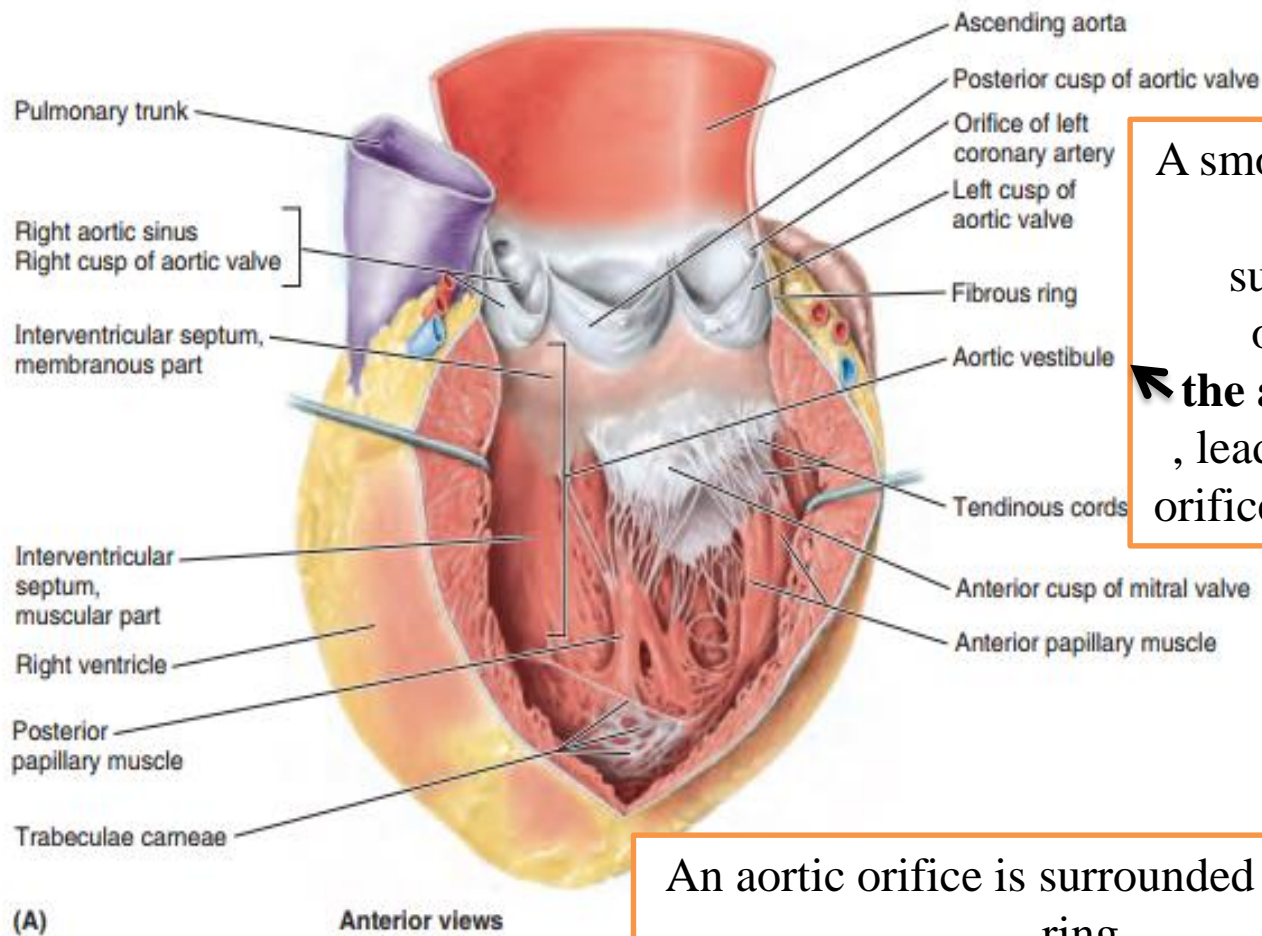
The interior of the left ventricle



a mesh of trabeculae carneae that are finer and more numerous than those of the right ventricle

Anterior and posterior papillary muscles that are larger than those in the right ventricle

A double-leaflet mitral valve that guards the left AV orifice

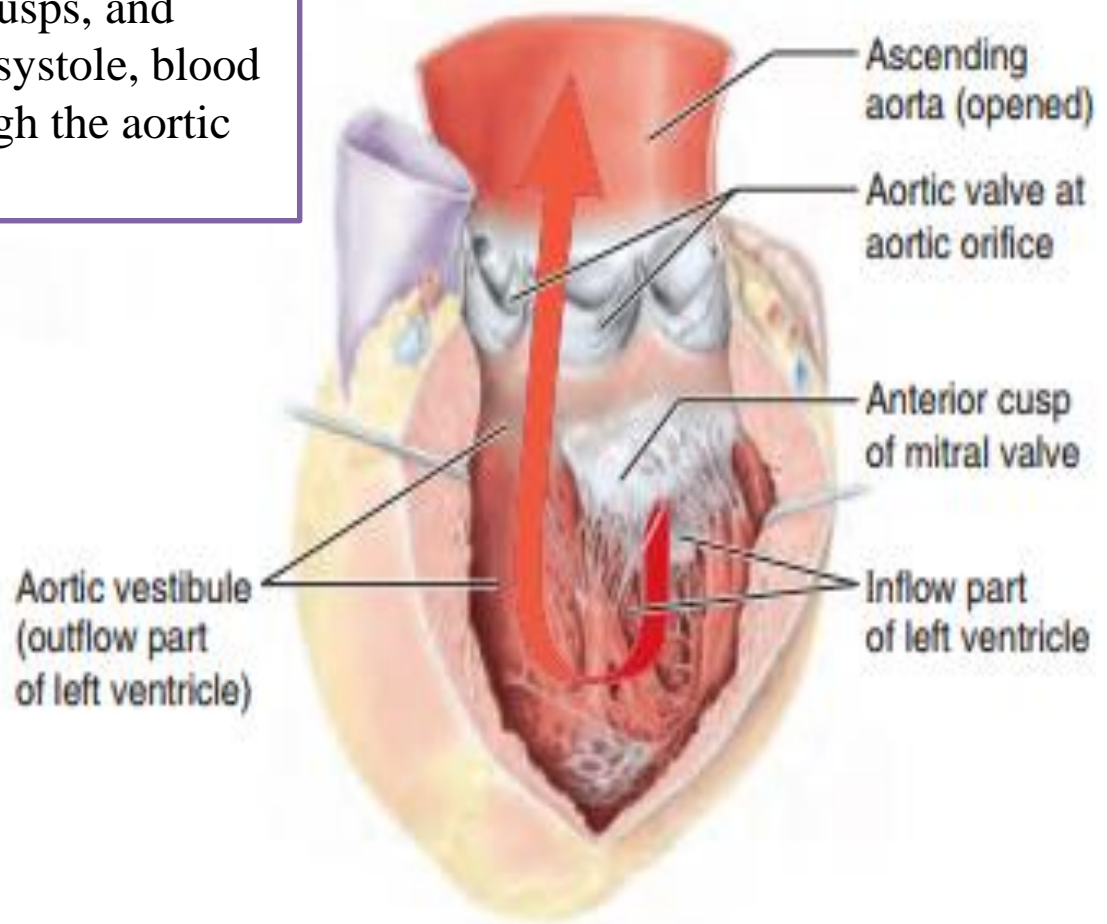


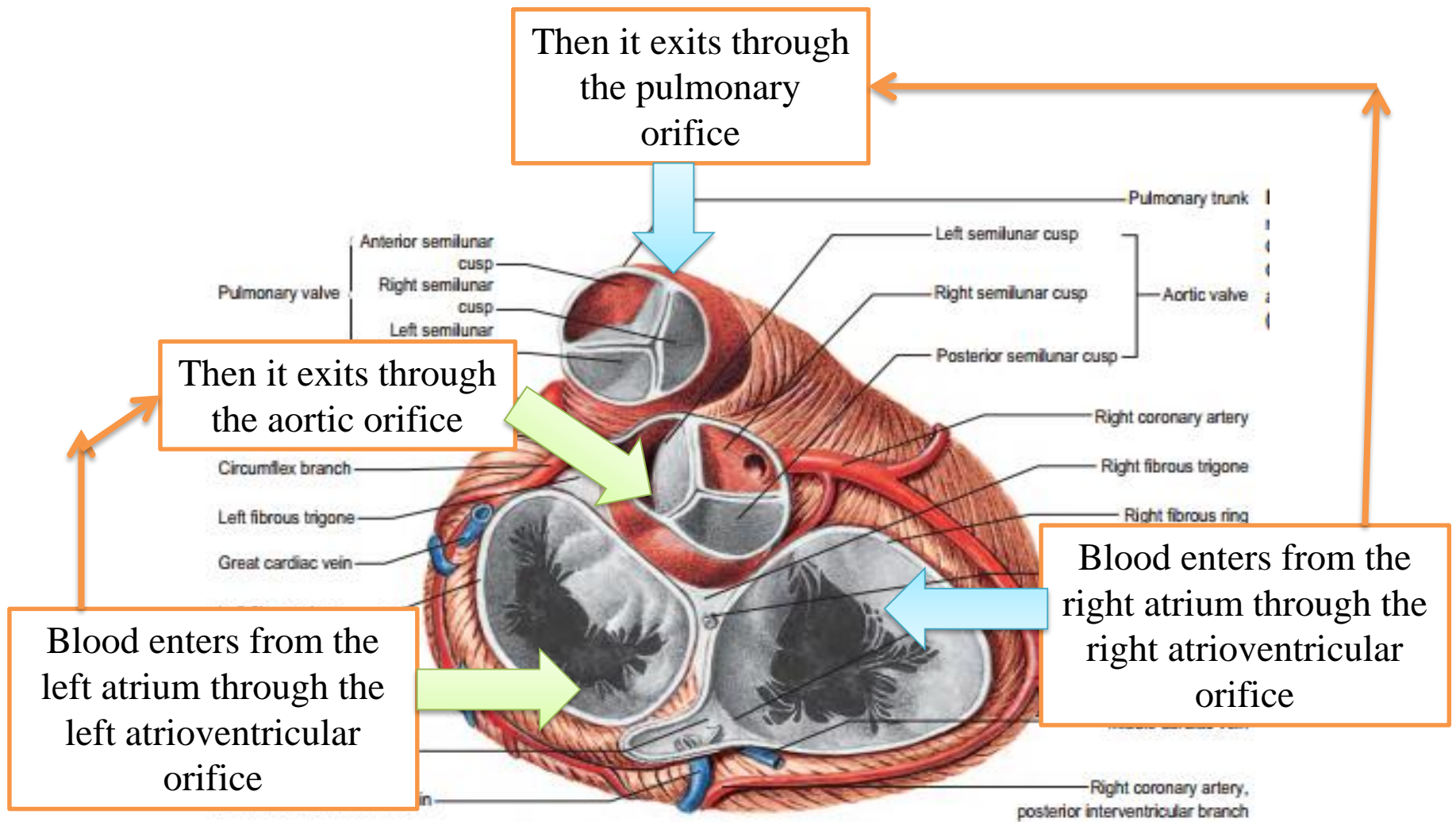
A smooth-walled, non-muscular, supero-anterior outflow part, **the aortic vestibule**, leading to the aortic orifice and aortic valve

An aortic orifice is surrounded by a fibrous ring

- The left atrioventricular orifice admits atrial blood during diastole, flow being towards the cardiac apex.
 - After closure of the mitral cusps, and throughout the ejection phase of systole, blood is expelled from the apex through the aortic orifice

The bloodstream undergoes two right angle turns, which together result in a 180° change in direction. This reversal of flow takes place around **the anterior cusp of the mitral valve**





In contrast to the orifices within the right ventricle, those of the left ventricle are in close contact, with fibrous continuity between the cusps of the aortic and mitral valves
the subaortic curtain The inlet and outlet turn sharply round this
FIBROUS CURTAIN

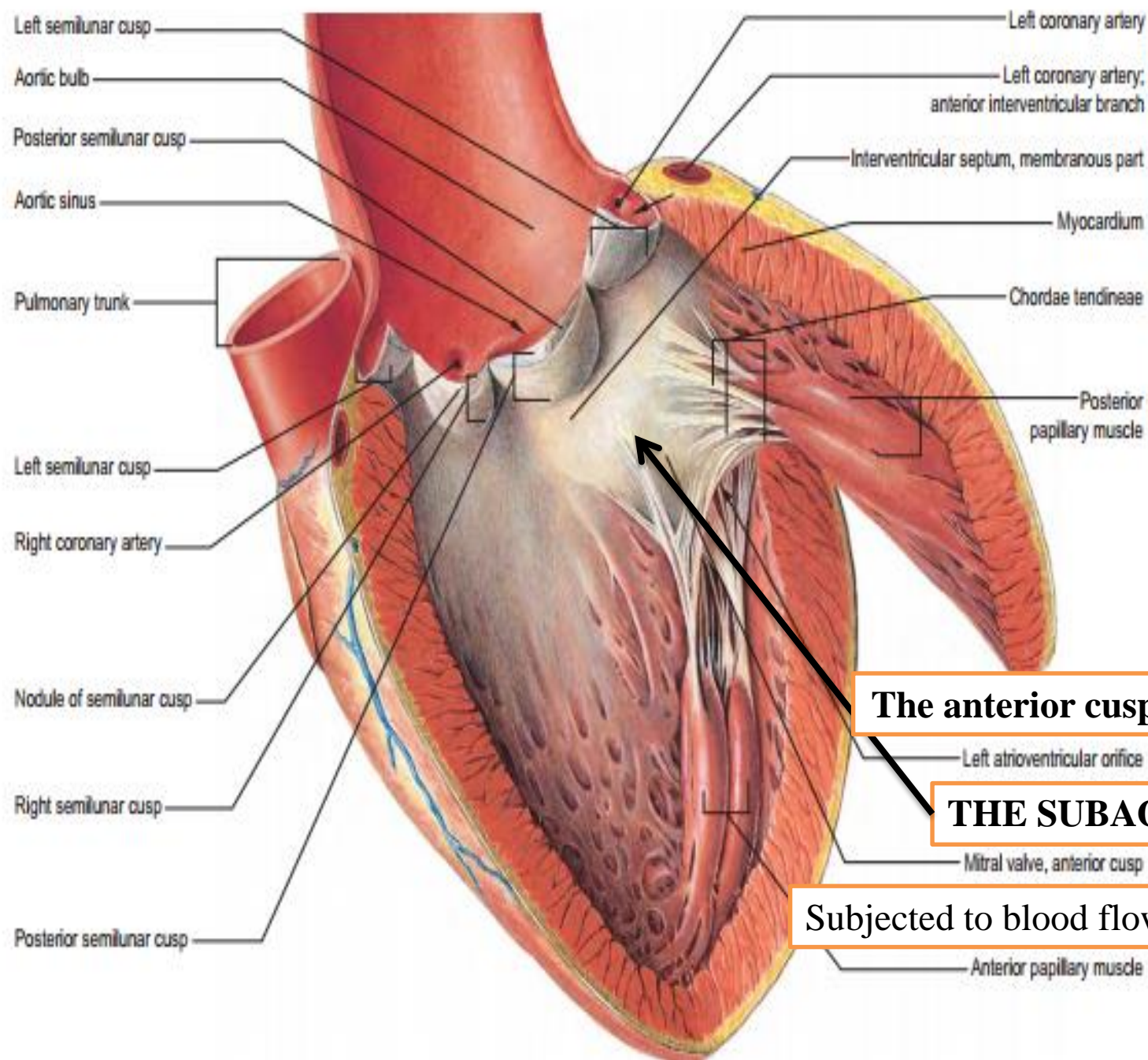


Fig. 56.13 The aortic orifice opened from the front to show the cusps of the aortic valves, their nodules, lunules, commissures and the triple-scalloped line of anular attachment. Also shown is the continuity of the subaortic curtain with the mitral anterior cusp (i.e. 'aortic baffle') and the coronary ostia, and the spatial relationship of the aortic orifice to the pulmonary orifice and to the left ventricle. (From Sobotta 2006.)

The anterior cusp of the mitral valve

THE SUBAORTIC CURTAIN

Subjected to blood flow from two sides ???