Problem Based Learning 2

Feras Fararjeh MD

13.10.2019

Case 1

- A 19 year old male college student. Presents with history of yellowish discoloration of sclera, exertional fatigue and shortness of breath. Additionally, there is left sided abdominal pain. He has family members with similar symptoms.

Case 1

- Findings:

Pallor

Jaundice (yellowish discoloration)

Splenomegaly (enlarged spleen)

Abnormal red cells on blood film

Case 1

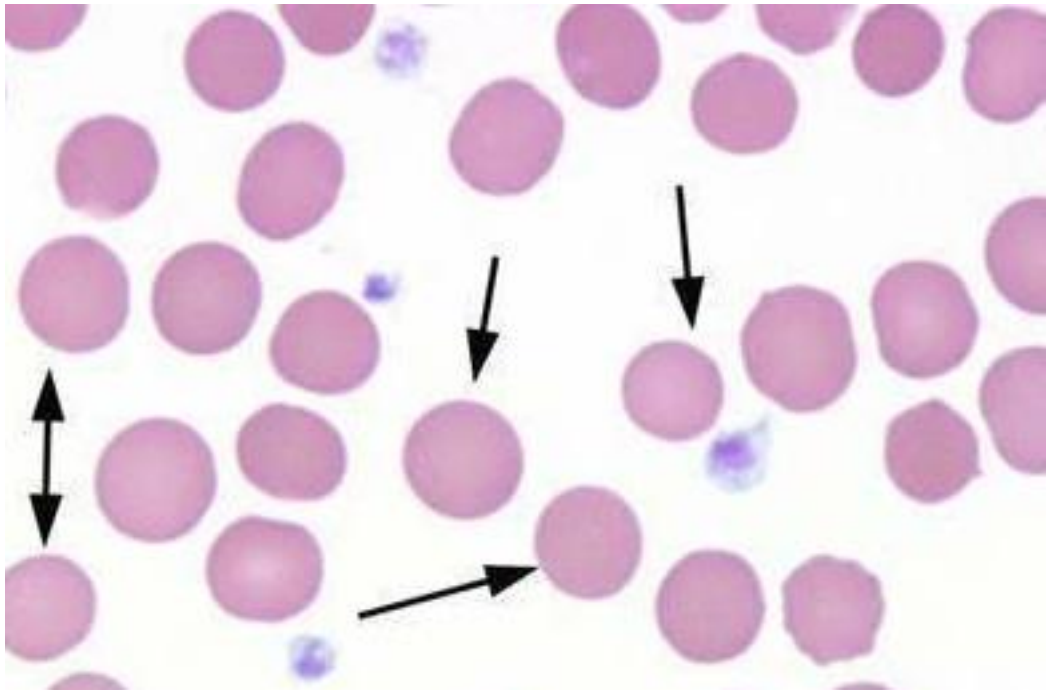

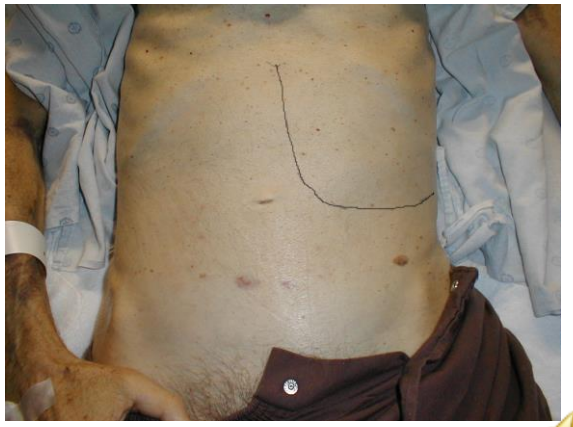

Case 1

- Hereditary spherocytosis:

A familial hemolytic disorder of red cell membrane. Generally inherited as an autosomal dominant disease

The patient presents with mild anemia and jaundice, with a modestly enlarged spleen.

There is a genetic heterogeneity of the disease and this is reflected in the clinical presentation

Case 1

The main site of red cell destruction is the spleen so the spleen size relfects the severity of hemolysis

In addition to the clinical features described above, the blood film shows small spherocytic red cells lacking area of central pallor

Case 1

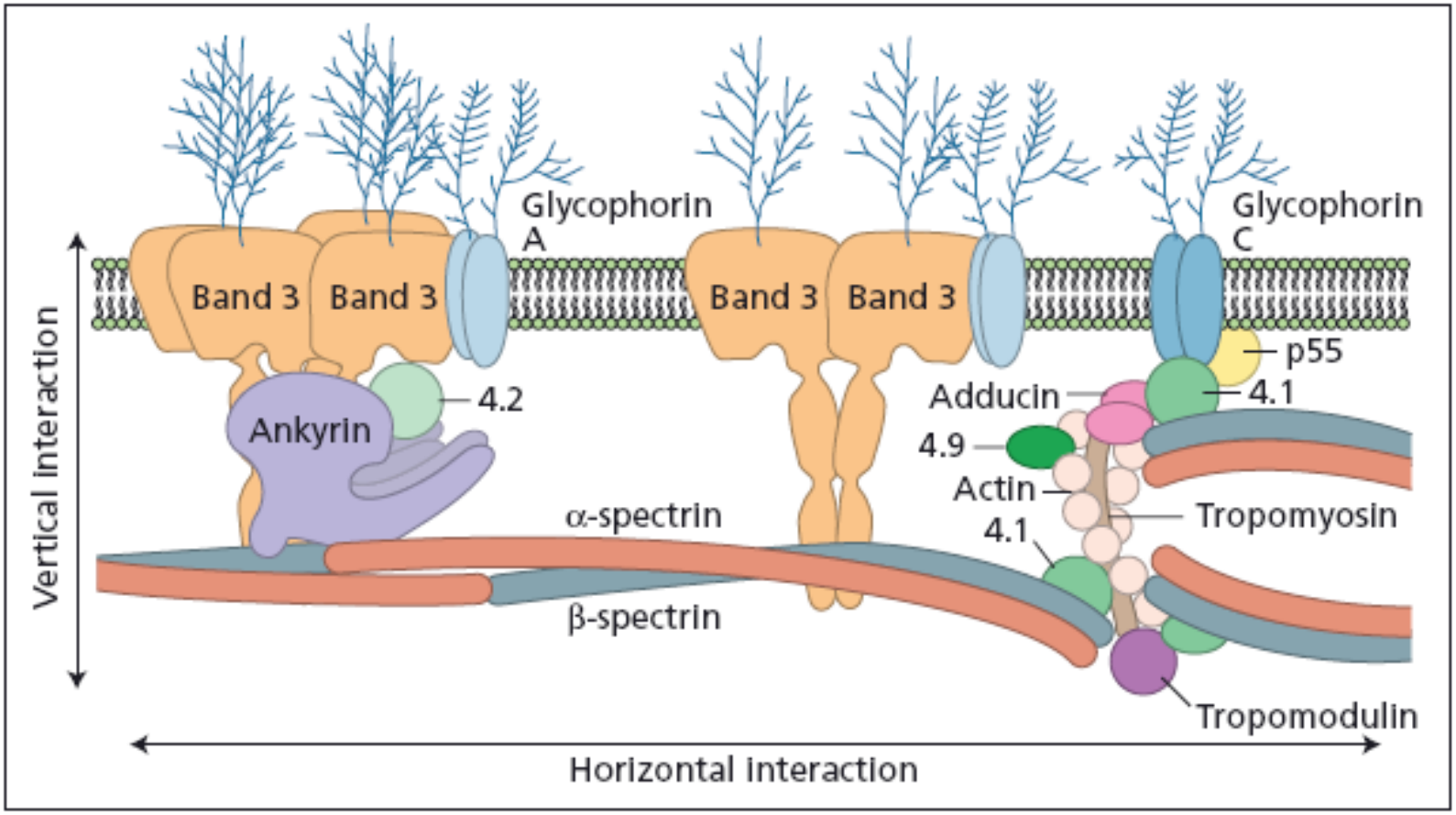

Arrangement of RBC membrane proteins. 60% of HS cases result from a defect in ankyrin-spectrin complex. The reminder involve a deficiency in band 3 or protein 4.2.

Figure from Postgraduate Haematology, 6th ed. 2011

Case 1

- Diagnosis is by Osmotic fargility test or by identification of protein abnormalities or gene defects.

Case 2

- A 24 year old male. Presents with new onset yellowish discoloration of sclera with exertional fatigue and shortness of breath. Urine is very dark. Patient was normal before attack. He had fava bean 1 day before onset of symptoms.

Case 2

- Findings:

Pallor

Jaundice (yellowish discoloration)

Abnormal red cells on blood film

Case 2

- Glucose-6-phosphate dehydrogenase (G6PD) deficiency:

Episodic acute hemolytic anemia following exposure to triggering factors.

The most common ezymatic disorder of red blood cells, affecting 400 million people worldwide.

Inherited as X-linked recessive disease. The gene for G6PD is located on the X-chromosome with more than 150 variants identified associated with variable degree of hemolytic severity.

Case 2

G6PD catalyses the first step of the pentose phosphate pathway which is the major generator of reducing power within red cells. Oxidative stress that exceeds red cell ability leads to acute hemolysis and anemia in affected patients.

Case 2

Denatured hemoglobin forms Heinz bodies in red cells. Such cells get recognised by macrophages in the spleen where the precipitate and a small piece of the memberange gets removed, leading to characteristic bite cells on standard blood film.

Case 3

- A 20 year old female college student presents with acute pain in the back, shoulder and extremities. She reports this is not the first time; attacks are more frequent in cold and stressful conditions.
- On a previous occasion, she was admitted with respiratory symptoms and had her blood exchanged.

Case 3

- Findings:

Pallor

Jaundice

Underweight

Skeletal abnormalities (medullary and epiphyseal infarction, dactylitis, marrow hyperplasia)

Leg ulcers

Abnormal red cells on blood film

Case 3

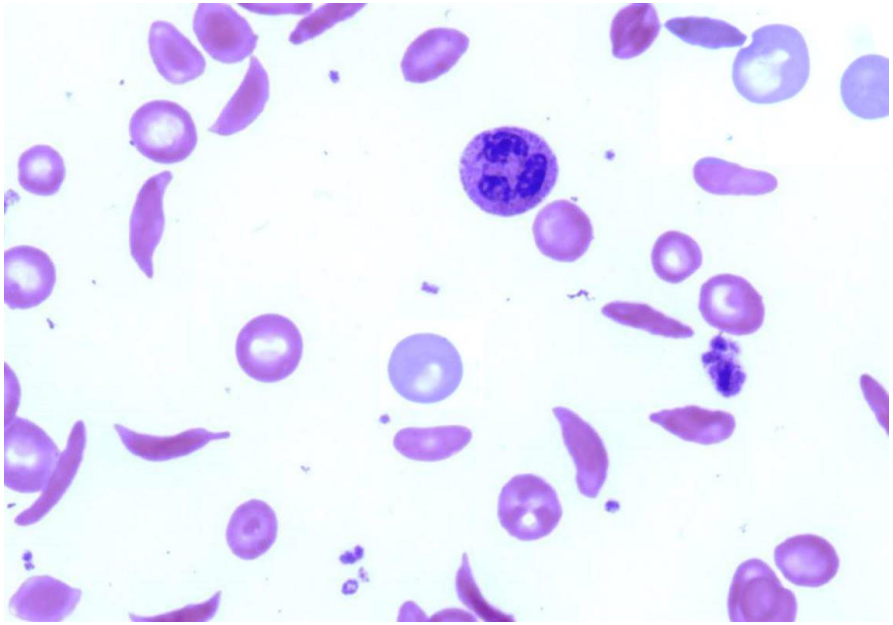

Case 3

- Sickle cell disease

An inherited chronic hemolytic anemia with different clinical manifestations arising from the tendency of hemoglobin to deform red blood cells into the characteristic sickle shape.

This property is due to a single nucleotide change in B-globin gene leading to substitution of valine for glutaminc acid at position 6 of the B-globin chain.

Case 3

- Clinical Features:

Anemia

Acute painful episodes

Abnormal growth and development

Infections

Neurological manifestations

Pulmonary complications

Sickle cell retinopathy and nephropahty

Leg ulcers

Case 4

- A 29 year old housewife presents with exertional fatigue, shortness of breath and palpitations. This started few months ago but is progressive. She had 3 complete pregnancies in the last 5 years. Her menstrual blood loss is heavy. She has no bleeding or infective symptoms. Her diet sounds balanced and she has no nausea, vomiting or altered bowel habits.

Case 4

- Findings:

Pallor

Hair loss

Koilonychia

Angular stomatitis

Abnormal red cells on blood film

Case 4

Hypochromic Microcytic Anemia (iron deficiency)

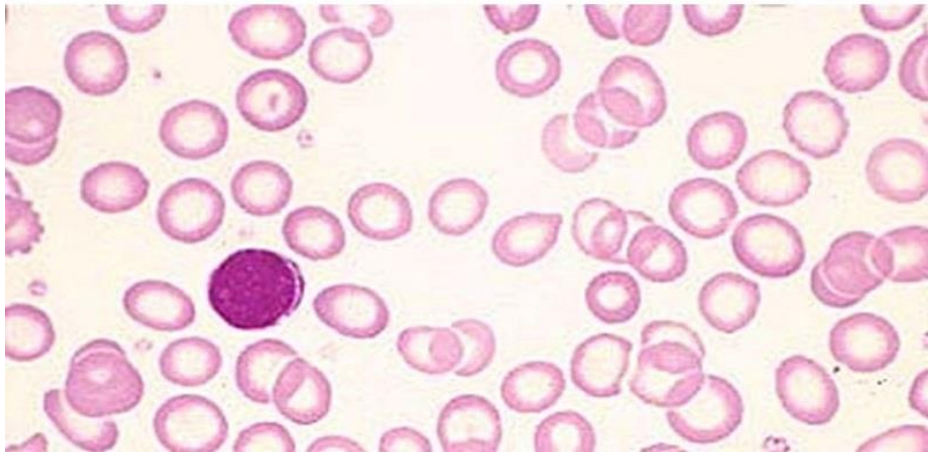

Case 4

- Iron deficiency anemia

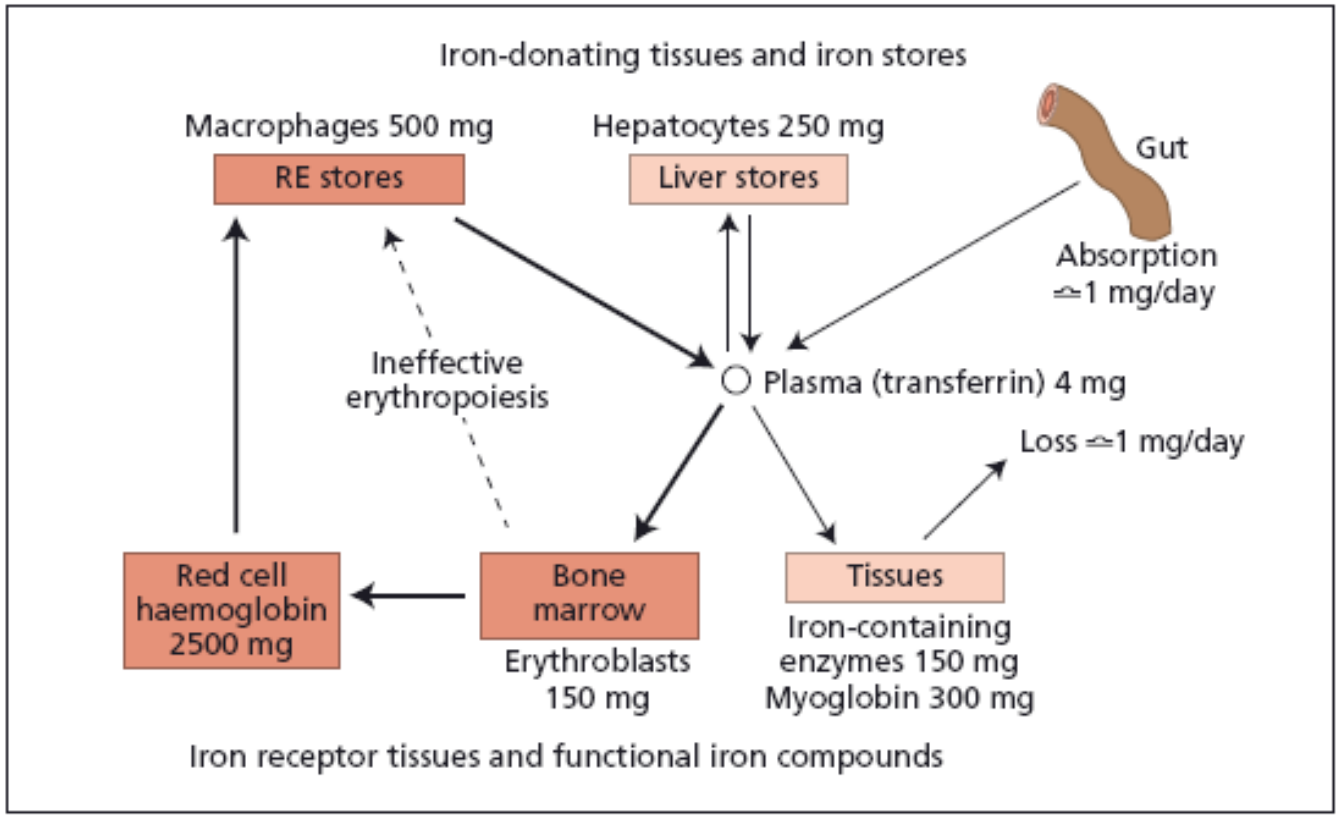

Figure 3.1 The major compartments of iron in a 70-kg man. Iron supply for erythropoiesis and release of iron from senescent red cells dominate internal iron exchange. RE, reticuloendothelial.

Figure from Postgraduate Haematology, 6th ed, 2011

Case 4

- Causes of iron deficiency anemia:

Blood loss

Increased requirements

Diet

Malabsorption

Case 5

- A 62 year old retired engineer. He has new symptoms of exertional fatigue and shortness of breath. This started around 2 months ago. He also noticed a change in his bowel habits recently and thinks he is losing weight.
- He is not vegetarian and his diet sounds balanced.

Case 5

- Findings:

Pallor

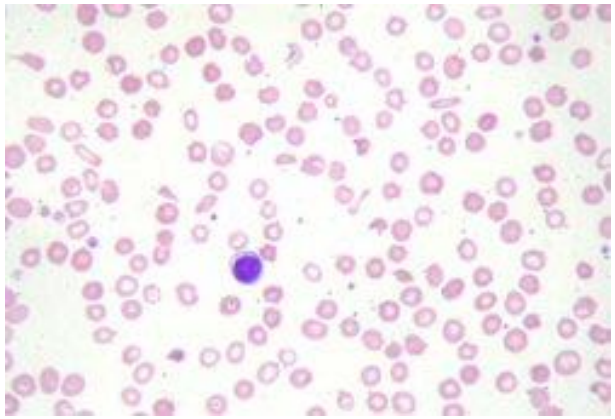

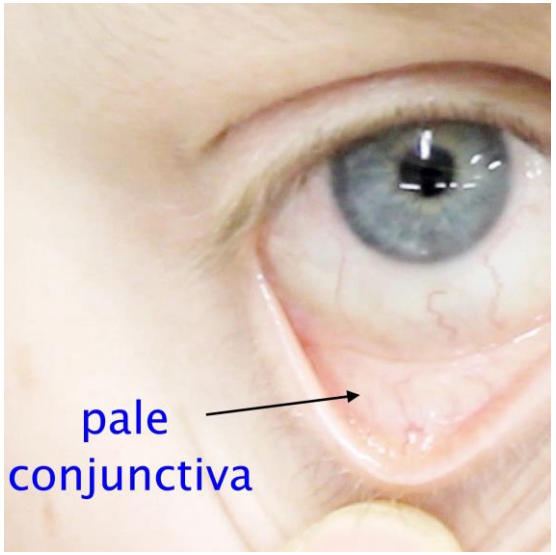

What is the next thing to do?

Case 5

- Causes of iron deficiency anemia:

Blood loss

Increased requirements

Diet

Malabsorption.

Case 6

- A 42 year old female with history of surgery done 10 years ago for morbid obesity (gastric by pass) presents with exertional fatigue and shortness of breath. She reports some mental sluggishness and inability to walk normally. Her family think she is becoming depressed and more forgetful. She is not attending her scheduled clinic visits and not taking her prescribed medications.

Case 6

- Findings:

Pallor

Mild jaundice

Symmetric paresthesias/numbness

Shuffling gait

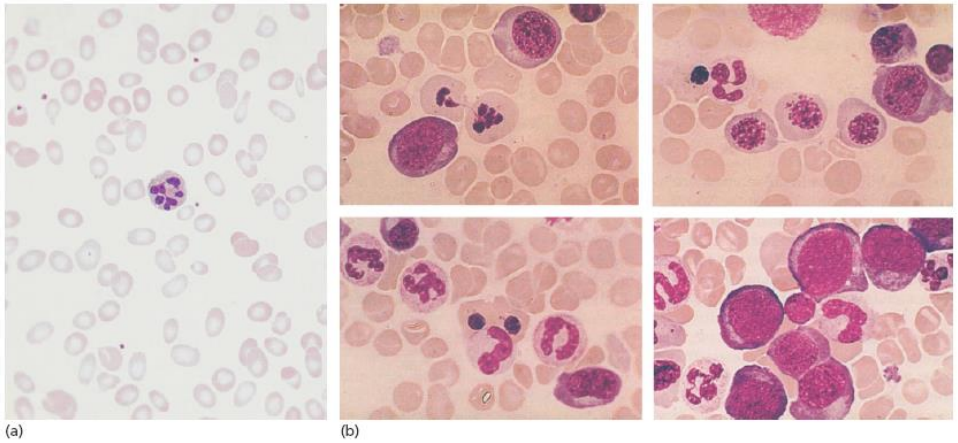

Figure 5.4 Severe megaloblastic anaemia: (a) peripheral blood; (b) bone marrow.

What is the next thing to do?

Case 6

- Vitamin B12 deficiency:

Main causes are dietary and malabsorption.

In addition to anemia, neurological symptoms can occur and should be corrected as soon as possible once the disease is suspected. Such symptoms can occur regardless of presence of anemia

In severe cases, ineffective erythropoiesis and hemolysis occur.

Case 6

Table 5.5 Causes of cobalamin deficiency causing megaloblastic anaemia.

Nutritional
Vegans
Malabsorption
Pernicious anaemia
Gastric causes
Congenital intrinsic factor deficiency or functional abnormality
Total or partial gastrectomy
Intestinal causes
Intestinal stagnant loop syndrome: jejunal diverticulosis, ileocolic fistula, anatomical blind loop, intestinal stricture, etc.
Ileal resection and Crohn's disease
Selective malabsorption with proteinuria
Tropical sprue
Transcobalamin deficiency
Fish tapeworm

From Postgraduate Haematology, 6th ed, 2011

Case 7

- A 64 year old lady presents with acute onset of symptoms that started one week ago:

- Fatigue
- Palpitations
- Shortness of breath
- Fever
- Cough with sputum
- Gum bleeding
- Skin bruising

No previous episodes and no family history of similar conditions

Case 7

- Findings:

- Pale
- Documented fever
- Skin bleeding (Ecchymosis, petechial rash)
- Abnormal blood film and bone marrow
- Bone marrow is hypercellular and replaced by abnormal cells

Case 7

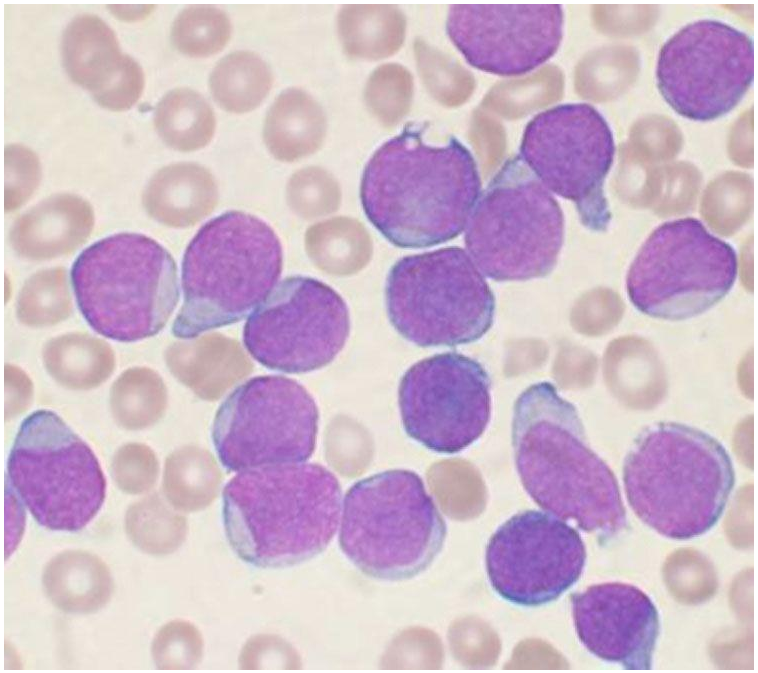

Case 7

- The triad of anemia, infection and bleeding suggests pancytopenia.
- In this case, pancytopenia is due to replacement of normal bone marrow by abnormal immature cells (blasts) indicating presence of acute leukemia

Case 7

- Acute leukemias are either myelocytic or lymphocytic. Differentiating both conditions clinically can be difficult and certain additional tests are needed to do so.

- This patient needs treatment of her infection, support by blood and platelets and needs to start treatment with chemotherapeutic agents appropriate for her disease.

Case 8

A 40 year old gentleman presents with acute onset of symptoms that started one week ago:

- Fatigue
- Palpitations
- Shortness of breath
- Fever
- Gum bleeding
- Skin bruising

No previous episodes and no family history of similar conditions

Case 8

- Findings:

- Pale

- Documented fever

- Skin bleeding (Ecchymosis, petechial rash)

- Blood film showing reduced cell numbers but no abnormal cells.

- Bone marrow is markedly hypocellular

Case 8

- Another collection of clinical symptoms suggesting pancytopenia with different findings in the bone marrow.
- The bone marrow is hypocellular or aplastic. This is seen in aplastic anemia which can be inherited or acquired.

Case 8

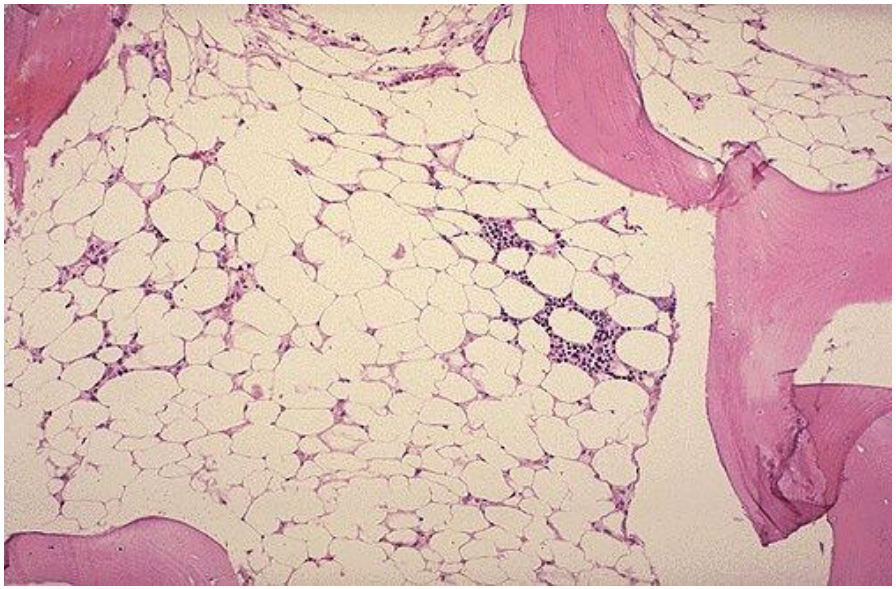

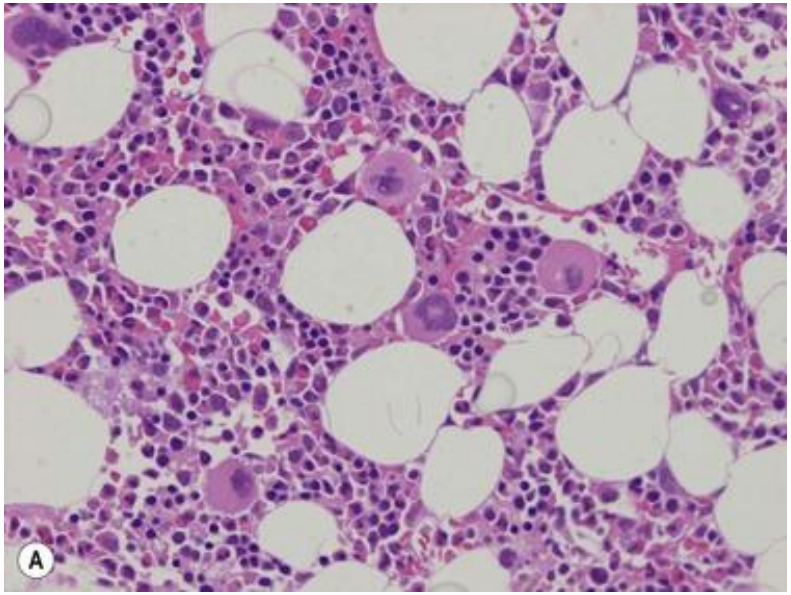

Case 8

- The severity of aplastic anemia depends on the residual cellularity in the examined bone marrow and the degree of pancytopenia present.

- If severe disease present, this patient treatment options includes immunosuppression or hematopoietic stem cell transplant. Chemotherapy or steroids are not effective.

Case 9

- A 7 year old boy presents with swollen knee of few days duration. This is not the first time it happens. Both knees and ankles are affected but his right knee is affected most. Symptoms start by feeling of hotness in the joint followed by swelling, pain, reduced ability to move and hot skin.
- His mother reports he bled abnormally after circumcision. He has not had any surgical procedures done. His mother thinks that some of her family members had similar symptoms.

Case 9

- Findings:
- Swollen knee (with effusion) with hotness and reduced movement.

Source: Lichtman MA, Kipps TJ, Seligsohn U, Kaushansky K, Prchal JT: Williams Hematology, 8th Edition: http://www.accessmedicine.com
Copyright © The McGraw-Hill Companies, Inc. All rights reserved.

Case 9

- Hemophilia

X- linked recessive disease leading to low coagulation factors (FVIII low in hemophilia A and FIX low in hemophilia B)

The disease is usually inherited but sporadic cases (without family history, presumed due to a new mutation) is also common.

Case 9

- Symptomatic patient are usually those with severe disease (Factor level <1%).
- Increased bleeding episodes mainly affecting load- or strain-bearing joints (ankles, knees, and elbows). Recurrent bleed into particular joints lead to joint deformities and disabilities. Other forms of bleeding include large muscular bleed and less commonly urinary or CNS bleeding.

Case 9

- Patient with severe disease should be treated with replacement therapy. Factor VIII or IX should be given as prophylaxis in order to keep level between 5-30% as this would prevent most bleeding episodes.
- This can vary according to patient life style and level of physical activity
- Additional doses may be needed to treat breakthrough bleeding or before and after surgical procedures

Thank you