Pathology of the stomach-part 2

Manar Hajeer, md, FRCPath

University of Jordan, School of medicine

Peptic Ulcer Disease

- **H. *pylori* infection or NSAID use**
- Imbalance between mucosal defenses and damaging forces.
- In USA: H.*pylori* infection is falling and increased use of low-dose aspirin in aged population.

- Any portion of the GIT exposed to acidic gastric juices
- Most common in gastric antrum, first part of duodenum.
- Esophagus in (GERD) or ectopic gastric mucosa (Meckel diverticulum)

Pathogenesis

- > 70% of PUD caused by H. *pylori* infection
- Only 5 -10% of H. *pylori*–infected individuals develop ulcers.
- **Gastric acid is fundamental in pathogenesis.**
- **Cofactors: smoking, chronic NSAIDs, high-dose corticosteroids, alcoholic cirrhosis, COPD, CRF, hyperparathyroidism**.

- **Hyperacidity is caused by**:
- H. pylori.
- Parietal cell hyperplasia.
- Excessive secretory response (vagal)
- Hypergastrinemia as in *Zollinger-Ellison syndrome*

Zollinger-Ellison syndrome

- Multiple peptic ulcerations
- Stomach , duodenum, even jejunum
- Caused by uncontrolled release of gastrin by a tumor (gastrinoma: massive acid production)

MORPHOLOGY

- 4:1, proximal duodenum : stomach.
- Anterior duodenal wall
- >80% solitary.
- Round to oval, sharply punched-out defect
- Base of ulcers is smooth and clean
- Granulation tissue.
- Hemorrhage & Perforation are complications.

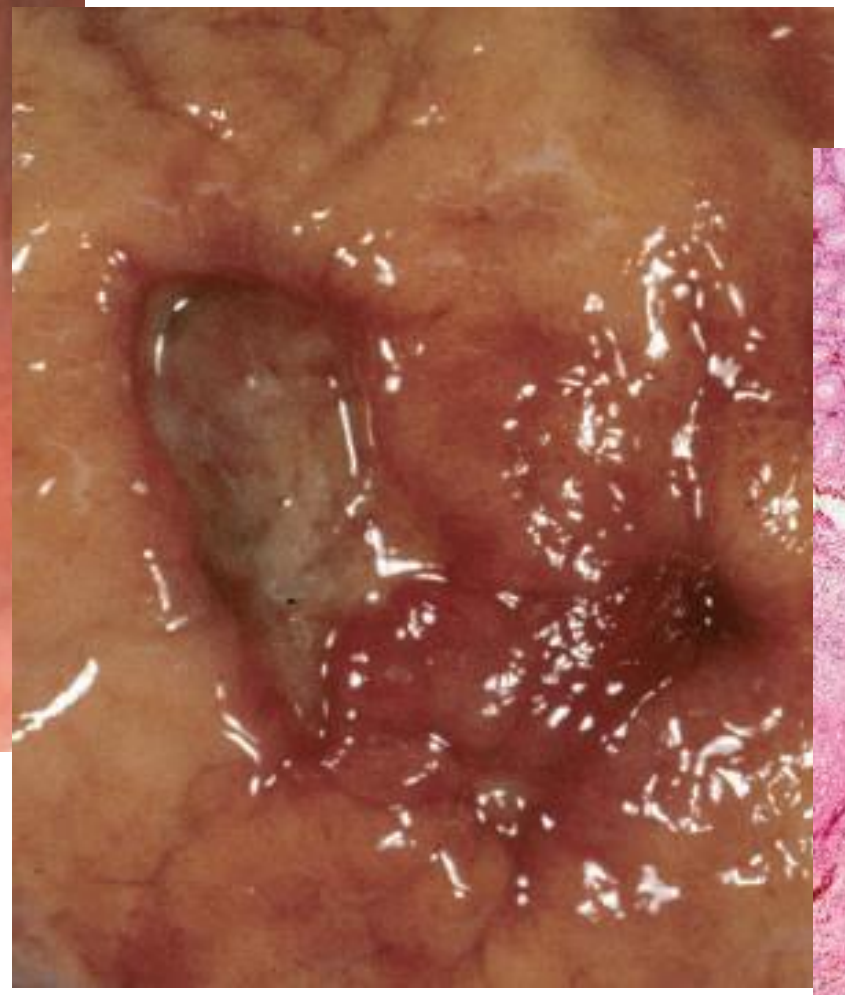

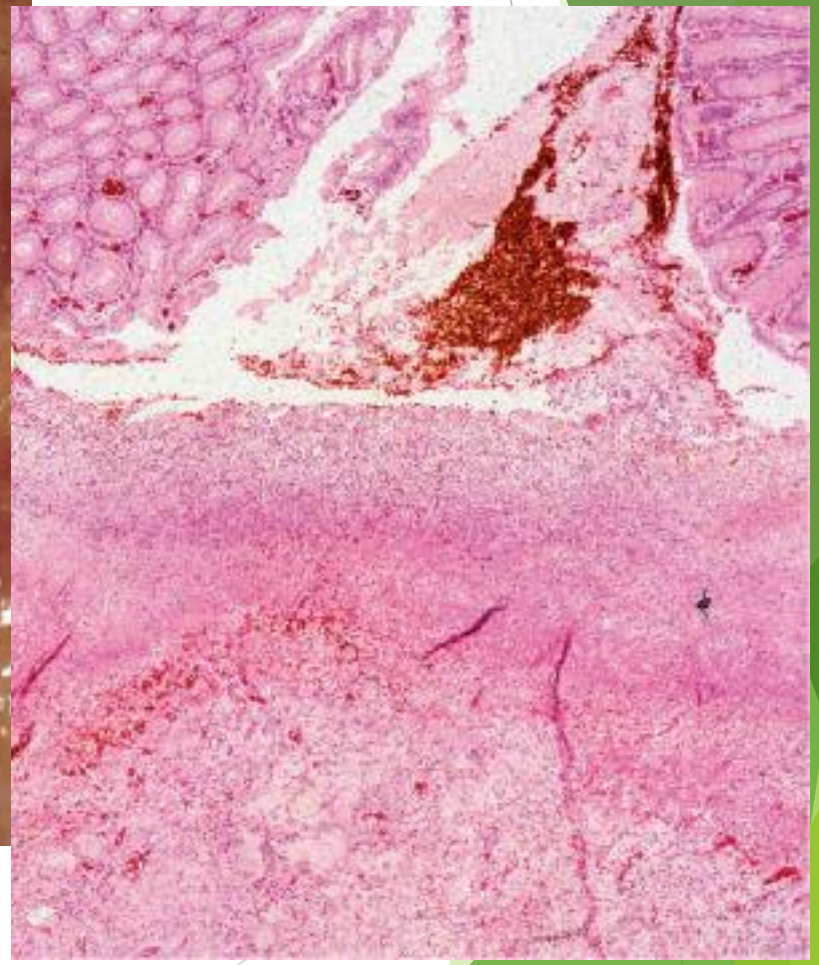

Robbins Basic Pathology 10th edition

Gastric ulcer

http://ar.utmb.edu/webpath/gihtml/gi019.htm

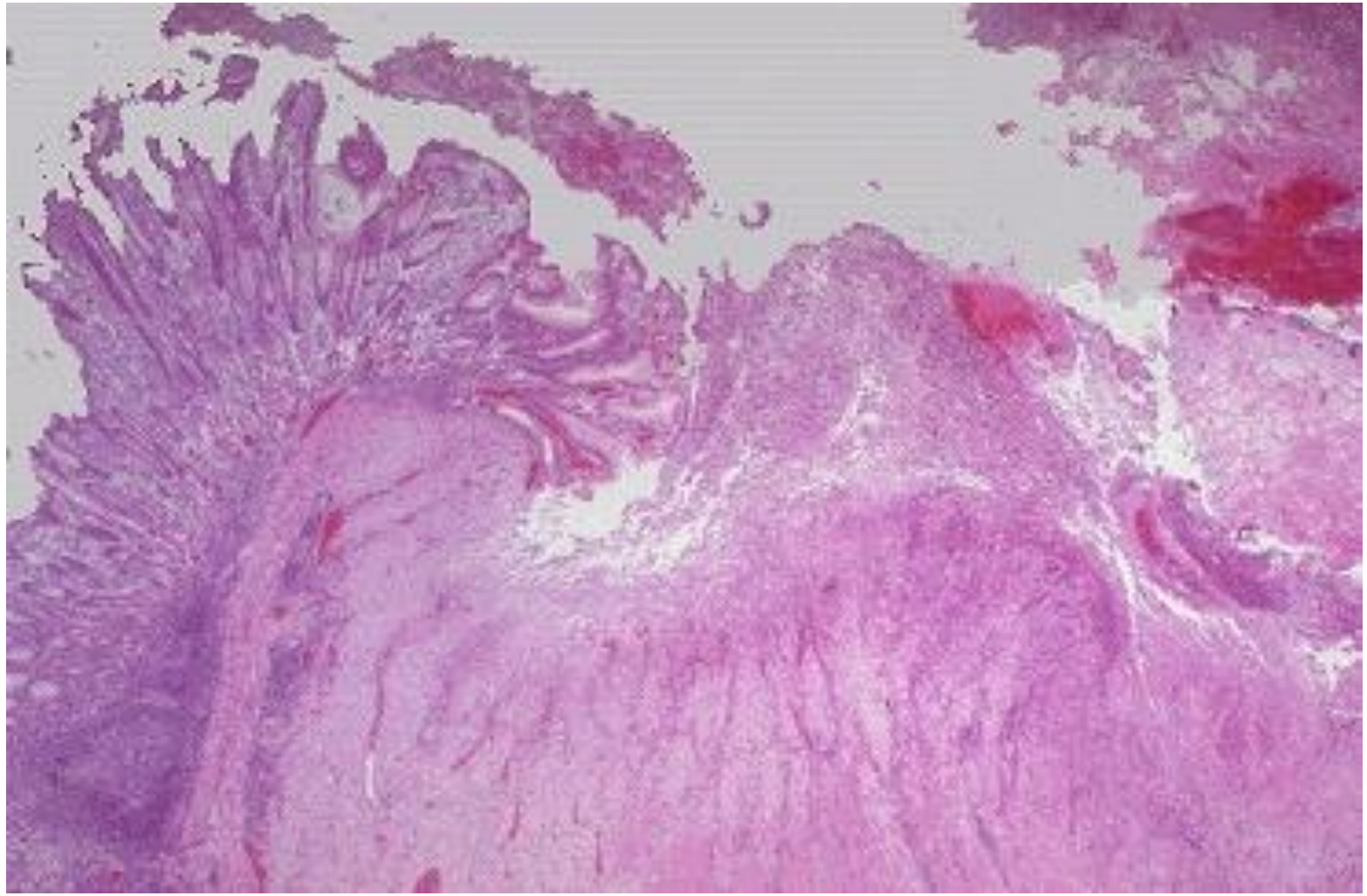

http://ar.utmb.edu/webpath/gihtml/gi019.htm

Clinical Features

- Epigastric burning or aching pain
- Pain 1 to 3 hours after meals at daytime
- Worse at night, relieved by alkali or food
- Nausea, vomiting, bloating, bletching.
- Iron deficiency anemia, frank hemorrhage, or perforation.

- Current therapies are aimed at H.pylori eradication.
- Surgery reserved for complications.

GASTRIC POLYPS AND TUMORS

- Gastric Polyps:
- Inflammatory and Hyperplastic Polyps
- Gastric Adenoma

- Gastric Adenocarcinoma
- intestinal and diffuse types

- Lymphoma
- MALToma.

- Neuroendocrine (Carcinoid) Tumor
- Gastrointestinal Stromal Tumor

Gastric polyps

- Polyps: masses projecting above the level of adjacent mucosa
- Epithelial or stromal cell hyperplasia, inflammation, ectopia, or neoplasia.

- **Inflammatory and Hyperplastic Polyps**
- 75% of all polyps.
- Arise in a background of chronic gastritis
- Regress after H.pylori eradication.
- Risk of dysplasia if size > 1.5 cm.

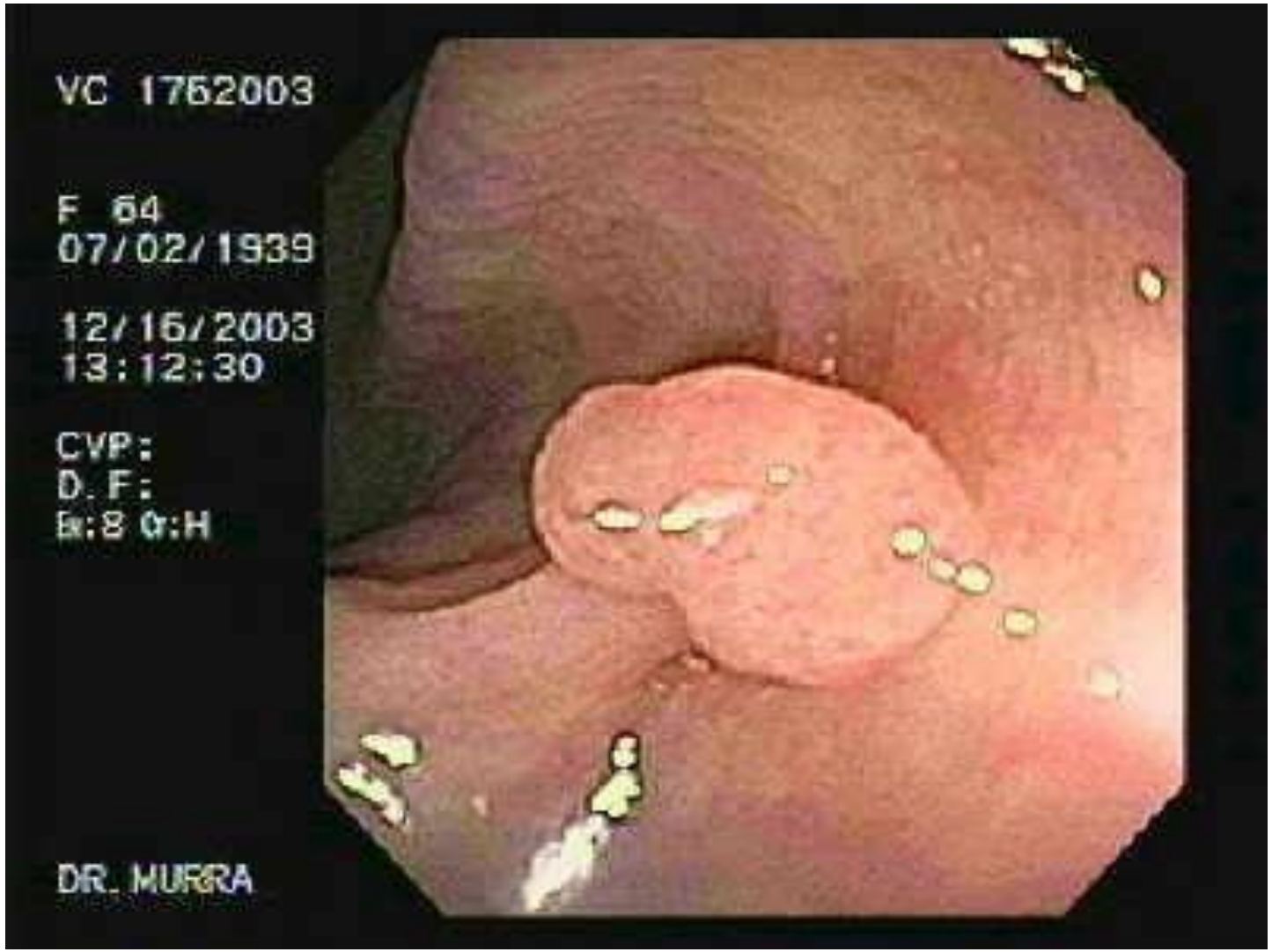

plus.google.com

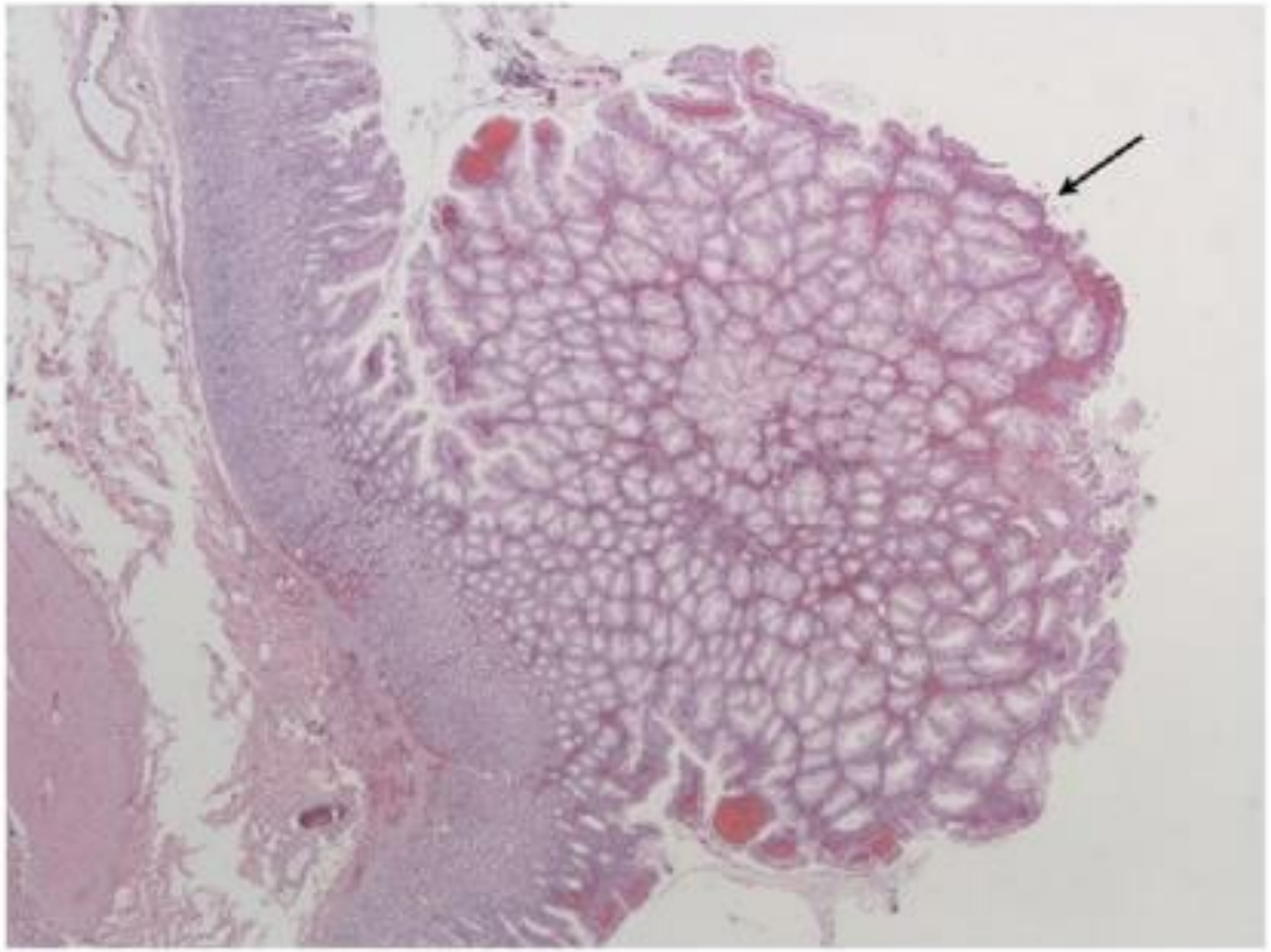

https://www.hindawi.com/journals/crigm/2013/631975/fig1/

Gastric Adenoma

- 10% of all polyps.
- Increase with age.
- M:F = 3:1
- Background of chronic gastritis, atrophy and intestinal metaplasia.
- Dysplasia in all cases, low- or high-grade.
- Risk of adenocarcinoma related to the size (greatest if > 2cm).
- Risk of carcinoma higher than colonic adenoma.
- **30% have concurrent CA**.

Gastric Adenocarcinoma

- 90% of all gastric cancers.
- Early symptoms mimic gastritis >>> late diagnosis.
- Rates vary markedly with geography (Japan, Costa Rica, Chile).
- Screening >> early detection.
- **Background of *mucosal atrophy and intestinal metaplasia*.**
- ***PUD does not increase risk*.**

- ***In USA rates dropped > 85%, BUT increased rate of cardia cancer due to GERD & obesity*.**
- ***Two main types: intestinal and diffuse*.**

Pathogenesis

- Genetic alterations due to H.pylori associated chronic gastritis , lesser extent EBV (10%).
- Most cases are sporadic.

- Familial diffuse type: mutations in *CDH1* (E-cadherin).
- Sporadic diffuse type: CDH1 (E-cadherin) mutation in 50%, and methylation in the rest.

- Familial intestinal type, with FAP: APC gene mutation.
- Sporadic intestinal-type Ca: B catenin mutation, MSI…….etc

- **P53 mutation in sporadic cancer of both types.**

MORPHOLOGY

- Lauren classification: separates gastric cancers into intestinal and diffuse types.
- **Intestinal type:**
- Bulky.
- Exophytic mass or ulcer.
- Form glands.

- **Diffuse gastric cancers**
- Infiltrative growth pattern
- Discohesive cells (signet ring cells)
- Desmoplastic reaction (thick wall, linitis plastic).

Intestinal type

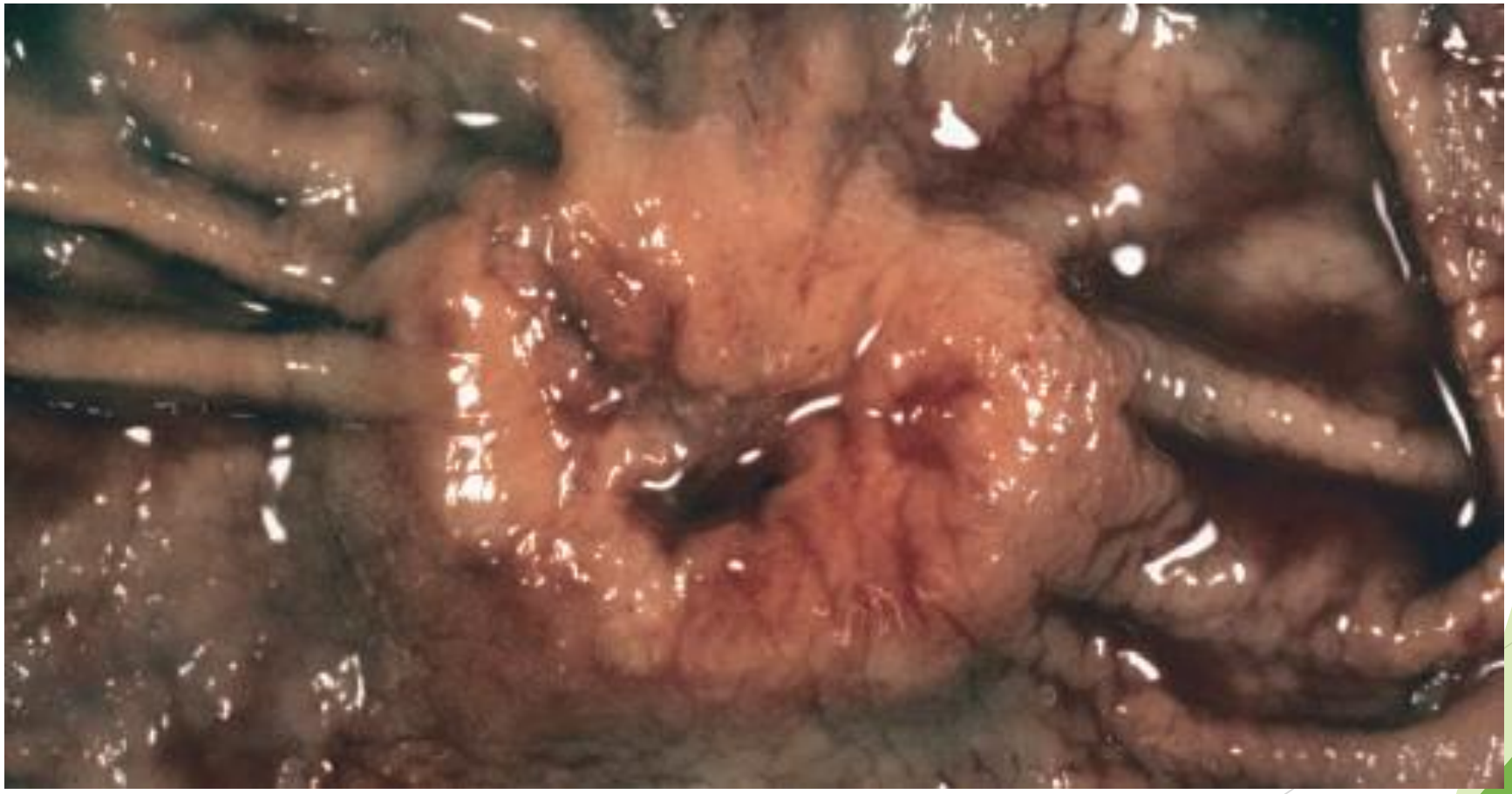

Robbins Basic Pathology 10th edition

Linitis plastica

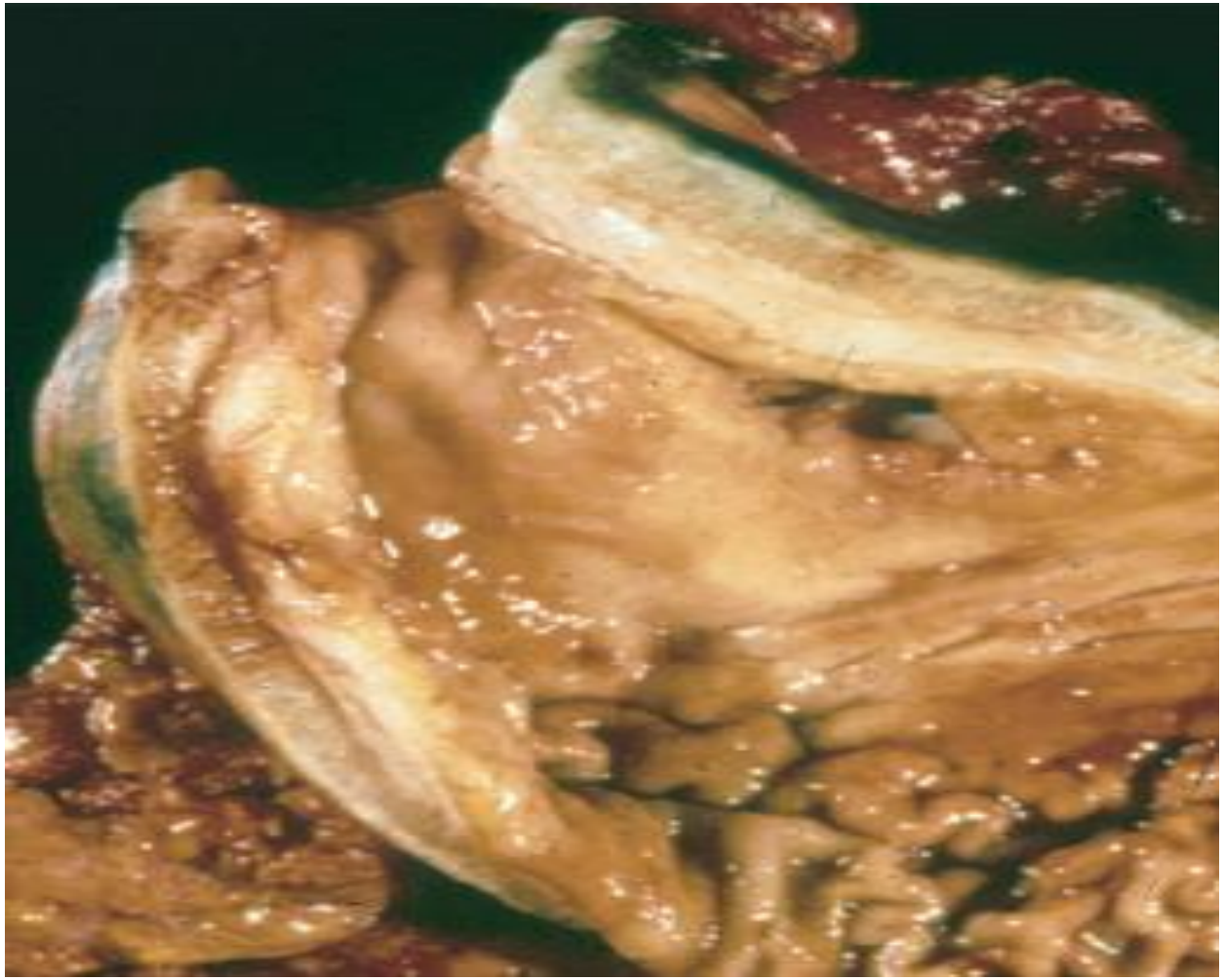

Robbins Basic Pathology 10th edition

Signet ring cells:
large mucin vacuoles that expand the cytoplasm and push the nucleus to the periphery,

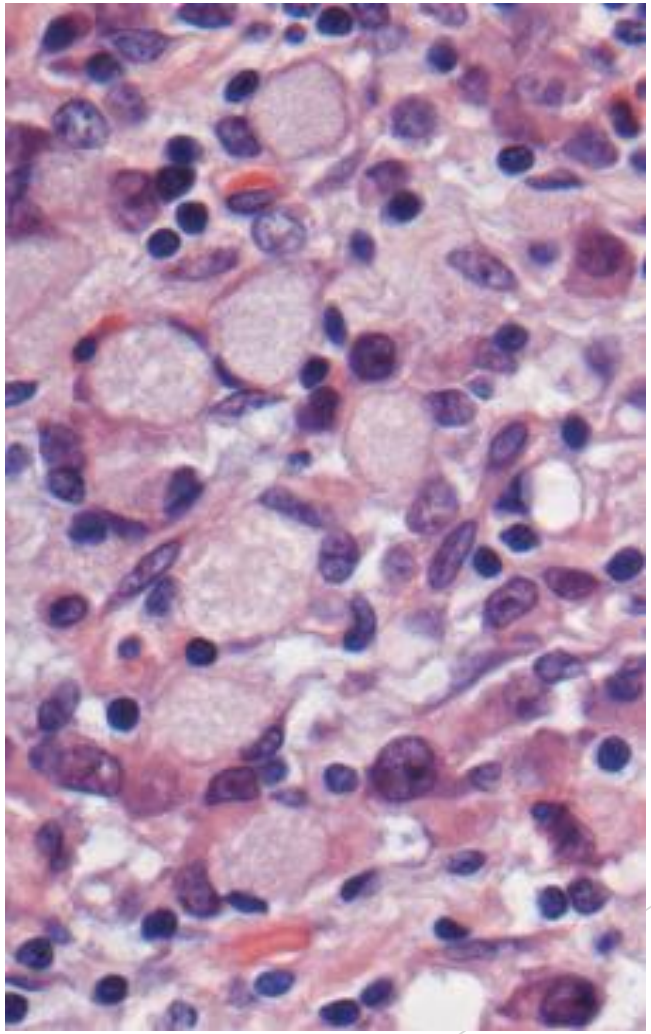

Robbins Basic Pathology 10th edition

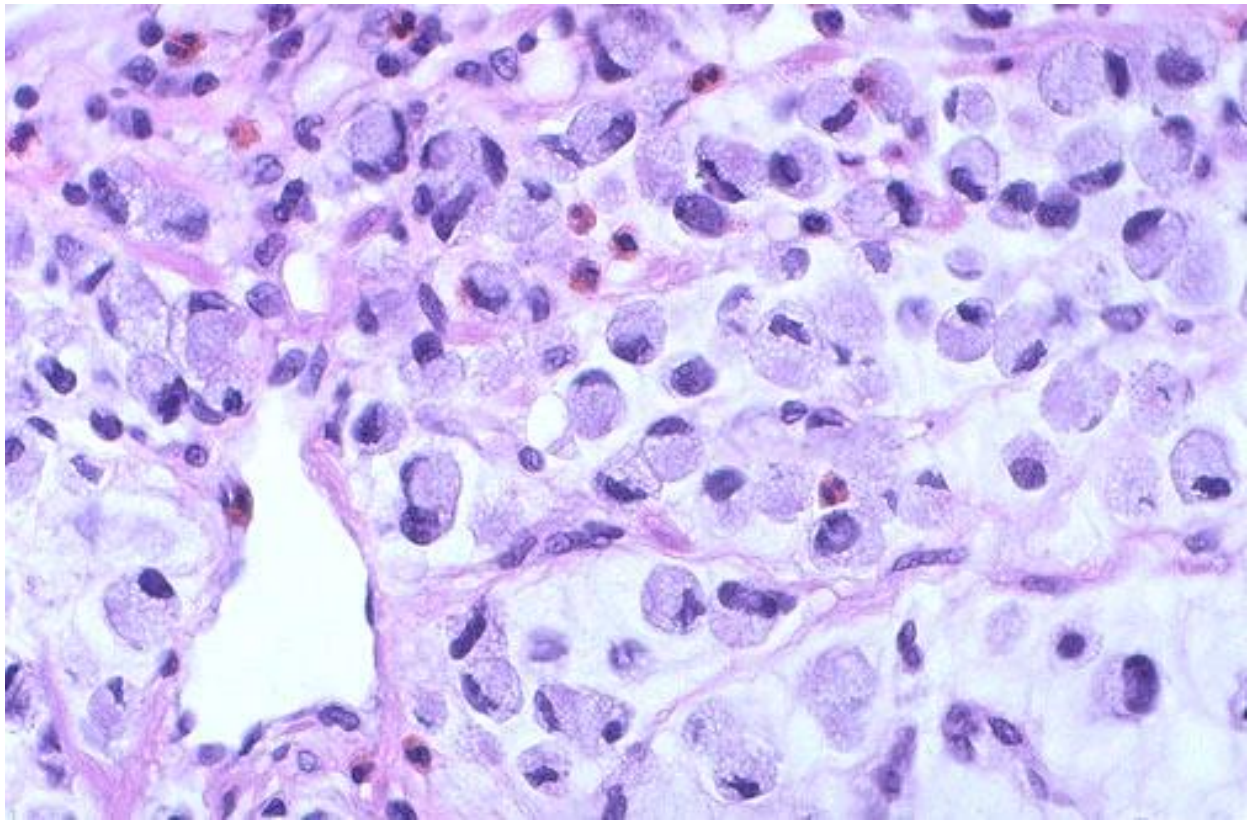

Medicine simplified

Gastric Adenocarcinoma; Lentis Plastica- Gross

The LINITIS PLASTICA is the most spectacular, and most feared, of all gastric adenocarcinomas. It grows diffusely through all layers of the stomach, greatly thickening its wall, and giving the stomach a classic leather bottle appearance. It has a horrible prognosis.

Clinical Features

- **Intestinal-type gastric cancer**
- High-risk areas
- Develops from precursor (adenoma, dysplasia)
- Mean age 55 yrs.
- M:F 2:1

- **Diffuse type gastric cancer:**
- Incidence uniform across countries.
- No precursor lesion.
- M:F 1:1
- **Younger age.**

- The drop in gastric cancer incidence applies only to the intestinal type.
- Incidences of intestinal and diffuse types are now similar in some regions.
- Most powerful prognostic factors: **depth of invasion & extent of nodal and distant metastasis at the time of diagnosis**
- **Most cases Dx at advanced stage.**
- 5 year survival 90% to 20% for early and advanced tumors, respectively.
- Tx: surgery, chemotherapy, targeted Tx (anti HER2)

Lymphoma

- Stomach is the most common site of extranodal lymphoma.
- 5% of all gastric malignancies.

- **Most common type : extranodal marginal zone B-cell lymphomas (*MALToma) (indolent)***
- ***Second most common lymphoma: diffuse large B cell lymphoma (aggressive)***

Neuroendocrine (Carcinoid) Tumor

- Tumors arising from neuroendocrine-differentiated gastrointestinal epithelia (e.g., G cells).
- > 40% occur in the small intestine.
- Associated with endocrine cell hyperplasia, chronic atrophic gastritis, and Zollinger- Ellison syndrome
- Slower growing than carcinomas.

Intramural or submucosal masses (small polypoid lesions)

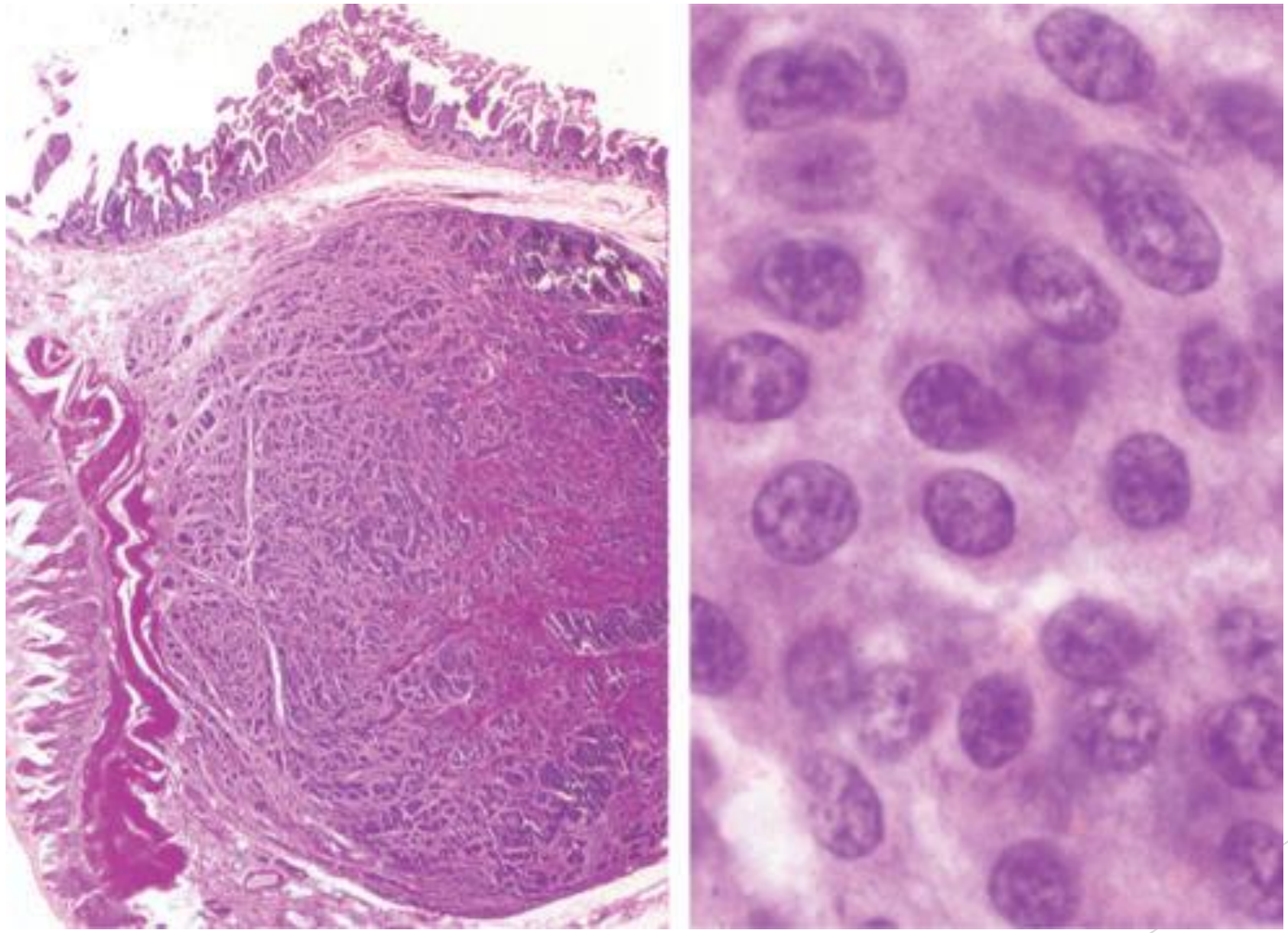

Nests , uniform cells with scant, pink granular cytoplasm and salt and pepper chromatin.

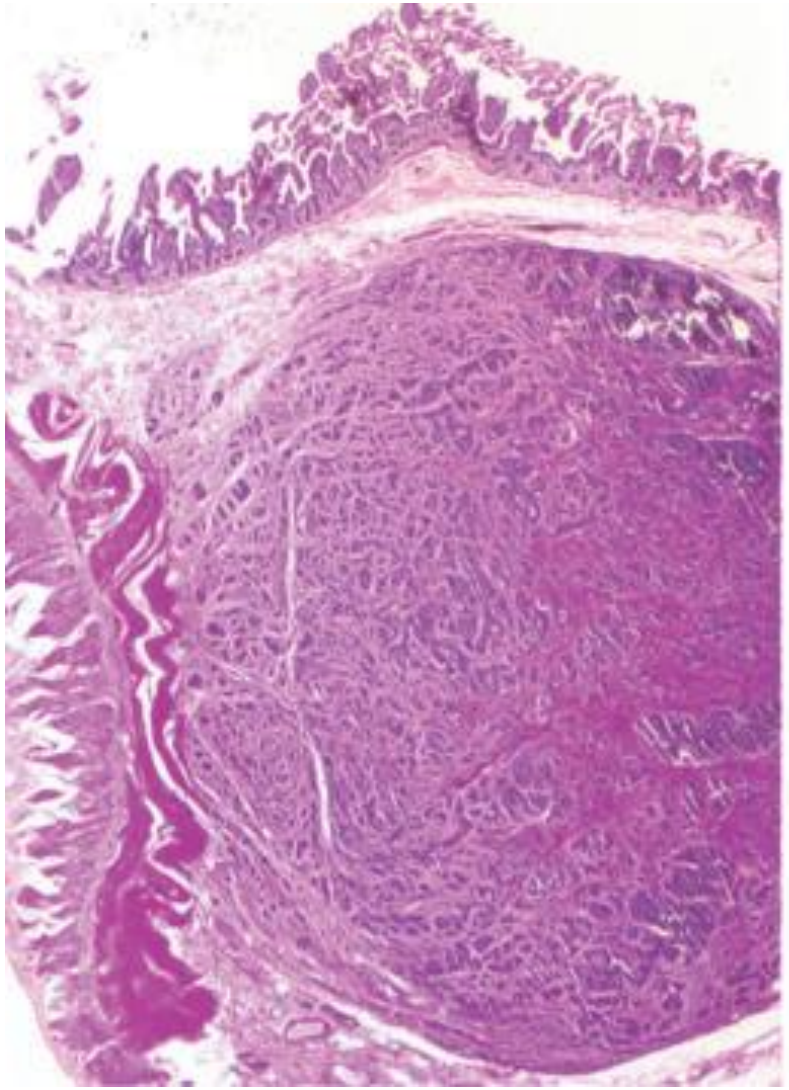

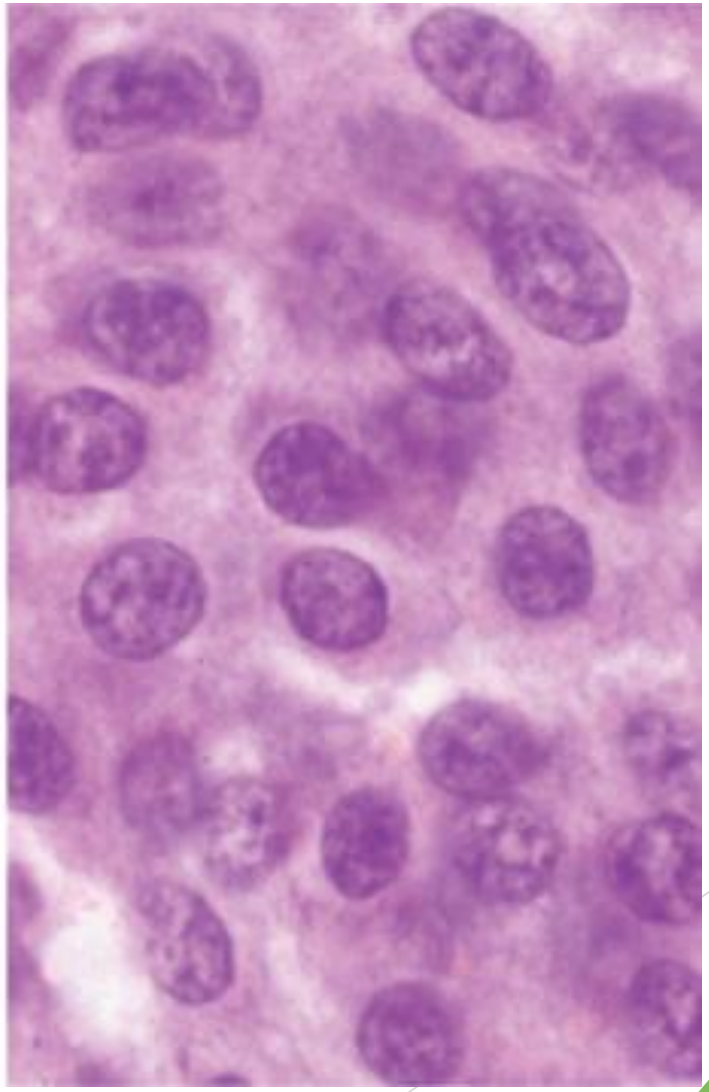

Carcinoid syndrome

- Due to vasoactive substances
- Seen in 10% of cases.
- *strongly associated with metastatic disease.*

- **Cutaneous flushing, sweating, bronchospasm, colicky abdominal pain, diarrhea, and right-sided cardiac valvular fibrosis**

Gastrointestinal Stromal Tumor (GIST)

- Most common mesenchymal tumor of the abdomen.
- > ½ of cases occur in the stomach.
- 75- 85% harbor c-KIT mutation.
- 8% PDGFRA mutation.
- Arise from the interstitial cells of Cajal