Anatomy / اول
ال
Dr. maher.

Medical Language

- Most derived from **Latin** and/ **Greek** language.
- Important for clear communication in health sciences.
- To describe the body clearly and indicate the position of its parts in relative to each other.

Objectives

Divide medical words into their basic parts.

Find the meaning of basic combining words.

Basic word parts

- **Word Root** ⇨ Origin of the word.
  eg: Gastr = Stomach
- **Suffix** ⇨ Word ending.
  - Gastr / ic ⇨ Related to.
  - Gastr / itis ⇨ Inflammation.
  - Gastr / ectomy ⇨ Removal.
  - ...../ Logy ⇨ Science.

Basic word parts ...continued

- **Prefix** ⇨ Word beginning.
  - **Epi** ⇨ Above eg: **Epi**/gastr /ic
  - **Hypo** ⇨ Below eg: **Hypo**/gastr /ic
  - **Anti** ⇨ Against eg: **Anti**/bio /tic
  - **A** ⇨ NO eg: **A**/vascular
- **Combining Vowel** ⇨ A vowel that joins one root to another or to the suffix. [Usually **O**] eg:
  - Gastr /**o**/logy
  - Gastr /**o**/intestinal
  - Gastr /**o**/ hepatic

Anatomical Position

Referral position

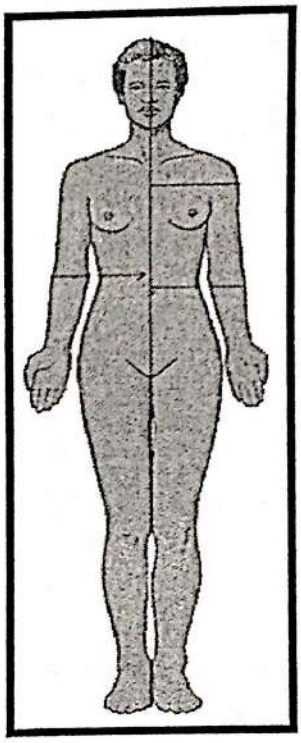

Worldwide constant method in describing a patient, assume he is in that specific position.

As if the

- Person standing erect.
- Facing forward.
- Palms turned forward.
- Feet by side.

Directional Terms

To describe the position of one body part relative to another.

Term	Meaning
Anterior	Nearer to front of body
Posterior	Nearer to the back
Superior	Nearer to the head
Inferior	Nearer to the feet
Median	Central line of the body
Medial	Nearer to the median line
Lateral	Away from median line
Proximal	Nearer to point of origin
Distal	Away from point of origin
Superficial	Nearer to body surface
Deep	Away from body surface

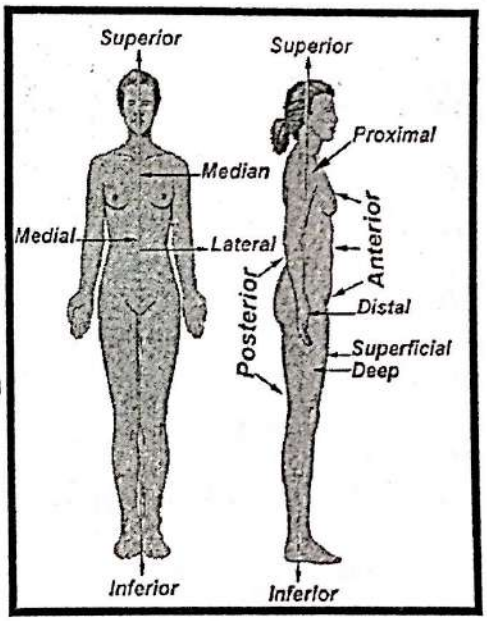

Body planes/Sections

Flat surfaces that pass / cut throughout body levels.

- **Midsagittal** → divide the body into two equal halves.
- **Sagittal** → divide body into two parts.
- **Horizontal** → divide body into upper part and lower part.
- **Coronal** → divide the body into anterior part and posterior part.

➢ **Sections** → Used in Anatomy, Pathology and Surgery.

➢ **Planes** → used in Radiology e.g.. CT and MRI.

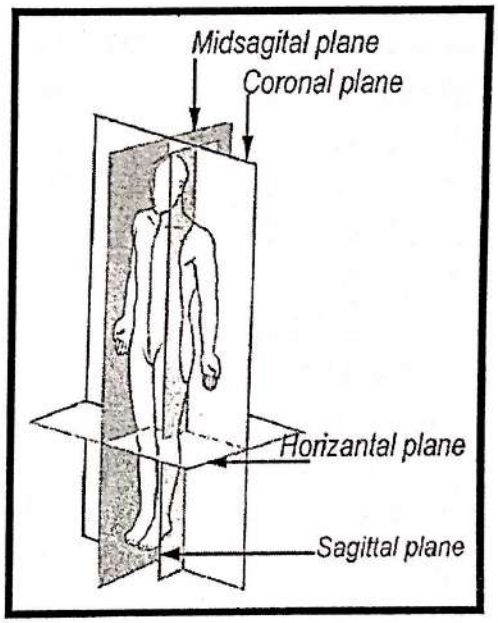

Bony Skeleton

- A calcified connective tissue that serve as **storage** for calcium and phosphorus.
- Act as **Levers** for muscles to produce movements permitted by joints.
- Contain internal soft tissue, **Bone Marrow**, where blood cells are formed.
- Form of **206** bones in adults, connected via spaces called joints.

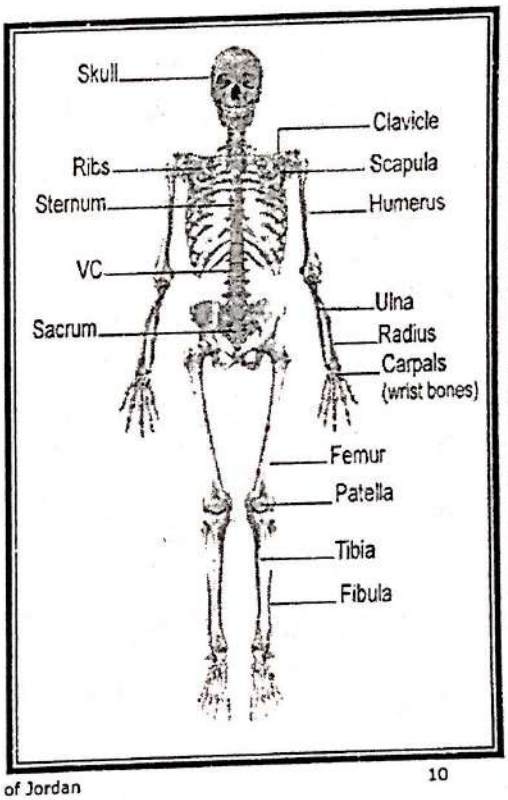

Divisions

Two divisions:

1. **Axial skeleton (80 bones).**
2. **Appendicular skeleton (126 bones).**
   - **Upper:**
     - **Shoulder girdle.**
     - **Bones of upper limb.**
   - **Lower:**
     - **Pelvic girdle.**
     - **Bones of lower limb.**

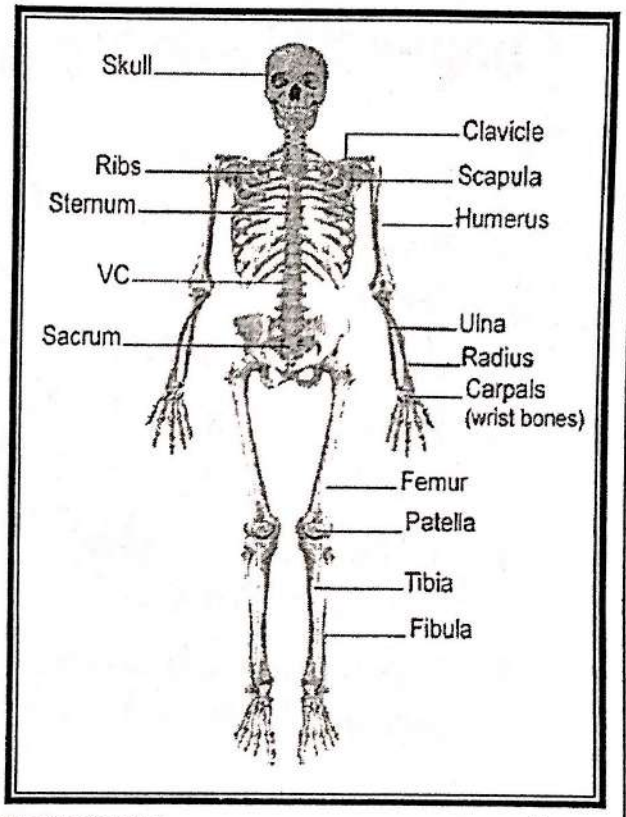

Shapes of bones

1. **Long bones.**
   e.g. Humerus
2. **Short bones.**
   e.g. Wrist bones
3. **Flat bones.**
   e.g. Scapula
4. **Irregular bones.**
   eg. Vertebra
5. **Sesamoid bones.**
   eg. Patella

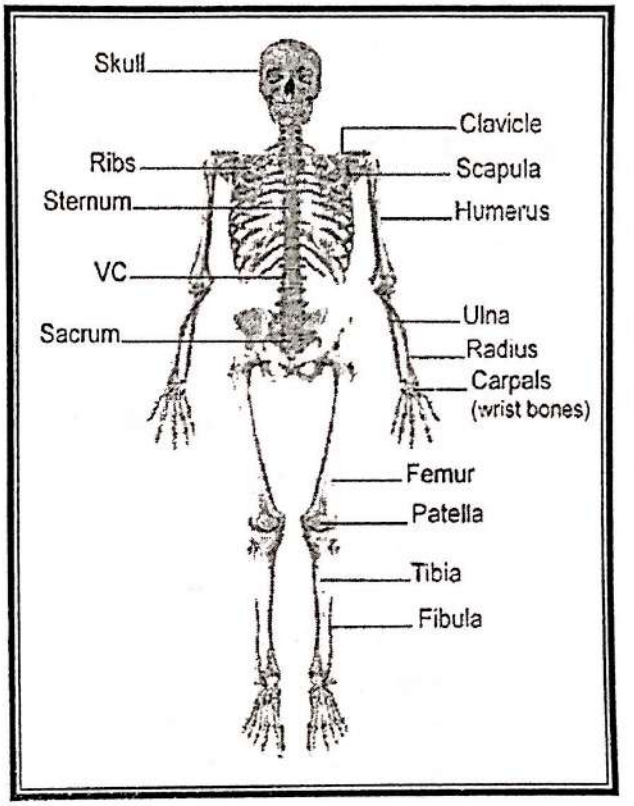

Bone Markings

Bone structural features adapted for specific functions. Are:

1. Either (bone deposition) ⇨ building new bone, resulting in raised or roughened areas. Appears in response to pull (tension) on bone surfaces by tendons, ligaments and fascia on the periosteum.
2. Or (bone resorption) ⇨ Groove on a surface of a bone caused by pressure.

1. Bone outgrowths serve as points of attachments for connective tissue.

- Tubercle درنه → Small, rounded projection.
- Tuberosity أحدوبة → Large, rounded projection.
- Facet وجيه → Smooth flat surface.
- Spine شوكه → Thornlike process.
- Process ناتئ → Projection on bone.
- Trochanter المدوّر → Large blunt projection.
- Protuberance حدبه → Bone projection.
- Crest عرف → Elongated ridge of bone.
- Line خط → long, narrow ridge of bone.
- Condyle لقمه → large, round protuberance at the end of a bone.
- Epicondyle لقيمه → prominence above condyle.
- Malleolus كعبي → Rounded process.

2. Grooves and openings, which allow the passage of soft tissues as blood vessels and nerves.

- **Foramen** ثقبه → *Opening through a bone.*
- **Fossa** حفره → *Shallow depression (trench).*
- **Fissure** شق → *Narrow slit between adjacent bones.*
- **Notch** ثلمه → *Nick (cut) at edge of a bone.*
- **Sulcus** تلم → *Groove along a bone surface.*
- **Meatus** صماخ → *Tubelike opening (passageway).*

Types of bone tissue

Classified according to relative amount of solid matrix, number and size of bone marrow cavities.

- **Compact bone**
  - Full with solid matrix.
  - Designed for weight bearing and support.
- **Spongy bone**
  - Full with bone marrow.
  - Designed for protection and blood cells formation.

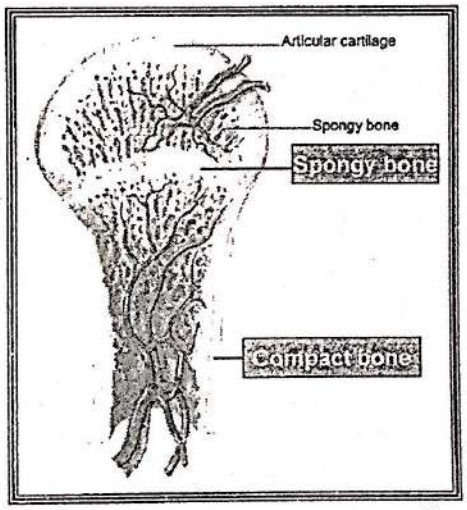

Movements of joints

1. Flexion (Fig. 1).
2. Extension (Fig. 1).
3. Adduction (Fig. 2).
4. Abduction (Fig. 2).
5. Medial rotation (Fig. 3).
6. Lateral rotation (Fig. 3).
7. Circumduction (rotation).

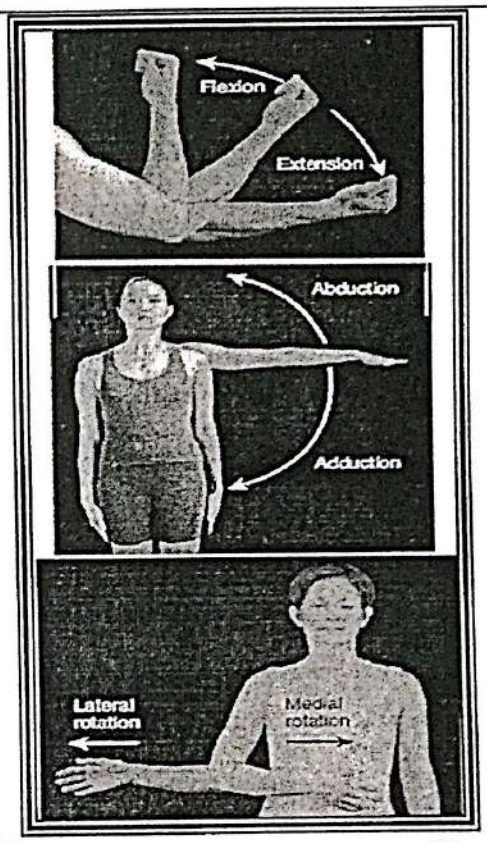

Types of Joints

Classified according to the type of connective tissue between the articulating bones.

1. **Synovial J.** Contains (Synovial **fluid**)
   e.g.. Knee joint.

2. **Cartilaginous J.** Contains (**cartilage**)
   e.g.. Intervertebral Joints.

3. **Fibrous J.** Contains (Fibrous CT)
   e.g.. Sutures between bones of the skull.

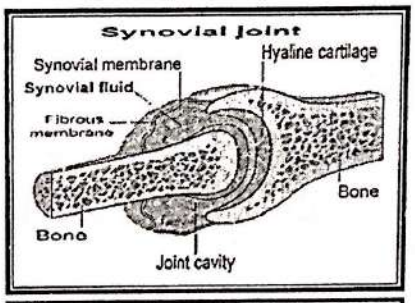

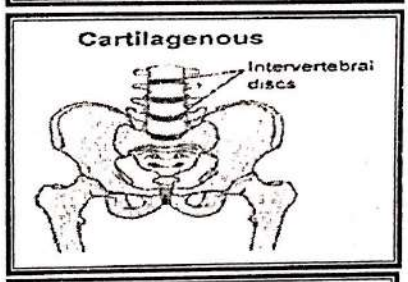

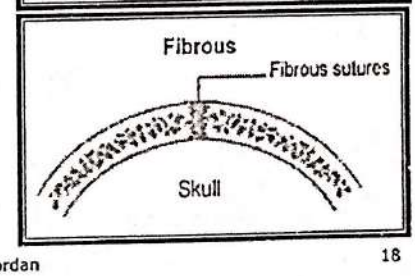

Anatomy 2
30-Jan-18

Upper Appendicular Skeleton

Components:

- **Shoulder Girdle**
  - Clavicle ⇨ Anterior
  - Scapula ⇨ Posterior
- **Bones of Upper limb**
  - Humerus
  - Radius ⇨ Lateral
  - Ulna ⇨ Medial
  - Carpal bones
  - Metacarpals
  - Phalanges

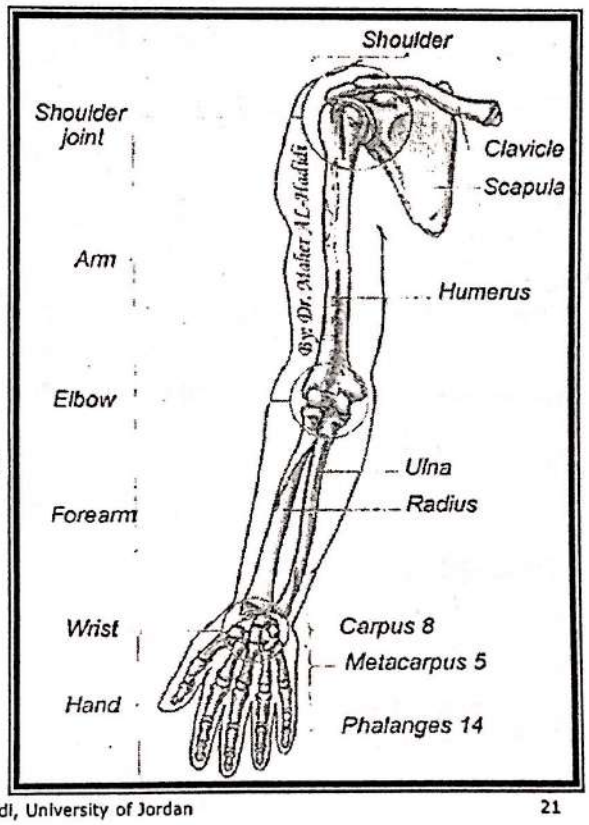

Clavicle

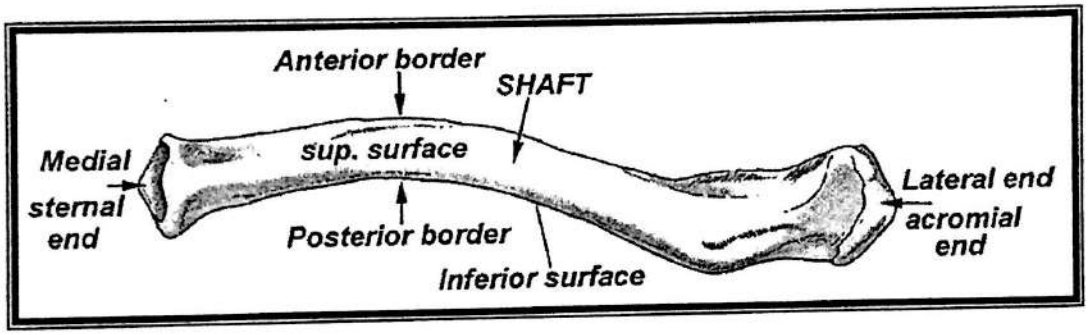

S-shaped, Subcutaneous, Flat bone
Connecting sternum medially and scapula laterally.

Parts:

- 2 ends
- 2 Surfaces
- 2 Borders

Scapula

Triangular in shape, has:

1. 3 angles.
2. 3 borders.
3. 3 processes.
   - Spine (posterior).
   - Acromion= (top of shoulder).
   - Coracoid (Raven= Crow + form). غرابي

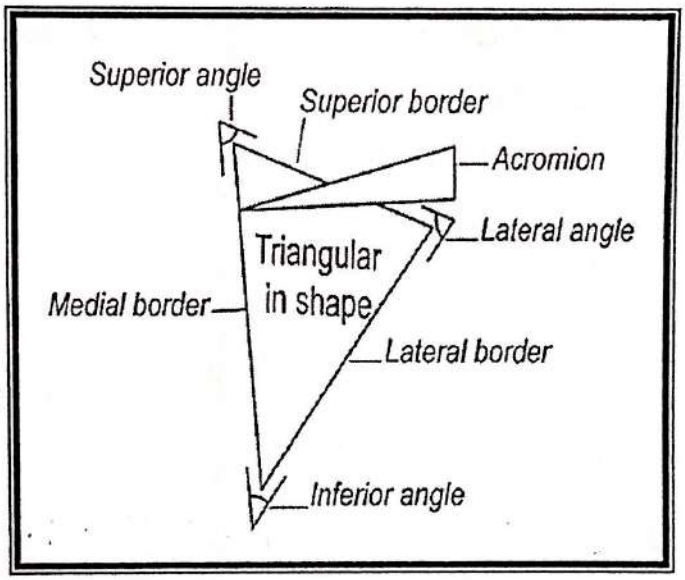

Scapula

4. 3 Surfaces.
   - Anterior.
   - Posterior

     2-parts:
     - Supraspinous fossa.
     - Infraspinous fossa.

Fossa=Shallow cavity.

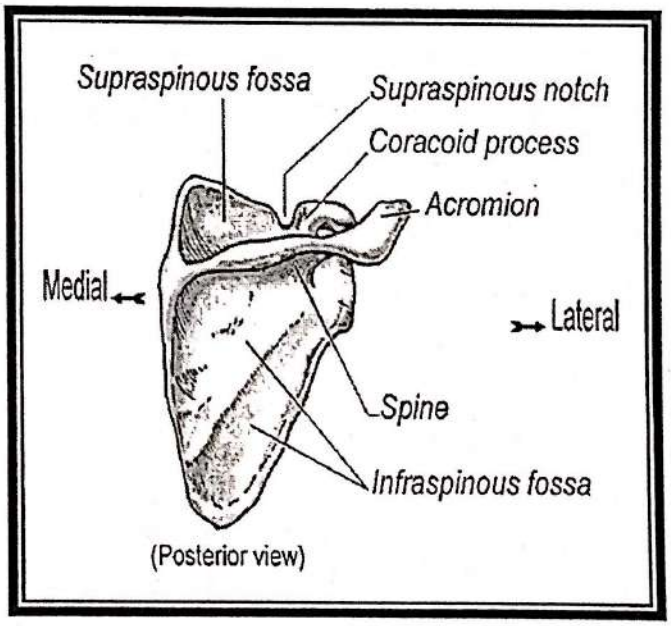

Scapula- Anterior view

- Subscapular fossa (Anterior surface).
- Glenoid fossa (Glen=Socket):
  - For articulation with head of humerus to form the shoulder joint.

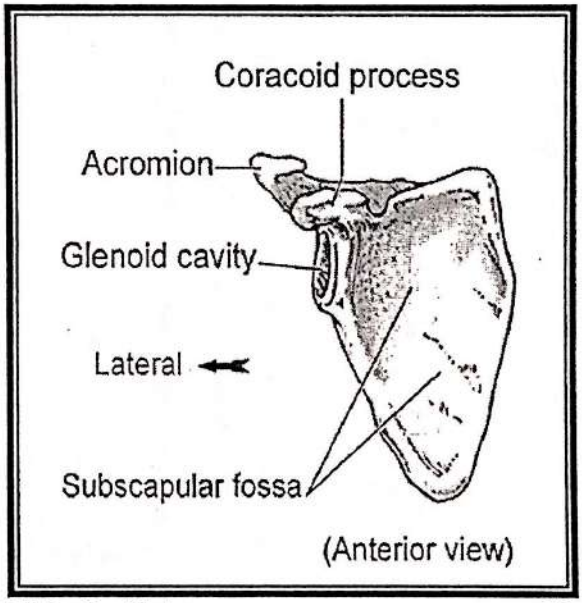

Humerus

3 Parts:

- Proximal end
- Shaft (body)
- Distal end

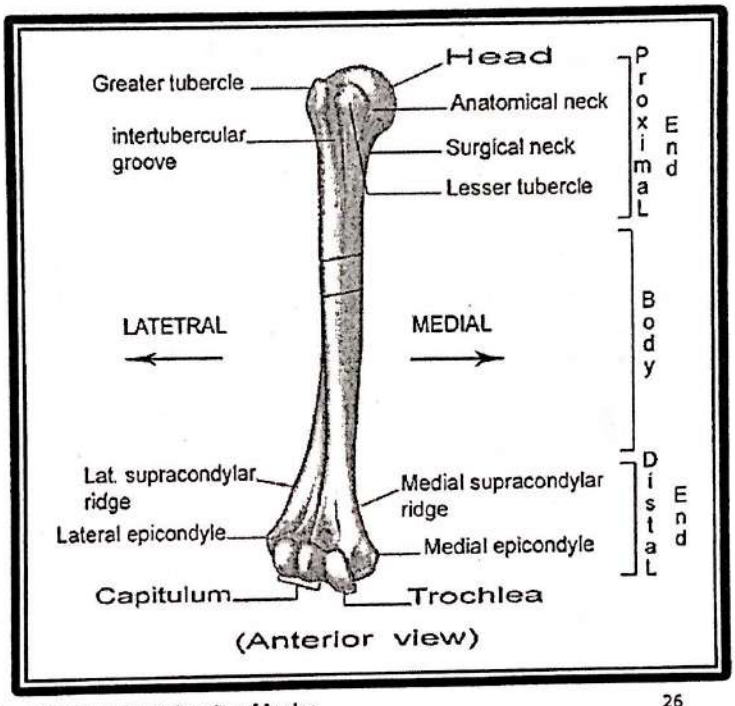

Humerus

1. Proximal end Parts:
2. Body Parts:

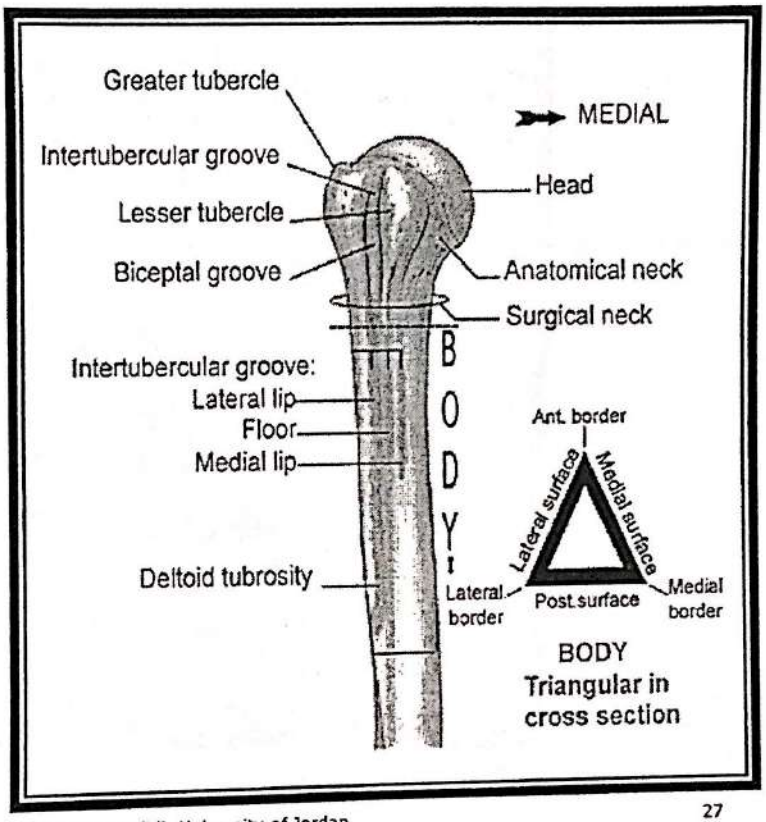

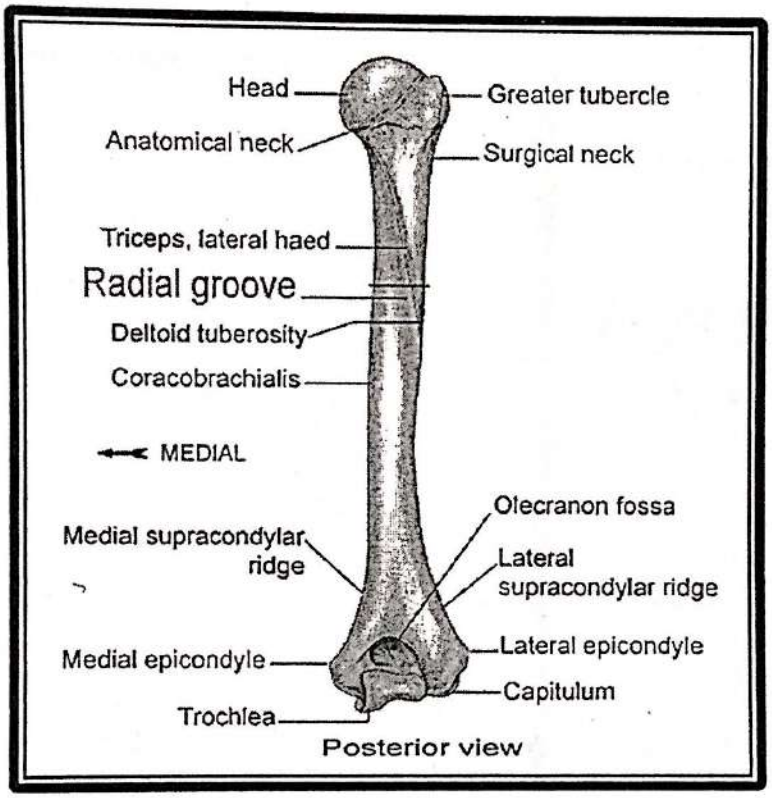
Head
Greater tubercle
Anatomical neck
Surgical neck
Triceps, lateral haed
Radial groove
Deltoid tuberosity
Coracobrachialis
MEDIAL
Olecranon fossa
Medial supracondylar ridge
Lateral supracondylar ridge
Medial epicondyle
Lateral epicondyle
Capitulum
Trochlea
Posterior view

Humerus- Distal end

- **2 Epicondyles:**
  For muscles attachment.
- **Capitulum:**
  For articulation with radius.
- **Trochlea:**
  For articulation with ulna.

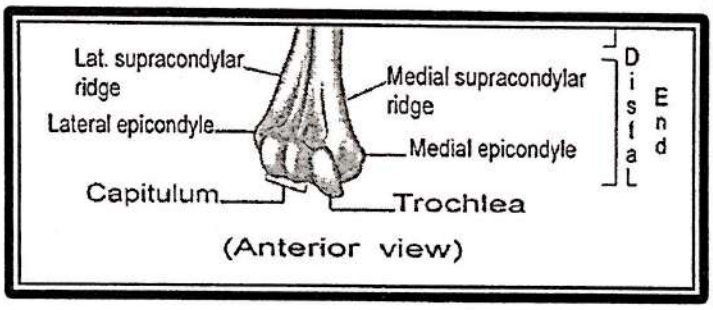

The University of Jordan
Faculty of Medicine
Department of Anatomy

Anatomy & Embryology (0502110)
Medical Class / Upper Limb
Second Semester 2017 /2018

No.	Topics	Day	Date	Practical	Week
1	Medical Terms and Bony skeleton	Sun	Jan,28	**Clavicle,Scapula and Humerus**	1
2	**Upper Limb:** Bones of UL.	Tue	Jan,30		1
3	Pectoral Region, Scapular muscles	Sun	Feb,04	**Pectoral region and Scapular muscles**	2
4	Embryology	Tue	Feb,06		2
5	Axilla, Brachial plexus	Sun	Feb,11	**Axilla and Brachial plexus**	3
6	Embryology	Tue	Feb,13		3
7	Compartments of Upper arm	Sun	Feb,18	**Compartments of upper arm**	4
8	Embryology	Tue	Feb,20		4
9	Anterior Compartment of forearm	Sun	Feb,25	**Ant. Compt. of Forearm**	5
10	Embryology	Tue	Feb,27		5
11	Posterior Compartment of Forearm	Sun	Mar,04	**Post. Compt. of Forearm**	6
12	Embryology	Tue	Mar,06		6
***	Mid-term Examination Mar 3 - 29				
13	Hand	Sun	Mar, 11	**Hand**	7
14	Embryology	Tue	Mar, 13		7

Recommended books:

1. Clinical Anatomy by Regions. *By: Richard Snell*
3. Langman's Medical Embryology. *By: T. W. Sadler*