Histology

faculty of medicine - JU2017

◉ Sheet ○ Slides

Number

10

Done by:

Dr. Heba Kalbouneh

Corrected by:

Ragad Alhawi

Doctor

Heba Kalbouneh

(Bone)

- Special connective tissue.
- **Cartilages + Bones** = Skeleton.
  - ✓ **Osseous** = refers to bone.

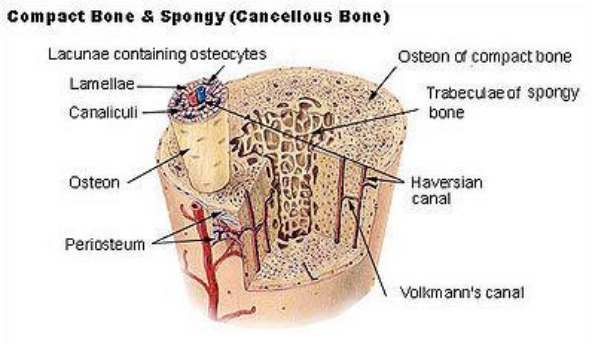

➢ Functions of the bone:

1. **Support:** It forms the framework of our body; most of the skeleton in our body is bones.
2. **Protection:**
   -The cranial bones provide protection for the brain.
   -Thoracic cage provides protection for the lungs and the heart.
   -Vertebral canal provides protection for the spinal cord.
   -The pelvic cavity provides protection for the urinary bladder and the reproductive organs.
3. **Movement:** bones don't move, but muscles which are inserted into the bones transform their action into the bodily movement.
4. **Mineral homeostasis:** bones act as reservoir for minerals that are important to our body such as calcium and phosphate. For example, a certain concentration of calcium inside the blood should be maintained, so when the body needs calcium, calcium will be mobilized from the bone to increase calcium blood level.
   - On the other hand, if you increase your intake of calcium, more deposition of calcium inside the bone occurs.
   - 99% of the calcium in our body is reserved in the bone. It is just like a storage site for calcium.

- ✓ **If we need calcium,** **mobilization** of the calcium from the bone will take place.
- ✓ **If we have extra calcium,** **deposition** of the calcium inside the bone will take place.

-Bone is a special type of connective tissue**, it is composed of:**

A. Cells	B. ECM
Osteoblasts & osteocytes 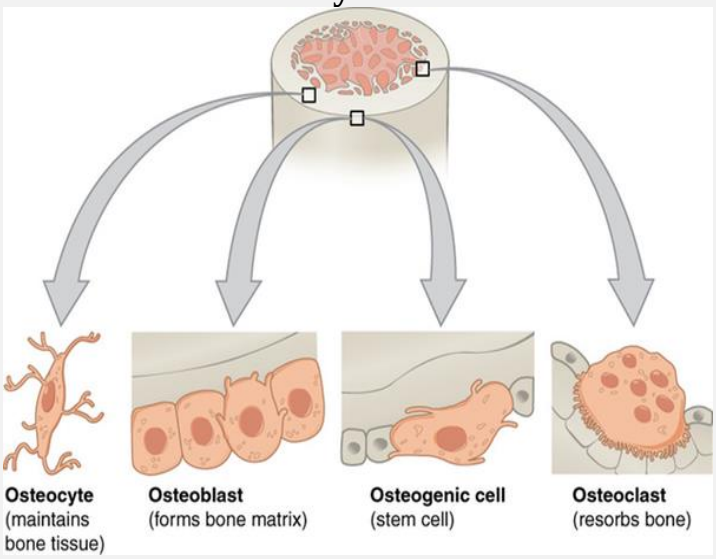	**- Fibers:** Mainly collagen type 1. This is why the bone is strong. **- Ground substance:** little amount of proteoglycans and glycoproteins. - Two thirds of the ECM of bone **is inorganic material (minerals).** This is why the bone is hard, because the ECM is highly mineralized.

These minerals are deposited inside ECM of the bone and form crystals called **Hydroxyapatite Crystals.** Main minerals are calcium and phosphate, other minor minerals are magnesium and potassium.

5. **Hematopoiesis:** the process of production of the formed elements of the blood (formation of red, white blood cells and platelets).
   -Occurs inside the red bone marrow.
   - At birth, most of our bones contain in their cavities red bone marrow. With aging this red bone marrow is gradually replaced by the yellow bone marrow. The red bone marrow remains only in the epiphysis of the long bones and flat bones such as the sternum for the production of the blood cells.

6. **Storage of adipose tissue:** yellow bone marrow.
   -Yellow bone marrow inside the cavities is adipose tissue.
   -Storage of lipids inside the bone as a yellow bone marrow.

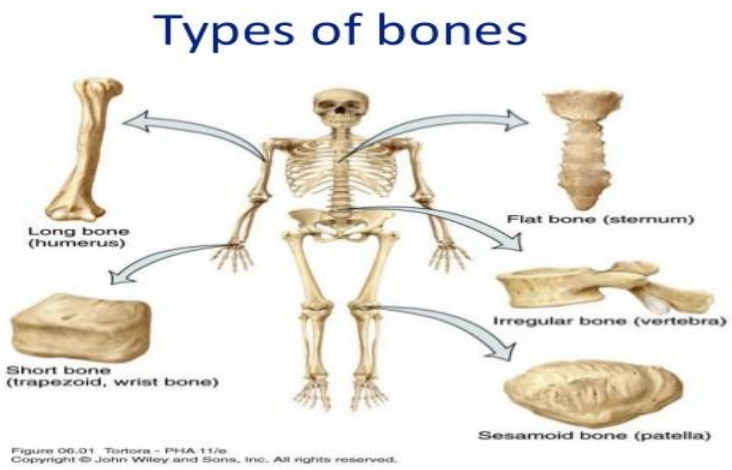

➢ Types of bones:

- **Anatomically: according to their shape:**

1. **Long bone:** composed of shaft or body of the bone (Diaphysis), proximal and distal ends (Epiphysis). For example phalanges are long bones because they are composed of proximal end, distal end and a shaft.
2. **Short bones:** carpal and tarsal bones
3. **Flat bones:** bones of the skull
4. **Irregular:** vertebrae
5. **Sesamoid:** located within tendons such as patella which is located within the quadriceps tendon.

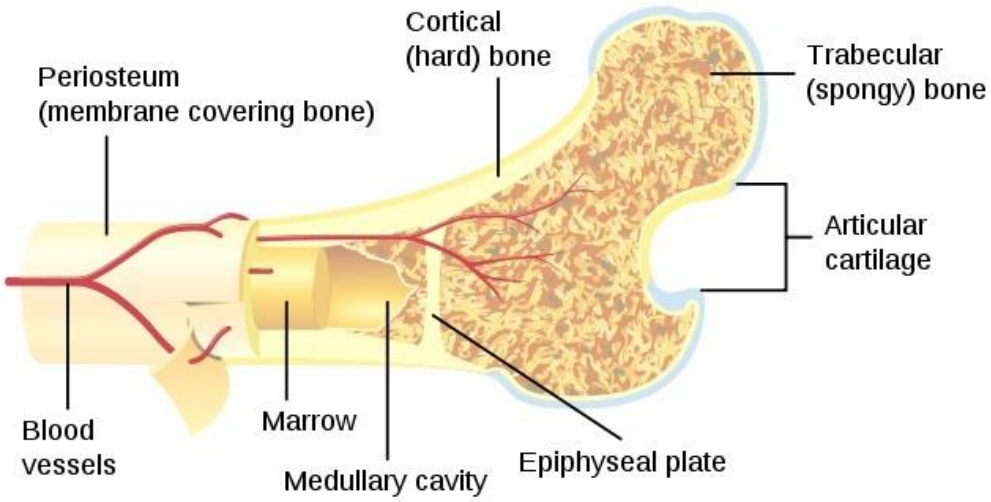

- **Macroscopically:** if we have a longitudinal section through the long bone, there are 2 different types of bones:

1. **Dense bone/Compact bone/Cortical bone:**
   - It is compacted, has no spaces and looks dense.

- Cortical refers to cortex which means shell.

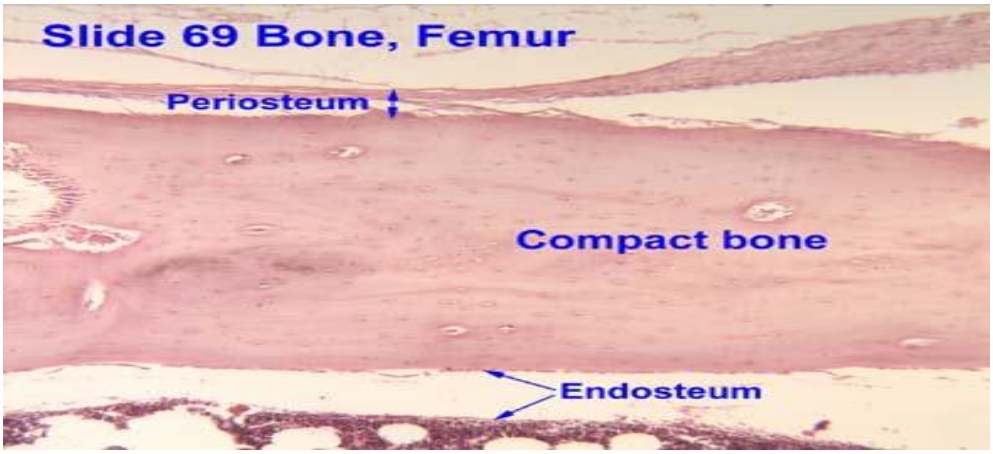

2. Spongy bone/Cancellous bone/ trabecular bone

-It has many spaces/holes that are filled with red bone marrow, so they are called marrow cavities.

- It looks like a sponge but it is not soft.

-It is composed of irregularly shaped bony structures or bony spicules, called trabeculae (called also trabecular bone)

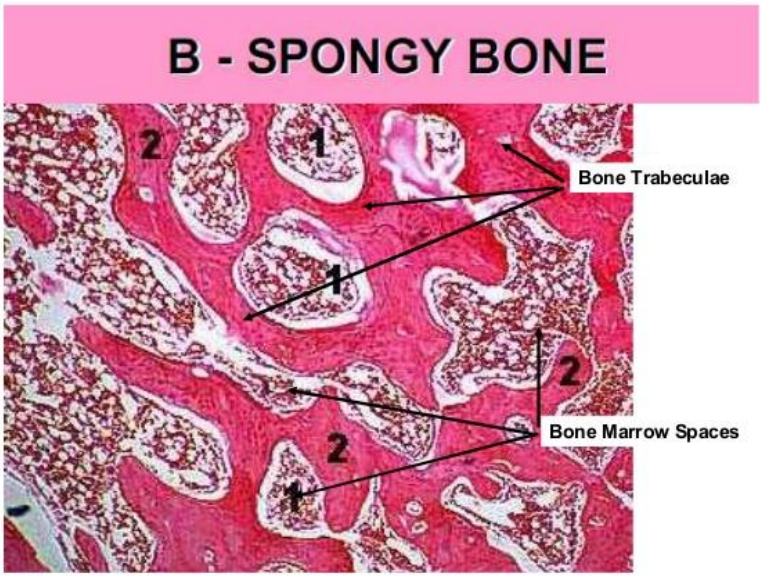

✓ **Remember** always and always: the spongy bone is covered by a layer of compact bone.

✓ **What is the difference in appearance between the compact and spongy bone?**

- The first one is compacted and the other has many spaces or pores, so the spongy bone is more lightly weighted.

✓ **Why our bones have cancellous bone?**

-Cancellous bone is not as strong as the compact bone and it is lightly weighted. Imagine if our bones are composed of only compact bones, then we would be so heavy and movement would be so difficult. The spaces inside the cancellous bones are cites for bone marrow as well

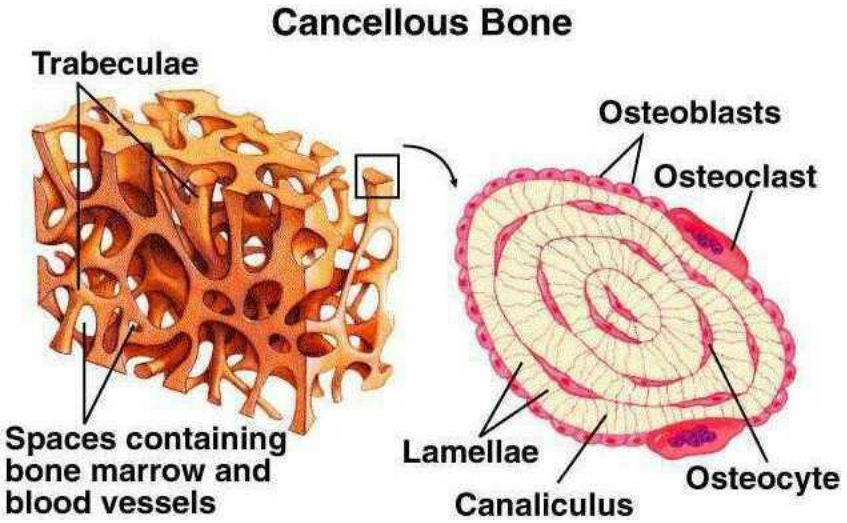

➢ The structure of the long bone:

- **Notice inside the diaphysis of the long bone:** there is a tube-like canal called **medullary canal or cavity** (at birth it contains red bone marrow). Within the spaces of the cancellous bone, there are cavities that are called **medullary cavities** that are filled with red bone marrow.
- With aging this red bone marrow will be replaced by a yellow bone marrow except in the epiphysis, some red bone marrow sites remain for the production of blood.
- **Epiphyses (proximal and distal ends) are composed** of spongy bone covered by a layer of compact bone (cortical bone), whereas diaphysis is composed of compact bone. However, a thin layer of spongy bone lines the medullary canal. Blue area: hyaline cartilage or articular cartilage. The articular cartilage has no surrounding perichondrium and it gets its nutrition from the synovial fluid inside the joint cavity.

Long Bone Anatomy (Cont.)

- **Medullary canal** – Canal in the center of the bone
  Adults – Fat storage (yellow marrow)
  Infants – Filled with red marrow (makes blood cells)
- **Red Marrow** – Responsible for hematopoiesis
  Adults – Found in cavities of spongy bone
  Infants – Found in medullary canal

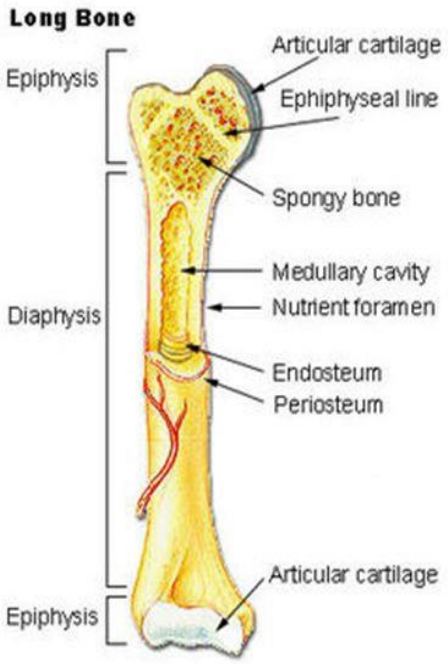

- **Notice:**

-Diaphysis: constricted portion of the body of the long bone.
-Epiphysis: proximal and distal ends.
-Epiphyseal line: The line between the epiphysis and diaphysis, it is closed, it is completely composed of bone, and it is the place where the growth plate was. It was composed of hyaline cartilage.
-Metaphysis: it is an area between the growth plate/epiphyseal line and the diaphysis.

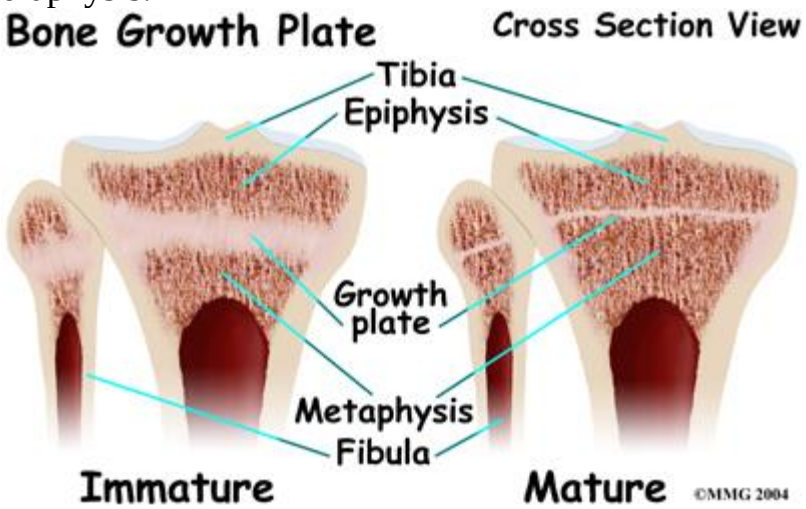

✓ **What is the difference between epiphyseal line and metaphysis?**

-The epiphyseal line is a part of metaphysis; the most proximal part or superior edge of the metaphysis if we are talking about the proximal end.

-Metaphysis is the zone of transformation between the diaphysis (constricted portion) and epiphysis (rounded in shape).

-Once the diaphysis (constricted portion) starts to flare out, the bone inside becomes spongy and the medullary canal ends; this area is called metaphysis.

Again: The diaphysis is mostly compact bone while proximal and distal ends are composed mostly of spongy bone. The epiphysis is mainly composed of cancellous bone and it is covered by a layer of cortical bone, same concept with diaphysis which is mainly composed of cortical bone and the medullary canal is lined by a thin layer of spongy bone.

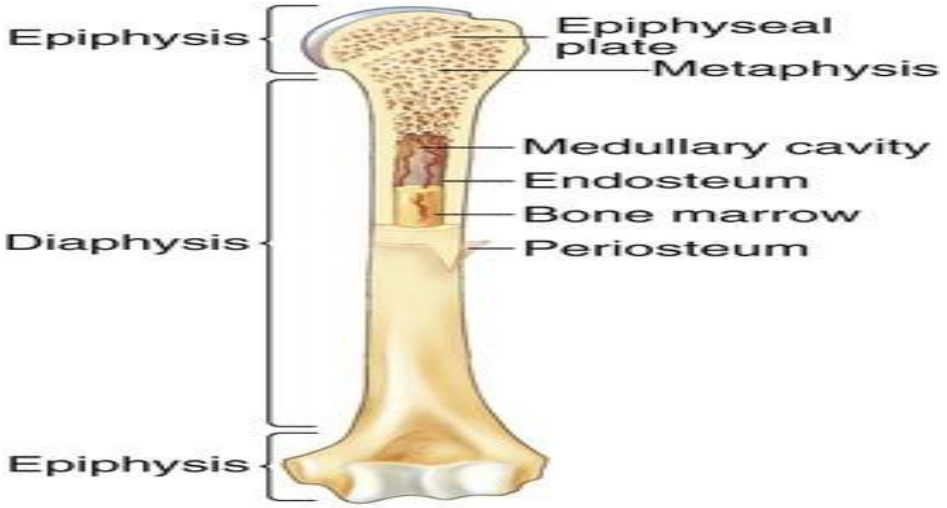

Growth plate is hyaline cartilage and is responsible for the growth of bone in length, which means whenever we still have cartilage, we can grow in height but once it is completely replaced with bone (growth plate is closed), the growth stops and it is called epiphyseal line. For example, a 30-year-old man has in his long bone epiphyseal **line** but not epiphyseal **plate**.

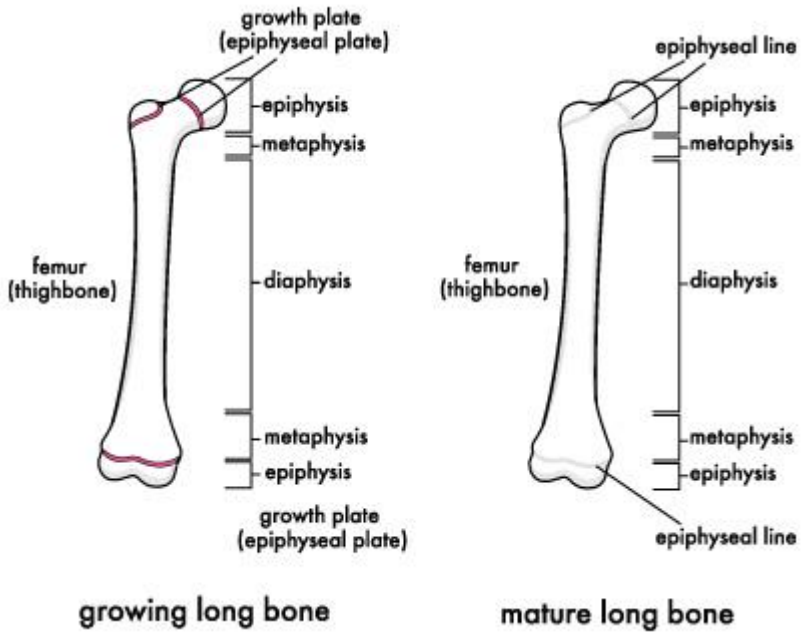

Additional information :

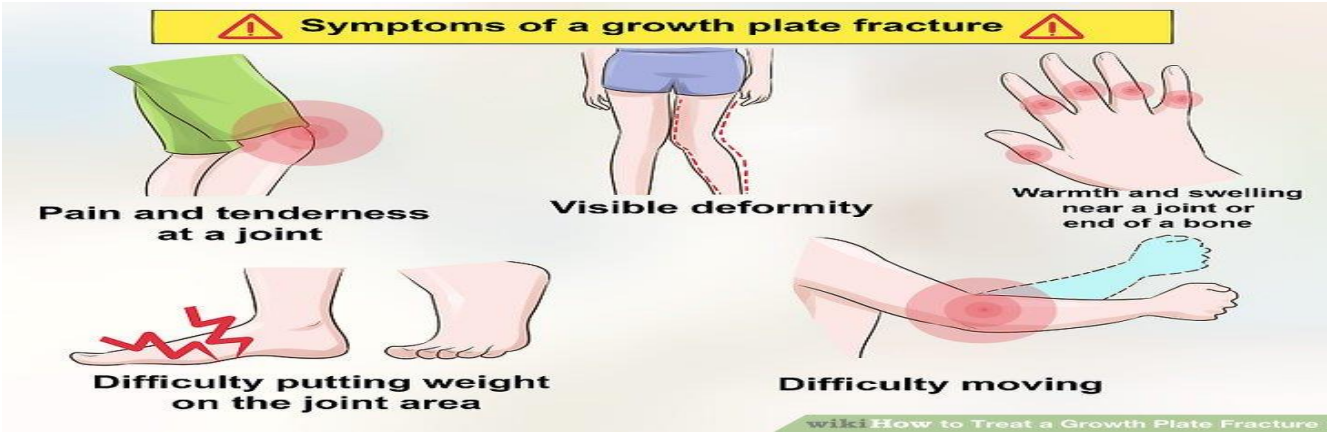

Periosteum: A double-layered membrane that covers the outer surface of bone (same as perichondrium), it is irregular dense connective tissue surrounding the bone .

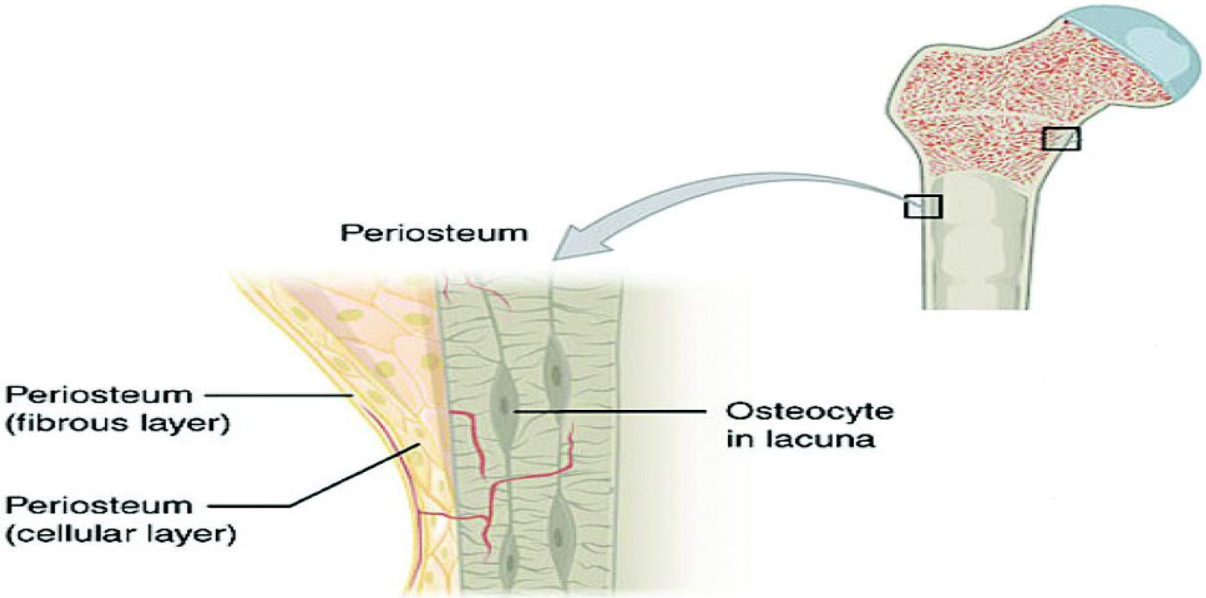

- **the outer layer is fibrous (contains collagen type I)**
- **the inner layer is a cellular layer, contains osteoprogenitor (osteogenic) cells which are able to differentiate into osteoblasts (similar to the structure of perichondrium)**

The microscopic structure of the compact bone:

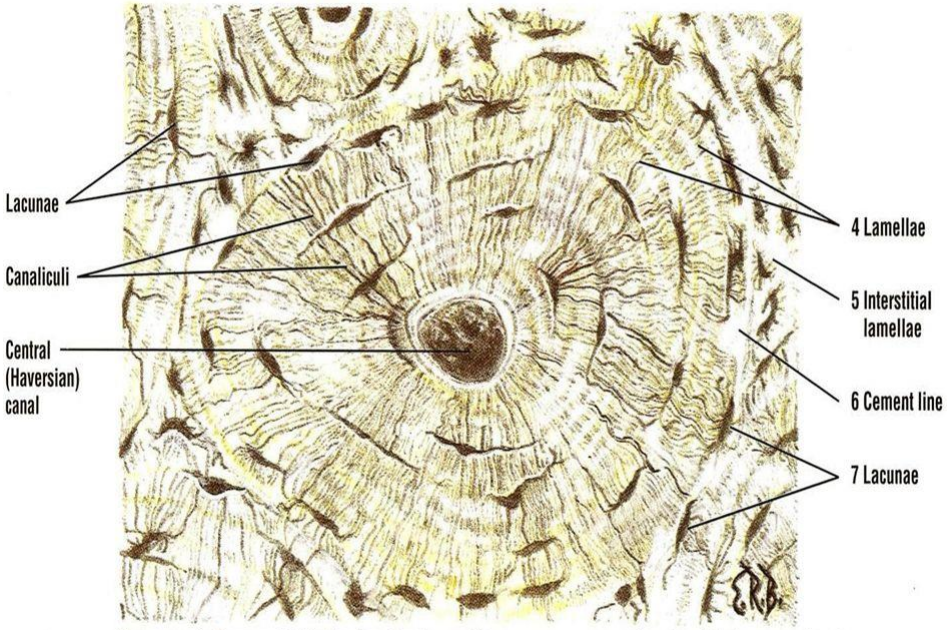

Compact Bone, Dried: An Osteon (transverse section). High magnification.

✓ No spaces (except for the presence of tiny canals)

✓ External cover (Periosteum which is composed of outer fibrous layer and inner cellular layer)

✓consists of structural units called **osteons or haversian systems**, each unit is a tall column of bone. It looks like tree trunk

✓ the long axis of the osteon is parallel to the long axis of the long bone.

Now the Osteon is:

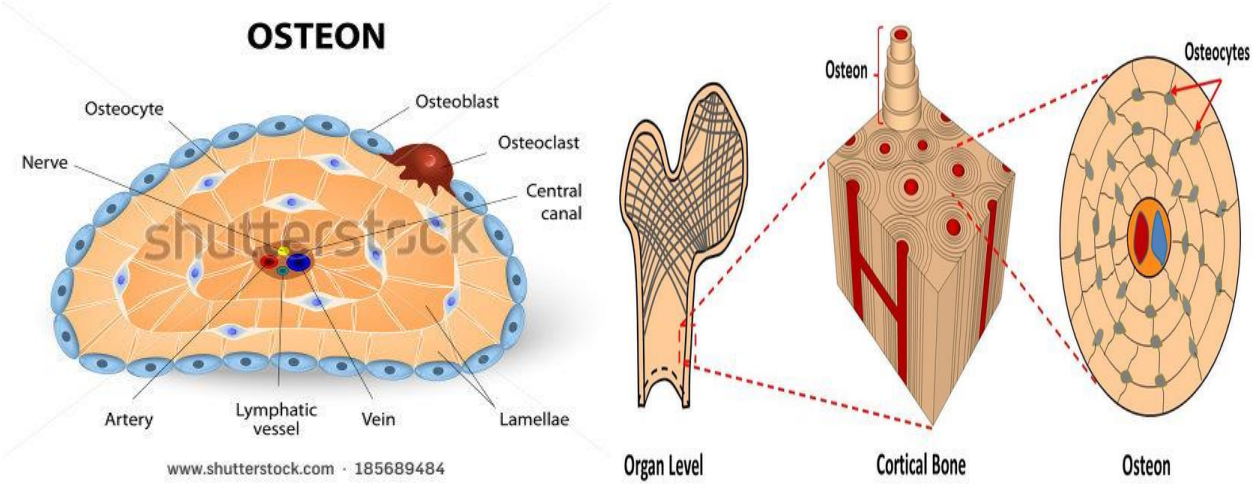

composed of concentric (متحدة المركز) rings of bone tissue surrounding a central canal called **Haversian canal** which contains blood vessels, nerves and lymphatics. These concentric rings are called lamellae. The bone is highly vascular and highly innervated, that's why bone fractures are very painful

the bone tissue is composed of cells and ECM

osteocytes are located **between** these lamellae.

ECM (which is actually the lamella).

▪ ECM is composed of:

1. 33% organic material, mainly collagen type I which is responsible for the bone's strength, glycoproteins and proteoglycans.

2. 67% inorganic material, minerals; mainly Calcium and phosphate, and they are responsible for the hardness of bone.

And that means if you exclude the minerals from the bone you would end up with a soft structure, and if you exclude collagen the bone would be brittle

Each ring is called lamella (صفيحة) (the plural is lamellae), each lamella is composed of bone ECM and osteocytes in between these lamellae.

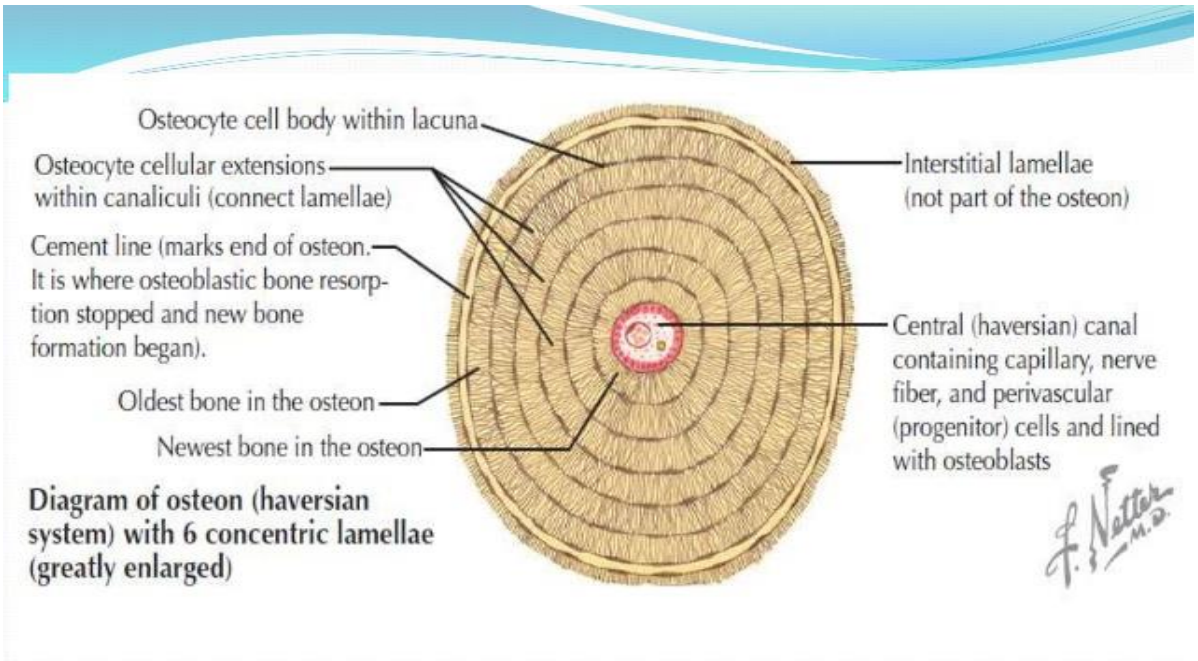

cement line:

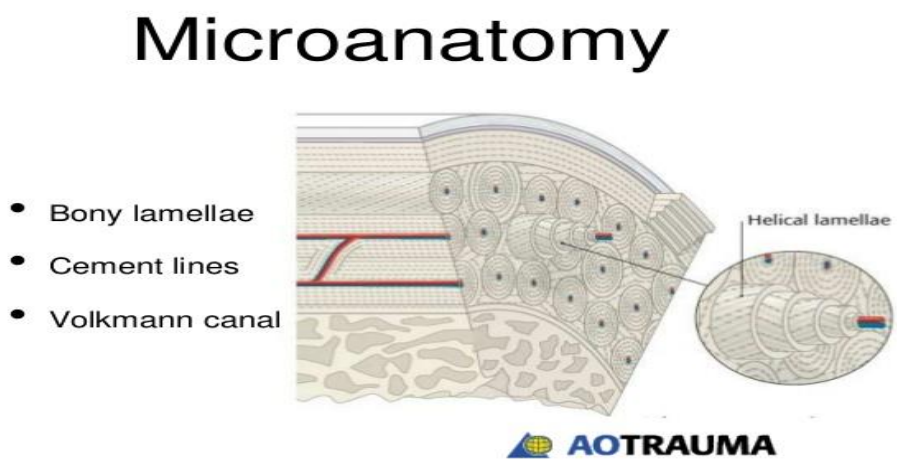

- **is the outermost layer of an osteon.**
- **can be demarcated from the nearby structures**
- **It is rich in proteoglycans**
- **It gives the osteon its distinct boundary**
- **It stains differently than other lamellae.**

Why we can demarcate each lamella from the adjacent one?

- Simply because of different orientations of collagen type I between lamellae.

Refer to the slides : notice collagen fibers in single lamella run helically and parallel to each other. In the adjacent lamella the fibers run also parallel to each other but at a perpendicular angle to the adjacent lamella, so that's why we can outline each lamella

Figure 6-6b The Structure of Compact Bone

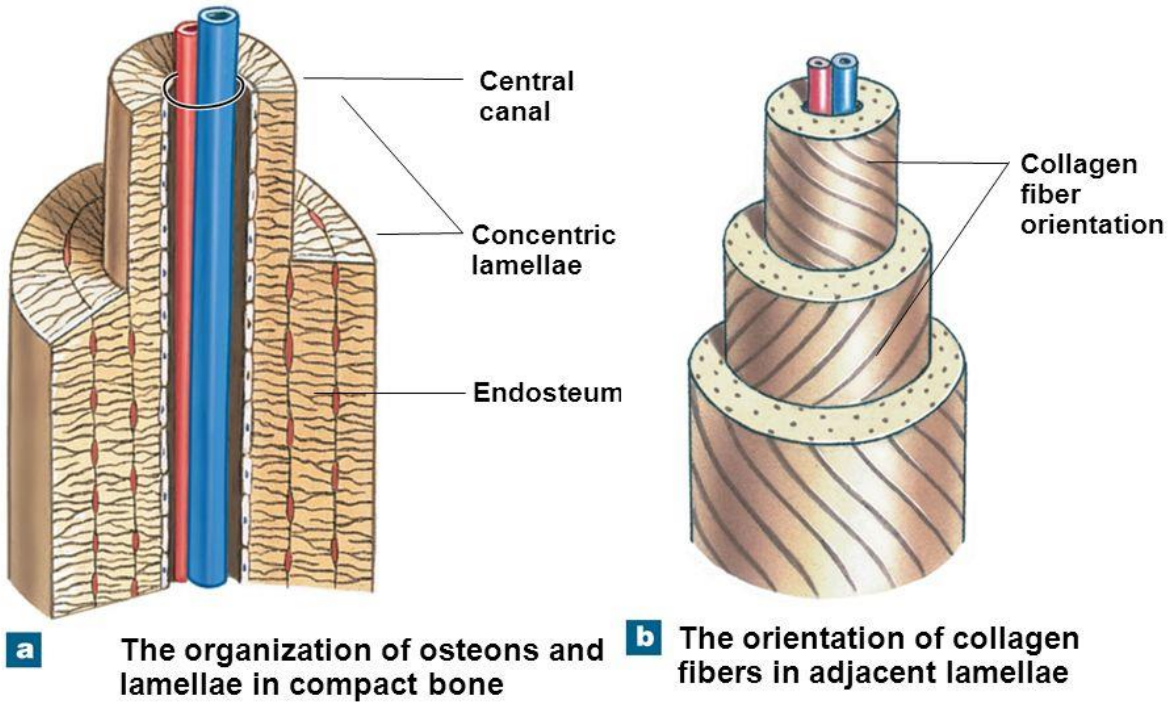

p. 186

This arrangement is very important for bone strength. How?

- if you arrange Lego pieces in rows above and parallel to each other to build a wall, this wall can be easily broken if a force is applied, but if you arrange the pieces in rows perpendicular to each other, then you get a stronger wall.

Types of lamellae:

1) Concentric lamellae: Circles within circles around haversian canals (osteons)

2) Interstitial lamellae : The old bone tissue that appear between new well-organized osteons , so it represents the old osteon system (this is an indication for continuous process of bone resorption and bone deposition, the word "old" here means partially resorbed)

3) Outer circumferential (محيطية) lamellae: Located exactly under the Periosteum and surround the whole circumference of the bone.

4) Inner circumferential lamellae: surround the medullary canal

Volkmann's canal: A transverse canal that contains blood vessels and nerve supply communicating with Haversian canals of osteons and the blood vessels of periosteum and endosteum

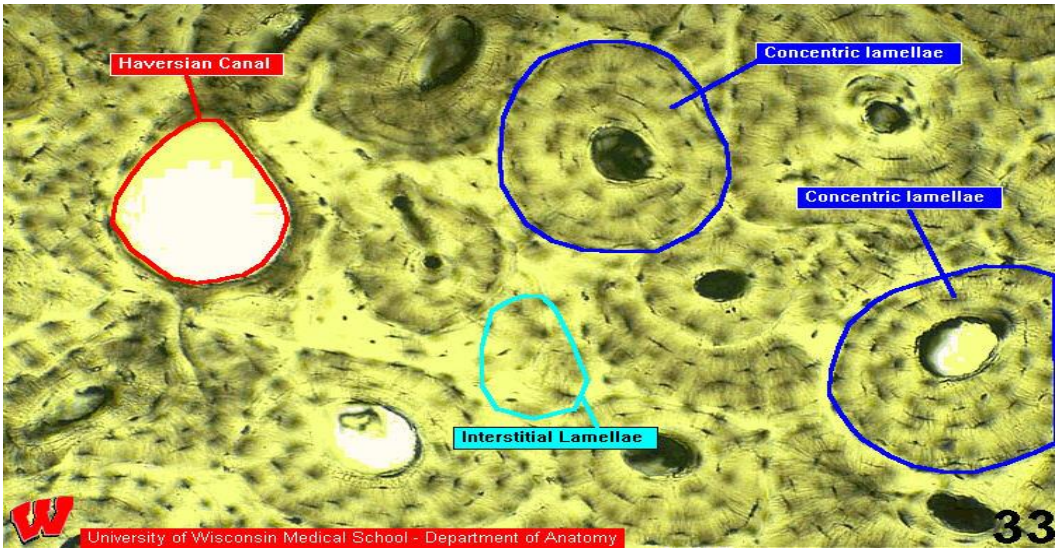

Osteocyte :

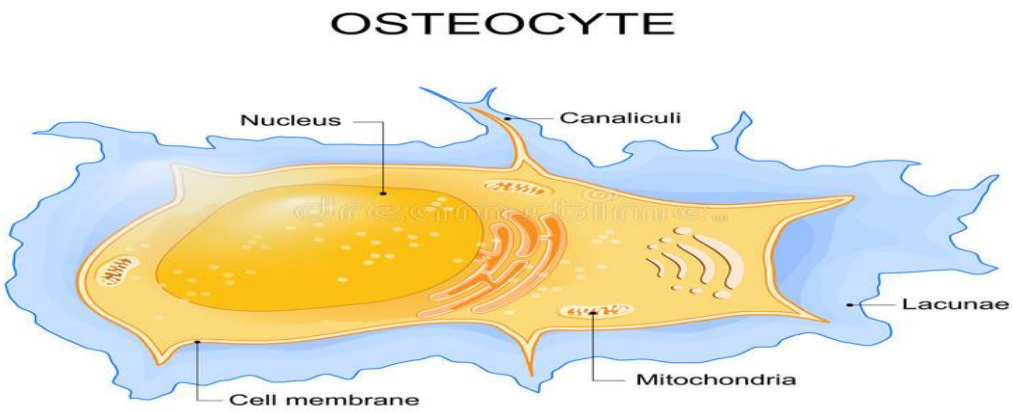

A cell that has many branches (processes) that pass through the bone tissue in small tiny canals created within bone ECM , those canals are called canaliculi (plural , and the singular is canaliculus).

Why do they have processes??

- To allow communication between Osteocytes and blood vessels of central canals, they are used for exchange of nutrients and waste products. The processes connect by gap junctions

Why canaliculi ?

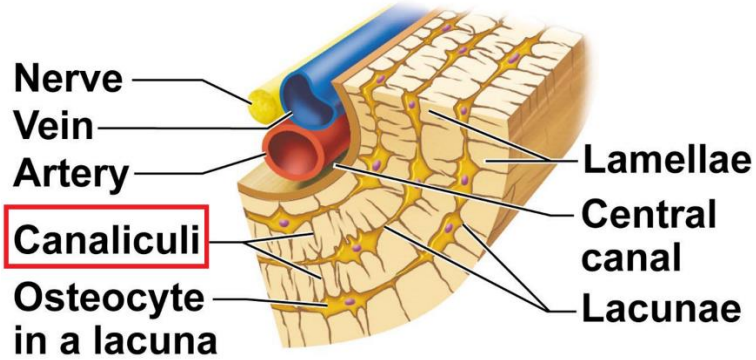

- Bone is a hard tissue so wastes and nutrients can't diffuse and can't reach osteocytes unless there are such canals.

Structure of Spongy bone:

- composed of trabeculae (plural, singular is trabeculum : Piece of bone) and spaces between them filled with bone marrow.

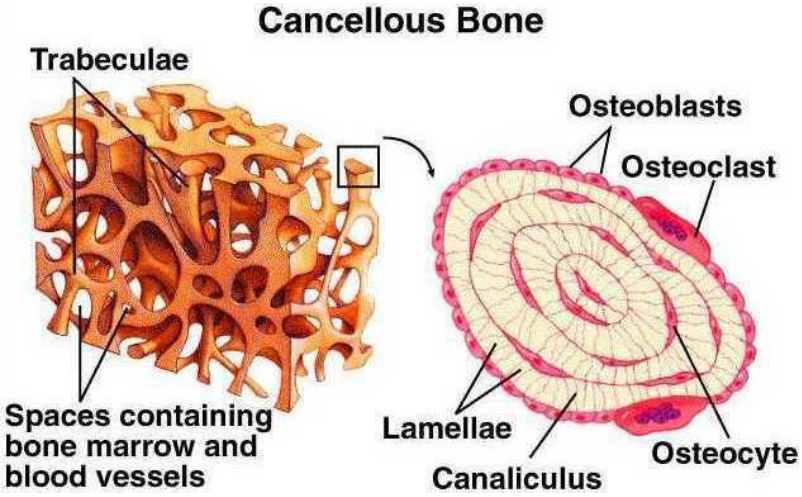

It has lamellae that run parallel to each other rather than forming concentric rings around a central canal, so there is no central canal in the middle (no osteons)

Does it contain osteocytes?

-YES

Do these osteocytes have canaliculi?

-YES

❗ Is spongy bone composed of osteons?

-NO

◆Lamellae in spongy bone is composed of ECM of bone (same as cortical bone; organic and inorganic)

❗ Where can you find the spongy bone?

In the epiphysis, and in flat bone (which is composed of spongy bone sandwiched between 2 layers of cortical bone)

✸ remember: Spongy bone is never ever exposed, it is always covered by a layer of compact bone

⬍ Diploë (pronounced dip-lo-we) is anatomical definition for area of spongy bone between the two parts of cortical bone.

Endosteum:

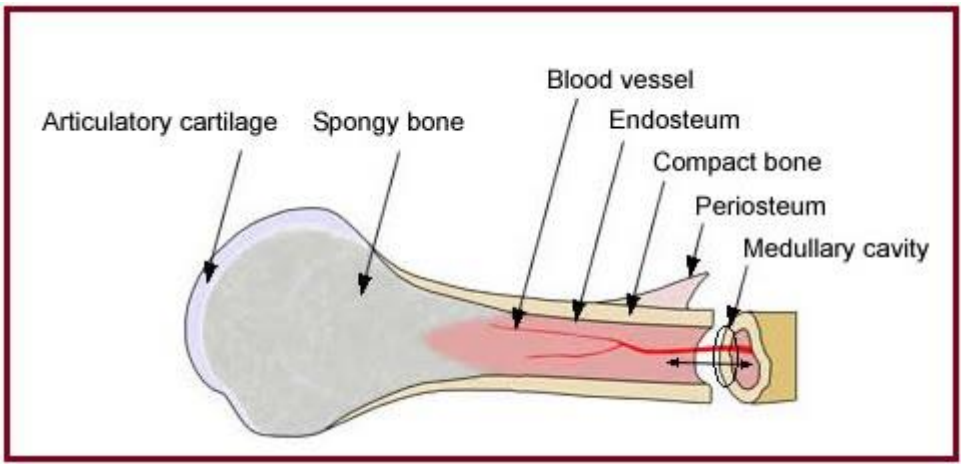

● is an inner-lining membrane

● It lines all cavities of the bone

Sharpey's fibers : Collagen I fibers anchoring Periosteum (specifically its outer fibrous layer) to the bone tissue , so that the periosteum is anchored to the bone tissue, the sharpey's fibers emerge from outer layer of Periosteum then merge with collagen type I of the bone matrix.

Figure 5.3c The structure of a long bone (humerus of arm).

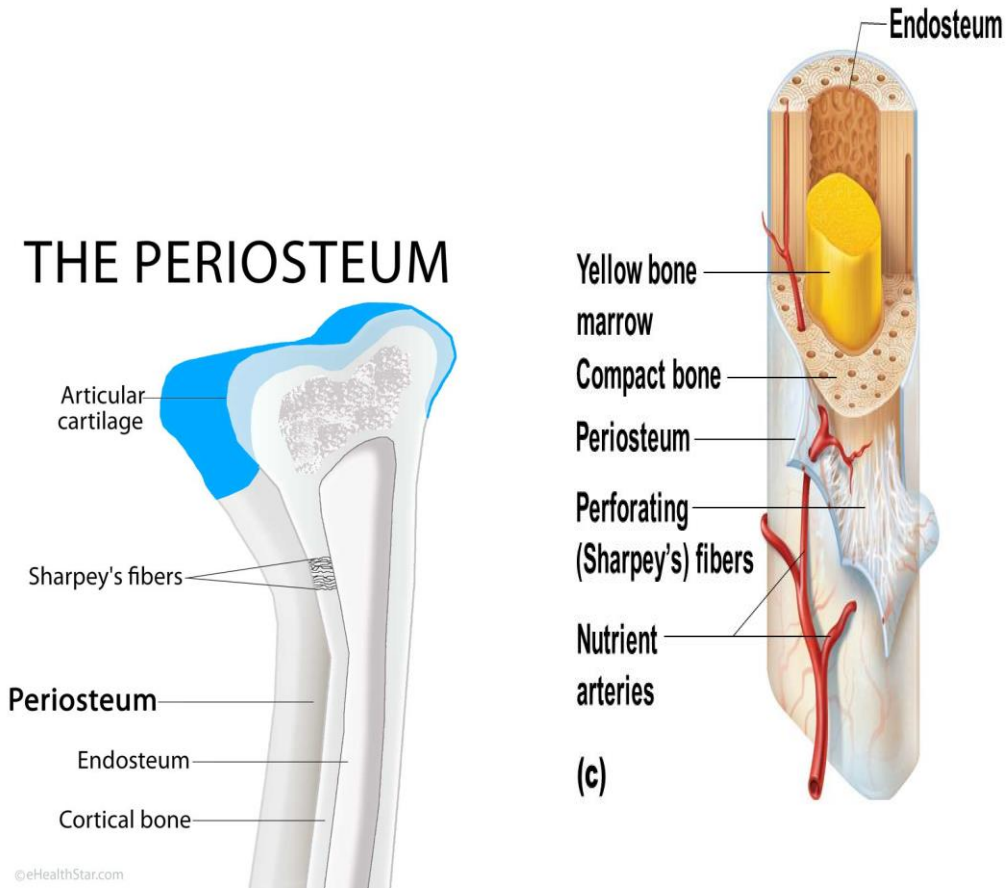

Clinical importance: When the surgeon tries to reflect (remove) the Periosteum, he/she must first cut the sharpey's fibers.

Now, what is the histological difference between Periosteum and Endosteum ?

-They differ in location and number of layers:

⭑ Endosteum ➞ lining , single layer of osteoprogenitor cells.

⭑Periosteum ➞ covering , double layer(outer fibrous and inner cellular containing osteoprogenitor cells)

*Spongy bone Vs. Compact bone

Compact bone is stronger but spongy bone is more lightly weighted

- 4 types of cells present in bone tissue:

1- osteoprogenitor cells

2- osteoblasts

3-osteocytes

4- osteoclasts

osteoprogenitor cells :

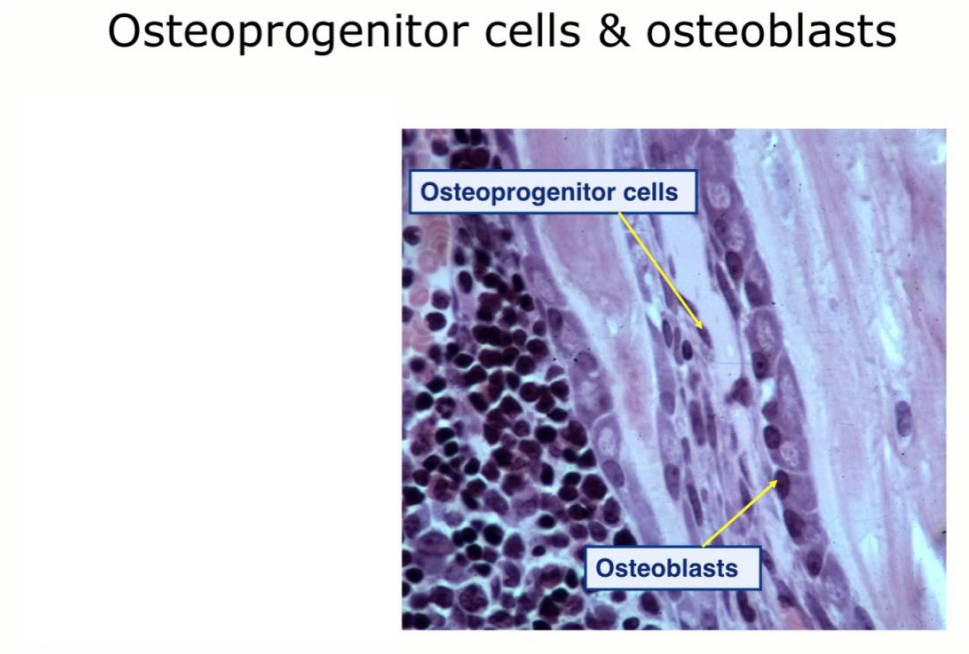

♦ **origin :** From mesenchyme

♦ **unspecialized stem cells: able to differentiate into bone-forming cells (osteoblasts).**

♦ **They can undergo mitosis**

♦**found in 2 places (cellular layer of Periosteum, the Endosteum)**

osteoblasts:

♦ **building cells ,they first secrete organic ECM (collagen I (mainly), proteoglycans, glycoproteins) and later they deposit minerals around and in between collagen fibers so the ECM is mineralized.**

♦ **Active cells in ECM synthesis.**

♦ **after the deposition of ECM, osteoblasts are entrapped within lacunae (small spaces) but they communicate with each other by canaliculi, now they are called osteocytes.**

♦ **Origin:** Osteoprogenitor cells, so you find them in periosteum and endosteum

♦ **arranged next to each other so they look like simple cuboidal epithelium.**

♦ **They synthesize ECM toward the bone surface (old bone)**

The matrix synthesized is called osteoid (like bone-still unmineralized)

♦ **osteoblasts secrete osteocalcin, osteocalcin binds Ca^{2+} with high affinity, thus raising the local concentration of these ions. Osteoblasts also release very small matrix vesicles which contain alkaline phosphatase and other enzymes. These enzymes hydrolyze PO_4^- ions from various macromolecules, creating a high concentration of these ions locally.**

The high ion concentrations cause deposition of minerals (crystallization) in and around the matrix vesicles. The crystals grow and mineralize further with formation of small growing masses of calcium **hydroxyapatite,** which surround the collagen fibers and all other macromolecules. Eventually the masses of hydroxyapatite merge as a more solid bony matrix as calcification of the matrix is completed.

♦ **Again:** ⍰ **[minerals]➞ leads to their deposition as crystals➞ these crystals unite to form the mineralized matrix of bone .**

Osteocytes:

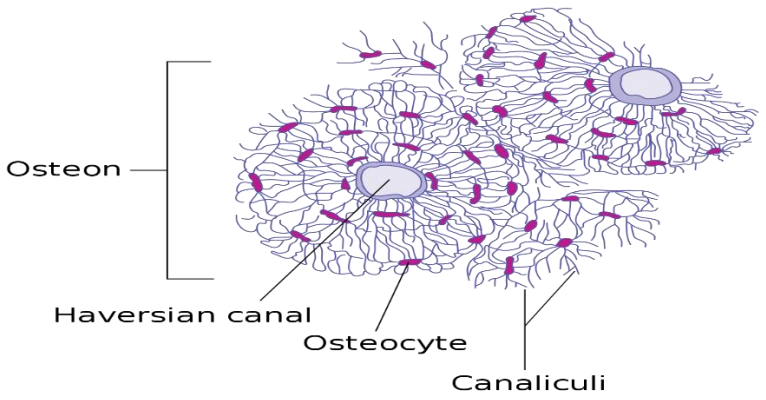

The inactive form of osteoblast. Thus, it is expected to have the same histological appearance of the inactive cells (fewer ER, condensed Golgi apparatus)

- **Smaller than osteoblasts**

- **Situated inside lacunae, one cell in each lacuna.**
- **Cells have processes (filopodial) passing through canaliculi in the thin surrounding matrix.**
- **Adjacent cells make contact through gap junctions in the processes.**

the osteocytes can communicate with each other through their processes which have gap junctions. **(Note that: gap junctions are not exclusive to the epithelial cells, it is also located between the osteocytes)

**** osteocytes are important to maintain the ECM**

Osteoclast :

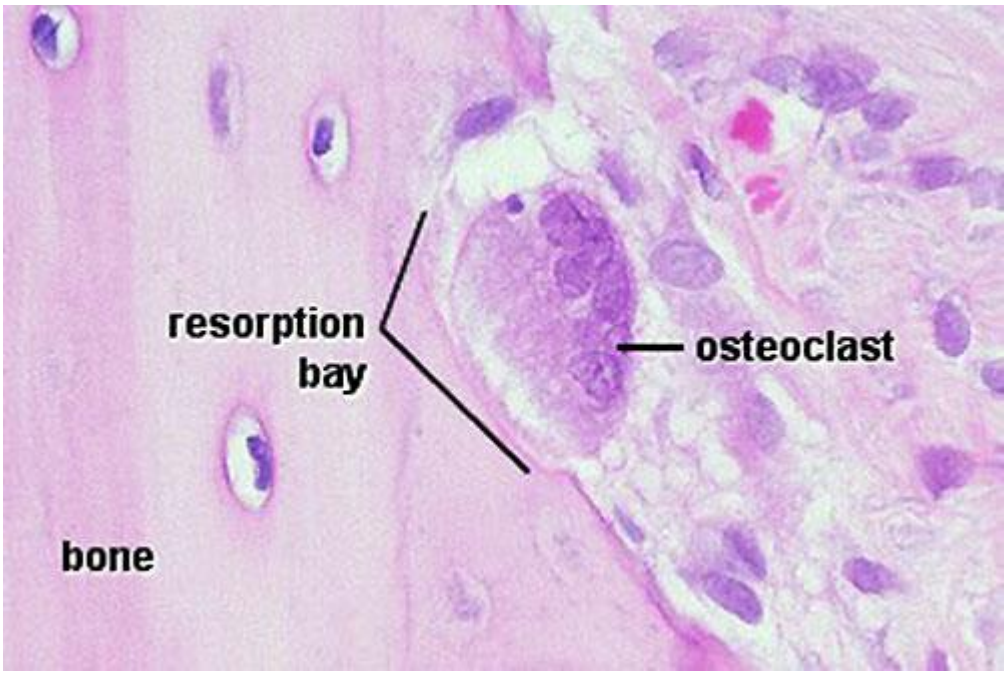

- We talked about them when we considered the mononuclear phagocyte system (different macrophage- like cells in different locations [in the bone they are called osteoclasts)
- originate from **monocytes (fusion of monocytes) (from hematopoitic stem cells in bone marrow)**
- **Multi nucleated:** their nuclei number can reach up to fifty nuclei within one cell
- **In histological sections, we are not able to see fifty nuclei, we usually see from (5-10) nuclei in each osteoclast**
- **The main function of them is the resorption** of the bone [be aware that when we say resorption of the bone it doesn't necessarily mean a disease, throughout our life, the bone is exposed to continuous state of remodeling (resorption and deposition).

- **They secrete different lysosomal enzymes into ECM (hydrolytic enzymes such as collagenase), and they pump protons (H+), creating an acidic microenviroment (low ph) in ECM, resulting in digestion and demineralization of the ECM.**
- **It's also located at the surfaces of the bone** (periosteum and endosteum), and they are bounded by actin filaments to the bone surface.
- The zone of the osteoclast that is bounded to the bone is rich in actin filaments in order to adhere to the bone, [this border of the osteoclast is called Ruffled border, it looks like microvilli, it is thrown into folds in order to increase the surface area].
- ****when a resorption of the matrix takes place, the calcium ions and phosphate will travel through the osteoclasts to the blood capillaries (by transcytosis), to increase the calcium/ phosphate level inside the blood**

  for example, the osteoclasts are activated when the concentration of the calcium in the blood is very low
- **Regulation of osteoclasts and osteoblasts:** It is achieved by hormones; certain hormones for example increase the osteoclastic activity and other hormones increase/decrease the osteoblastic activity.

- **✳ for example , normally, Estrogen (a hormone presents mainly during the reproductive life of females) inhibits the osteoclastic activity, but after the menopause low levels of Estrogen is present, so more bone resorption occurs, that is why osteoporosis is more common in females .**
- **And that is why it is very important for a female to take calcium supplement especially after the menopause**

Osteoporosi(هشاشةالعظام)

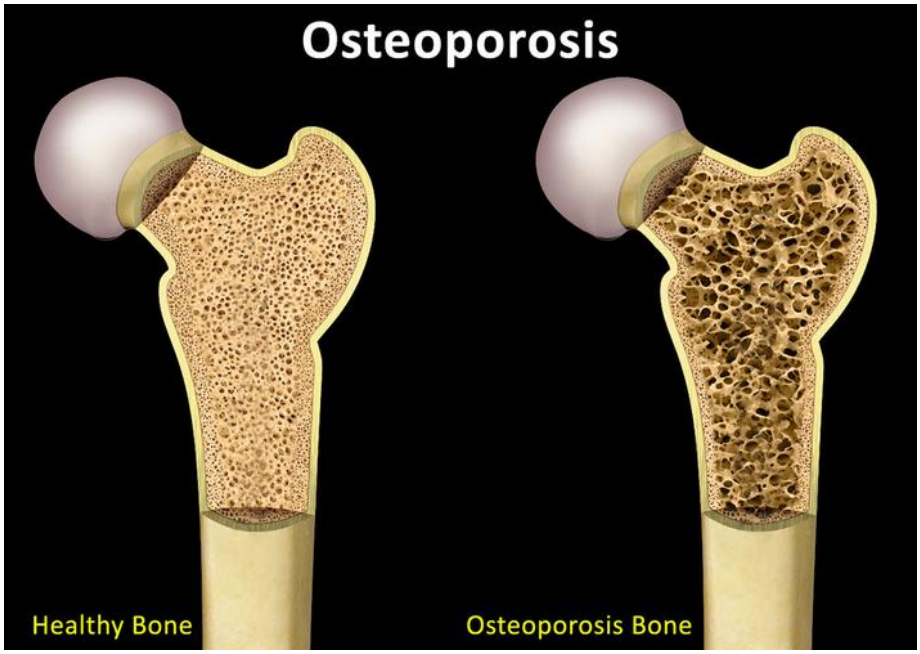

- the density of the bone is less, because the activity of the osteoclast is high which causes spaces (pores), in osteoporosis the bone deposition by osteoblasts is also less (the activity of osteoclast should be parallel to the activity of the osteoblast). The bone becomes weak and the possibility of fractures is high. In osteoporosis, the bone breaks with relatively minor injury that normally would not cause a bone to fracture. It is common in females after menopause. Because during the reproductive period estrogen (female sex hormone) inhibits the action of osteoclasts

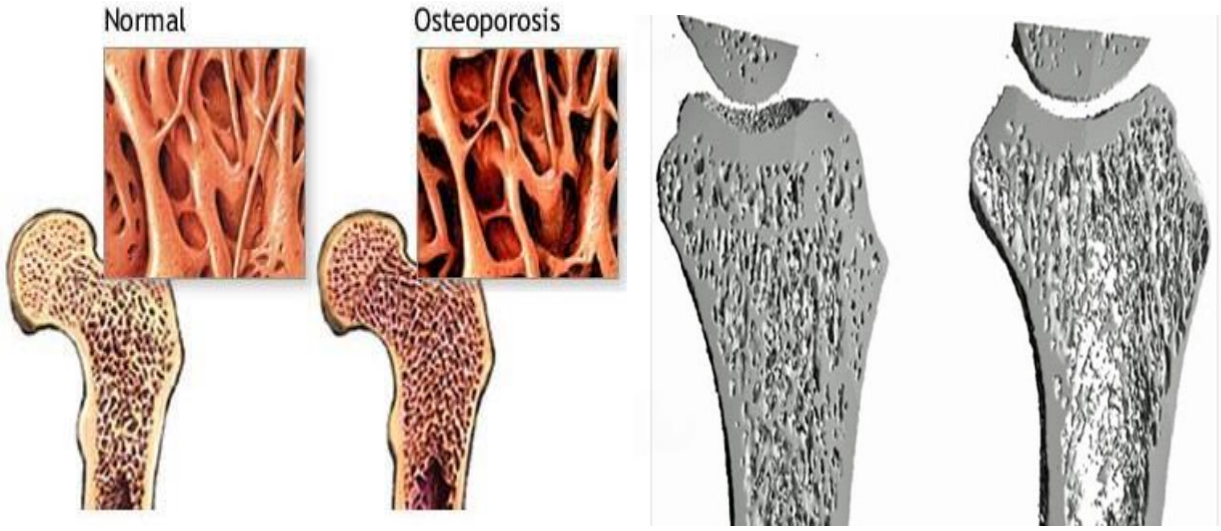

How to prepare a histological section of Bone for microscopic examination

- We have 2 methods (because ordinary microtomes can't cut the bony pieces "it is a hard tissue"):

1-decalcified bone : Removing minerals from bone tissue after putting it in a decalcifying agent , only soft structures (only cells and organic matrix) are left so I can do embedding, staining, cutting and so on ...

- So the bone after decalcification will resemble **tendon** (because the bone now contains collagen type I and osteocytes).
- This method leads to distortion of osteons so you can't see the highly-organized structure of osteons, simply because of minerals removal.

2-ground bone (ground is an adjective that means crushed) (مطحون), it is produced by fine grinding of bone specimen into small pieces then examine it under microscope without staining.

- In this method the morphology of bone is preserved, because bone dust will accumulate inside the spaces of bone (like empty lacunae, canaliculi, Haversian canal, etc ..) .
- **notice that the lacunae are empty because osteocytes were eliminated during grinding, no fixatives were used**