Histology

faculty of medicine - JU2017

◉ Sheet ○ Slides

Number

14

Done by:

Dr. Heba Kalbouneh

Corrected by:

ABDUL AZIZ ALSHAMALI

Doctor

Heba Kalbouneh

Nervous tissue

* Function of nervous tissue:

1-Sensory 2-Integration 3-Motor function

Example: when you see a glass of water you develop a sensory input (visual input), this stimulus will be converted to an electrical impulse (the photoreceptors of the retina are activated), then it goes to the brain (CNS), in the brain there is integration and interpretation of this information then taking a decision, if you decide to drink, motor impulses arise from your CNS to your muscles in order to pick up the glass and drink. Neurons respond to environmental Changes (stimuli) by altering the ionic gradient across the plasma membrane (depolarization).

*Anatomically the nervous system is divided into:

1. Central nervous system: Brain and spinal cord/ responsible for the integration of information, interpretation, making memory and taking decisions.

2-Peripheral nervous system: peripheral nerves ex: (radial, ulnar, axillary nerves……) (any nervous tissue outside the brain and spinal cord).

* The peripheral nerves are classified according to their origin:

1-from the brain: cranial nerves.

2-from the spinal cord: spinal nerves.

*The peripheral nervous system has two divisions:

1. **Somatic nervous system:** when the nerve brings sensations from skin to the CNS, and carries motor impulses to a voluntary muscle (skeletal muscle)

2-**Autonomic (visceral) nervous system:** when the nerve brings sensations from viscera to the CNS, and carries motor impulses to involuntary muscles (cardiac and smooth muscle) or glands (in general to a structure that is not under our conscious control)

*The neurons can be classified (functionally):

1-**Afferent neuron (sensory):** our skin contains sensory receptors (ex. nerve endings) and when stimulated by a stimulus such as pressure/heat, these receptors are going to generate an electrical impulse that goes from the periphery to the CNS.

2-**Efferent neuron (motor):** an electrical impulse goes from the CNS to a gland or muscle whether it is skeletal or cardiac or smooth.

<< Note that the shape of the neurons is different between the afferent and the efferent >>

* The structures of the neuron:

- ➢ The Neuron is composed of a **cell body** (Soma/ perikaryon) and this body has many processes.

- The short and branching processes are called Dendrites
- The long single process is called axon
- Axon at the terminal part gives many branches and the terminations of these branches have button like structures (swellings/knobs)
- The cell body contains large nucleus with prominent nucleolus which indicates the activity of the cell (in histological sections this appearance is very specific to neurons) ‘ Like an eye looking at you (owl eye) or fried egg’

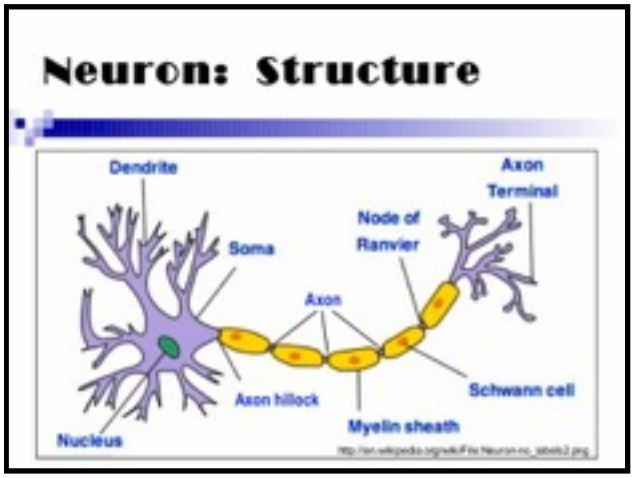

- ➢ **Dendrites**: as you go away from the cell body, these processes become smaller and thinner in diameter (like a tree), they are multiple processes. “profuse branching”

- ➢ **Axon**: it does not branch profusely, it branches at its terminals

- ➢ The axon is surrounded by a sheath called myelin (The myelin is mainly composed of lipids), the myelin does not form a continuous layer around the axon, there are spaces (nodes) between the myelin segments. These nodes are called nodes of Ranvier. Note that the nodes of Ranvier have high concentration of Na channels

- ➢ The area of contact between the terminal knob of the axon and the next neuron is called (synapse).

- ➢ These neurons are able to convert the stimulus into electrical signal and this electrical signal passes from dendrites to cell body to axon ((Unidirectional propagation of electrical impulses)).

*The Histology of the neuron:

- ➢ The cytoplasm of the cell body has **dots which appear basophilic under the L.M. Basophilia** within the cytoplasm **means** rough endoplasmic reticulum (**ribosomes**), these dots were called (Nissl bodies). This indicates the high synthetic activity of the cell. (Don’t forget that these cells synthesize neurotransmitters)

- ➢ Also the cell body has mitochondria, smooth ER, golgi apparatus (it’s important for packaging proteins from the rough ER).

- ➢ There are no organelles in the axon and dendrites (except the proximal part of the dendrites); they are mainly composed of microtubules, microfilaments and intermediate filaments (neurofilaments), which give the shape of the neuron.

- ➢ The microtubules are also important for the movement of the organelles/vesicles within the cell.

- The proximal part of the dendrites is similar to the cell body (contains Nissl bodies) but the distal part of the dendrites has no organelles (Similar to the axon)
- The neurons are highly differentiated cells, they do not undergo mitosis (long-lived cells)

***Terminologies of neurons:**

- Axoplasm = cytoplasm of axon
- Axolemma = plasma membrane of axon
- Axon hillock = the beginning of the axon is **triangular in shape and unmyelinated**. This area is the start point of the action potential generation (axon hillock is the area of maximum concentration of Na channels).
- Synaptic buttons/knobs= containing vesicles for neurotransmitters.
- The **axon** has constant diameter except at the terminal part where it starts to branch, **unlike** the **dendrites** where they become thinner as you go away from the cell body
- Axons are **longer** than dendrites, their length can reach 1 meter, for example the nerves of the lower limb, their cell bodies are in the lumber area and their axons extend from the lumbar area to the big toe
- Axon may bifurcate at multiple points along its length (axon collaterals).
- The axon is mostly myelinated and it can be unmyelinated whereas the dendrites are never myelinated.
- The axoplasm of the axon contains mitochondria, microtubules, neurofilaments, smooth ER but No Rough ER, no ribosomes and no golgi apparatus.
- Where could we find mitochondria and smooth endoplasmic reticulum inside the axon?

The terminal part of the axon, in order for the synaptic vesicles to perform exocytosis into the synaptic cleft, this process needs energy and calcium so we expect to find mitochondria and smooth ER inside the axonal terminals.

- Therefore, if there is a cut in the axon, **distal segment** of the axon **degenerates** because the axon depends on the cell body for its maintenance. The cell body is the trophic center of the neuron, if the axon is separated from the cell body it will die because it cannot synthesize its own proteins. Therefore, the cell body is important for the vitality of the axon.

Myelin: lipoprotein surrounding the axon for insulation and protection and increasing the velocity of the propagation of the action potential along the axon (The same concept as the rubber around the wire.) Myelin is formed by neuroglial cells that surround the neurons.

*AXONAL TRANSPORT

At the terminal part of the neuron, there are a lot of vesicles containing neurotransmitters, but **how these vesicles reach the axonal terminals?** by a process called axonal transport, using microtubules and motor proteins.

Axonal transport has two types:-

- **Anterograde transport**: movement of the vesicles **away** from the cell body, and its motor protein is kinesin
- **Retrograde transport:** is the movement of the vesicles **toward** the cell body (for recycling), and its motor protein is dynein

* The nervous tissue is composed of two types of cell:

1-neurons: excitable cells. Neurons are simply us, they perceive, think, sense, and remember. They control muscle activity and regulate the gland secretion.

2-neuroglia: important for supporting, nourishing and protecting neurons which is vital for establishing an appropriate microenvironment for the neurons to work, plus forming a glue-like structure between the neurons.

- **Neurons** do not divide (have no centrioles) and they are long-lived cells, **while neuroglia** can divide, they are supporting cells not neurons so they undergo mitosis.
- Neuroglia are smaller in size but larger in number compared to neurons.
- Neurons have high metabolic activity.
- Neurons are excitable cells; they receive stimuli and convert them into electrical impulses. **(but this function cannot be done by the neuroglia!!**

- CNS "central nervous system" has no or very minimal connective tissue (only around large blood - vessels)

- Brain is a soft tissue composed of neurons and neuroglia... (As if the neurolgia compensate for the absence of the connective tissue in the CNS).

- CNS has no connective tissue. While peripheral nervous system does have. Connective tissue forms sheaths surrounding the nerve fibers in PNS, however, the brain and the spinal cord are *covered by* layers of connective tissue known as meninges

Note: the **meat** that we eat is the muscles of the animal; the question is **why it must be boiled (cooked)?** >> In order to soften the connective tissue sheaths

* CLASSIFICATION ON THE NEURONS ACCORDING TO THEIR SHAPE:

The shape of sensory neurons is **different** from the motor neurons

- **Multipolar** : have one axon & multiple dendrites, this type is the most common E.g.: motor neurons
- **Bipolar:** have two processes one is the dendrite, and one is the axon. E.g.: photoreceptors of retina, olfactory epithelium, and hearing receptors inside the inner ear.
- **Pseudounipolar:** composed of a cell body with one short process (one stem) that divides into two processes, one brings impulses from the periphery called peripheral process, and the other carries impulses to the CNS called the central process. E.g.: sensory neurons

- Why is it called " pseudounipolar" ?
Originally, this neuron was bipolar, but the dendrite and the axon fused to form short stem and the two processes hence the name.

***Sensory** neurons (pain, heat, touch or pressure) are **pseudo-unipolar.**
*While the **motor** neurons are **multipolar**

4- **Anaxonic:** has no axon. It has cell body and many dendrites without an axon.

As there is no axon to initiate and propagate the action potential, this type **does not** generate action potential, **but it has a regulatory function** for the nearby neurons.

This type is f**ound entirely in CNS** (brain and spinal cord), and **never in the peripheral** nervous system.

This following picture may help you better understand the CLASSIFICATION ON THE NEURONS ACCORDING TO THEIR SHAPE

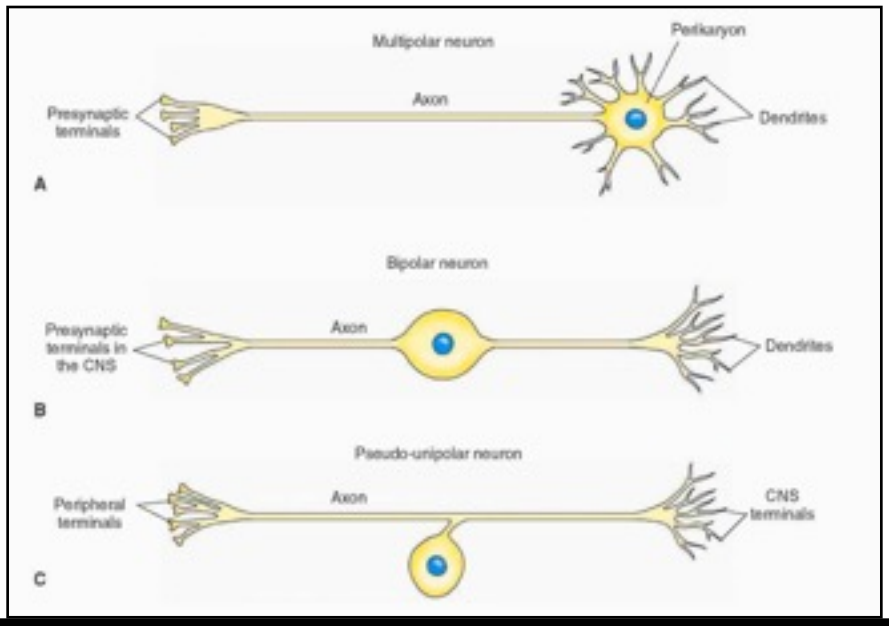

::: Summary :::

● The nervous tissue is composed of large cells which are neurons, and small supporting neuroglial cells.
● we **classify** the nervous system according to **location** into: Central nervous system and peripheral nervous system.
● we **classify** the peripheral nervous system according to **function** into:
sensory or motor
● we **classify** the **peripheral** nervous system according to the **organs** it serves into:
somatic or visceral (autonomic)
somatic: obtains sensation from the skin and delivers motor impulses to the skeletal muscles.
Visceral: obtains sensation from viscera and sends motor impulses to smooth muscles, cardiac muscles or glands

- **For action potential to be generated** there must be a Sodium (Na+) influx. Entry of Na+ will cause **depolarization** of the cell membrane; it becomes more positive inside and more negative outside. **Propagation** of action potential is uni-directional **always away from the cell body.**

- In **unmyelinated axons** Na must enter the whole length of axon to propagate the action potential, causing the action potential propagation to be slow. -While in **myelinated axons** the propagation is faster. Myelin doesn't cover the whole length of axon but there is exposed areas between myelin segments (exposed to the ECM) called (node of Ranvier) and the myelin segment between 2 nodes of Ranveir is called internodal segment. When action potential starts in Axon hillock it activates the Na gated ion channels on the nodes of Ranvier only so action potential jumps from one node to the next node.

***Types of conduction:**

1. **Saltatory** in **myelinated** neurons (Salta means jump).
2. **Continuous** in **unmyelinated** neurons.

***Local anesthetics**

How does an anesthetic work?

By stopping the action potential. Stopping action potential leads to loss of sensations because no signal is sent to the CNS from the periphery. Local anesthetics are low molecular weight molecules that block the Na voltage gated channels so no sodium is going to enter the cell, no depolarization, no action potential.

*** Synapse = meeting point between 2 structures.**

1. **Neuro-neuronal synapse:** synapse between 2 neurons (presynaptic and postsynaptic neurons).
In neuro-neuronal synapse we have different types of synapse:

a. **Axo-somatic synapse:** between the axon terminal and the cell body (remember neuron's cell body is called soma as well).

b. **Axo-dendritic synapse:** between the axon terminals of pre synaptic neuron and the dendrites of the post synaptic neuron.

c. **Axo-axonic synapse:** usually axon terminals synapse with either post synaptic neuron's dendrites or cell body but sometimes we might have a third neuron with its axon synapsing with the pre synaptic axon for modulation of activity.

2. **Neuro-muscular synapse**: synapse between a neuron and a muscle.

*** The collection of cell bodies has different names according to its location:**

- Cell bodies **inside the CNS** is called **nucleus** (single: nucleus, plural: nuclei).

- Cell bodies **in the PNS** is called **ganglion** (single: ganglion, plural: ganglia).

- The **collection of axons** makes what is called **nerve** in the **PNS**
> **eg:** (radial nerve, ulnar nerve, median nerve...etc).

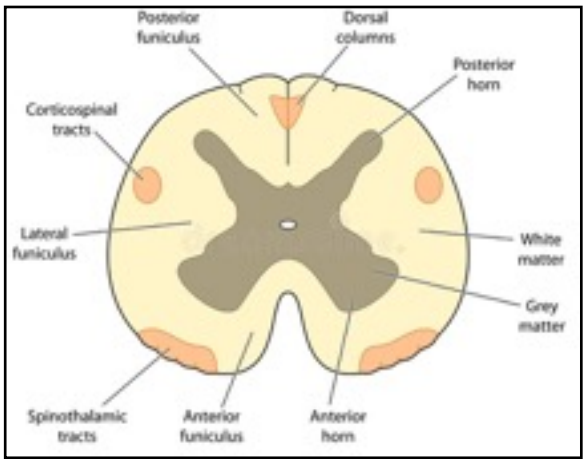

- **Collection of axons** in **CNS** makes what is called **tract**.

-**This is a section through the spinal cord** (**remember** spinal cord is part of the CNS).

- We can see light areas and dark areas.

- Dark areas are collection of cell bodies (nuclei).

- White areas are collection of axons (tract).

The collection of axons in PNS (nerve) is surrounded by a sheath of dense type of connective tissue called **Epineurium**.

- The epineurium sends **septa** that divide the nerve into groups or bundles called **Fasciculi (fasciculus)** or **fascicles (fascicle)**

- Each fasciculus is surrounded by a perineurium and inside this fasciculus we have group of axons. Each axon and its myelin are surrounded by endoneurium.

- The axon and its myelin sheath is called nerve fiber

Note: the organelles we can see inside the axon are SER (smooth endoplasmic reticulum) and mitochondria **but not RER or Golgi apparatus.**