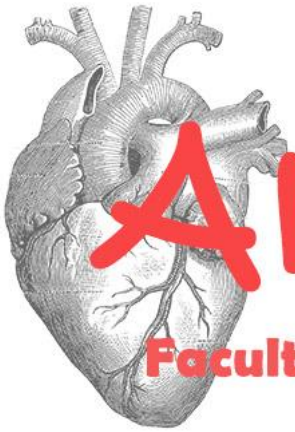

Anatomy

Faculty of Medicine - JU2017

◉ Sheet ○ Slides

Number

10

Done by:

Saba Al-Fayoumi & Lujain Hamdan

Corrected by:

Lujain Hamdan :")

Doctor

Maher Hadidi

The Heart

1) A pyramidal-shape, hollow, muscular, four-chambered organ.
2) About the size of the patient 's fist (not yours !).
3) Pumps blood to two different circulations : ● Pulmonary Circulation ● Systemic Circulation.
4) Its wall consists of three layers: inner endocardium, middle myocardium, and outer epicardium.
5) Has 45° rotation to the left, so the right side becomes anterior and the left side becomes posterior.
6) Its four Champers are :
   - Two Superior Chambers : Atriums (Right one and Left one).

♧Atria are separated from inside by Interatrial Septum.

   - Tow Inferior Chambers : Ventricles (Right one and Left one).

♧Ventricles are separated from inside by Interventricular Septum.

7) Divided into two sides : due to the rotation of the heart in the embryo (45°, left).

A. *The Right Side* : becomes The anterior side after rotation, forms the 1/3 of the heart, The low-pressure side, Contains *deoxygenated* blood.

- Divided into : ■ Right Ventricle ■ Right Atrium.

B. *The Left Side* : becomes The posterior side after rotation, forms 2/3 of the heart, The high-pressure side, Contains *oxygenated* blood.

- Divided into : ■ Left Ventricle ■ Left Atrium.

8) The Right Atrium and The Right Ventricle communicate by an atrioventricular valve, which is called Tricuspid Valve.
9) The Left Atrium and The Left Ventricle communicate by an atrioventricular valve, which is called Bicuspid Valve (mitral valve).

10) Has *Posterior* and *Anterior* **Interventricular Groove** on its surface.
11) Has The Coronary Sulcus, a circular groove on the external surface of the heart.

✓ Marks the **division between the atria and the ventricles.**
✓ Known as atrioventricular groove.
✓ The crux is the point at which the interventricular and interatrial sulci cross the coronary sulcus.

- ✓ Coronary Arteries pass through Coronary Groove to form a crown between the ventricles and the atria.
- ✓ The atria are Above the coronary groove, The ventricles are Below it.

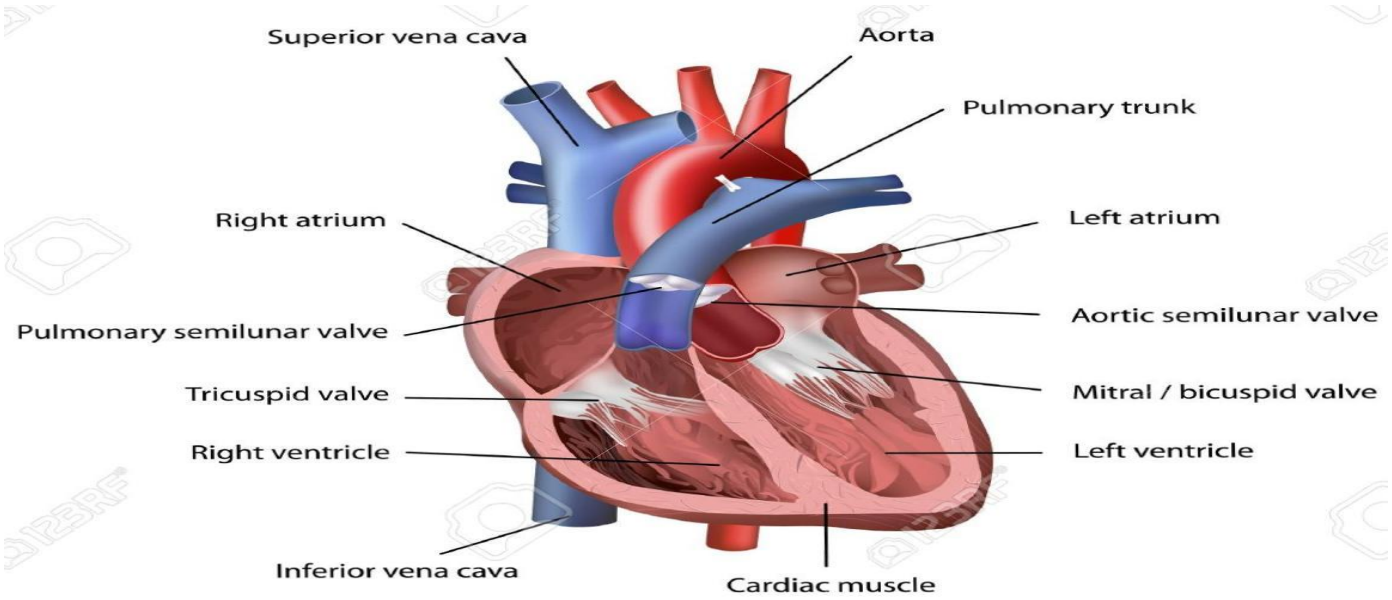

Apex of the heart

- ✓ the blunt rounded extremity of the heart, directed Downward, Forward and to the Left.
- ✓ Lies in the left fifth intercostal space slightly medial to the midclavicular (or nipple) line, approximately 9 cm from the midline.
- ✓ This location is useful clinically for determining the left border of the heart and for auscultating (hearing) pulsation of the mitral valve (Bicuspid Valve).
- ✓ Formed by The **Left Ventricle.**

Base of the heart

- ✓ Directed Posteriorly.
- ✓ Formed by ■ The **Left Atrium**, ■ The **Four Pulmonary Veins**. (Because left atrium receives oxygenated blood from the lungs by 2 right and 2 left pulmonary veins).

Borders of the heart : important to know the surface areas of the heart.

a) **Its right border** : The Right atrium.

b) **Its left border** : The Left ventricle.

c) **Its inferior border :** The right ventricle.

Surfaces of the heart

- **Anterior Surface** : Sternocostal Surface. Consists of 2/3 of Right Ventricle (mainly), 1/3 of Right Atrium (minimally).
- **Inferior Surface** : Diaphragmatic Surface. Consists of 2/3 of Left Ventricle (mainly), 1/3 of Right Ventricle.
- **The Base** : Left Atrium, 4 Pulmonary Veins.

Clinical Applications :

● When we give adrenaline to a patient, we blindly insert your needle into the right ventricle (anterior surface).

●● In Atrial Septal Defects (ASDs), The Interatrial Septum is opened, this case can be treated.

●●● Behind the heart, we have the Esophagus. Sometimes the food Compresses the Right Auricle. 》》 that prevents receiving blood from the lungs. 》》 The Lungs don't receive blood from the Right Ventricle. 》》The Right Ventricle doesn't receive blood from the Right Atrium. 》》So Superior Vena Cava can't drain the deoxygenated blood into the heart. 》》 That causes Congested Blood. 》》 This patient has blood-coughing.

Internal Anatomy of the Heart

- Each Ventricle has outflow part and inflow part.
- The inflow part should be rough to spread and minimize the pressure, that prevents bulging of the wall.
- The outflow part should be smooth to direct the stream of blood.
- Each Atrium has an auricle, which should be rough to
- Auricle is a dog-ear-like structure, **work as a reserve area.**
- *If the Left Atrium receives more blood from the lungs, it sends blood to the auricle.*

Figure 20-6c The Sectional Anatomy of the Heart.

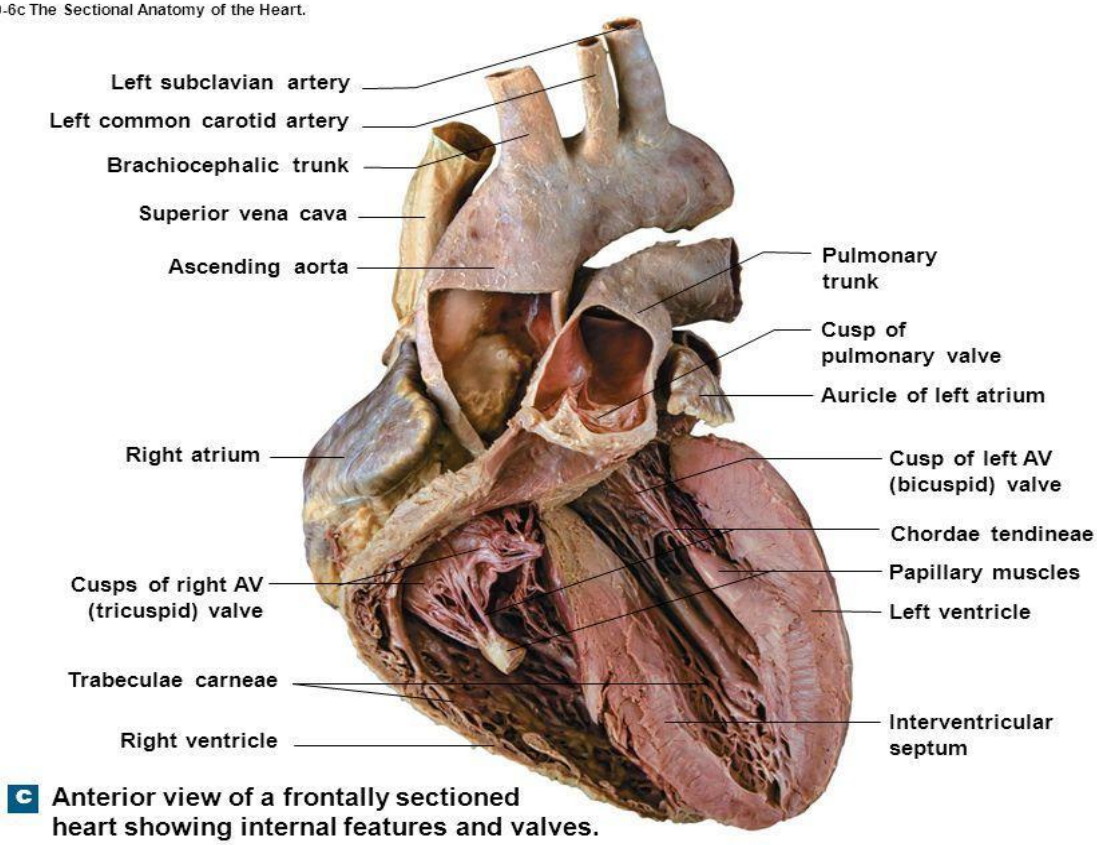

C Anterior view of a frontally sectioned heart showing internal features and valves.

1. Right Atrium

A- Receives *venous blood* from whole body by :

- Superior Vena Cava : drains the upper half of the body.
- Inferior Vena Cava : drains the lower half of the body.
- Coronary Sinus (vein) : drains the heart itself.

B- Sends blood to the right ventricle by **Tricuspid valve.**

C- Its Anterior wall is rough, Contains Crista Terminalis and Pectinate Muscles.

D- Its posterior wall is smooth, Consists of Interatrial Septum, Contains Fossa Ovalis and SA Node.

E- Is Larger than the left atrium but has a thinner wall, because it has slightly lower pressure.

☆☆Crista Terminalis (additional)

- Is a vertical muscular ridge running anteriorly along the right atrial wall from the opening of the SVC to the opening of the IVC.

Fossa Ovalis

- A fingerprint-like area or an oval-shaped depression in the interatrial septum and represents the remnant of the *foramen ovale,* through which blood runs from the right atrium to the left atrium before birth. Because in the embryo, lungs don't work. So the blood comes from SVC & IVC to the right atrium then is shunted to the left atrium through foramen ovale.
- Premature Babies (who are usually born in the 7th month of the pregnancy) when they cry, their colour becomes blue, WHY?
- Because the blood in the right and left atria is still mixed.
- The foramen ovale is shut when the baby takes the first breath which increases oxygen tension.

2. Left Atrium

A- Is smaller and has thicker walls than the right atrium.

B- Represents the base of the heart.

C- Its Anterior wall is rough, especially its auricle.

D- Its Posterior wall is smooth.

E- Receives oxygenated blood through four pulmonary veins.

F- Sends blood by to the left ventricle by Bicuspid valve.

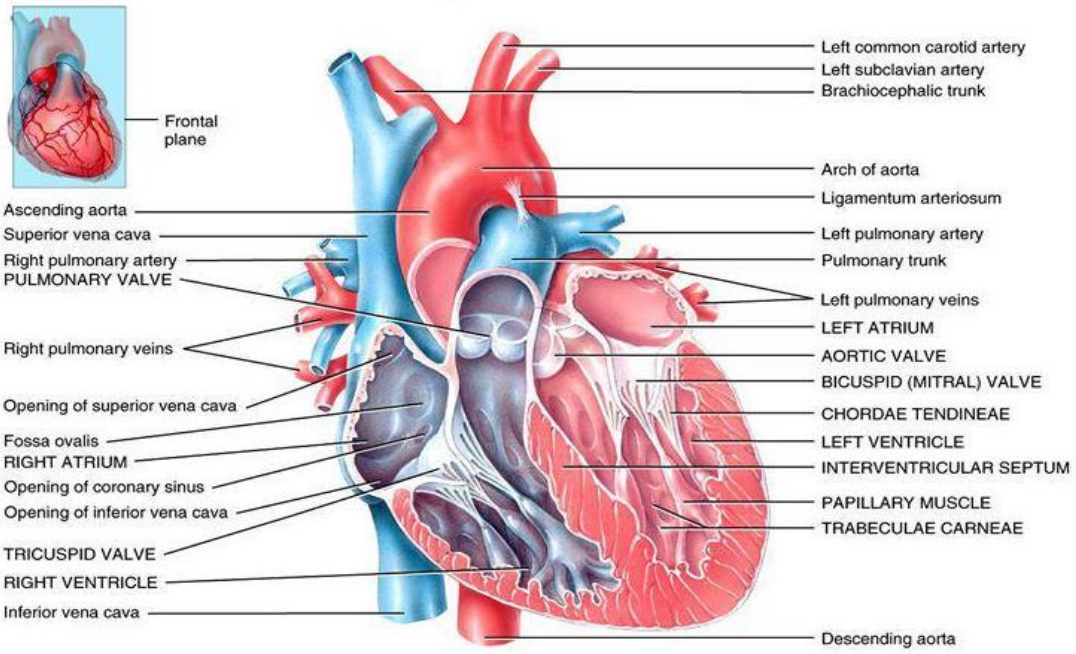

(a) Anterior view of frontal section showing internal anatomy

3. Right Ventricle

A- Makes up the major portion of the anterior (sternocostal) surface of the heart.

B- Received blood from the Right Atrium through Tricuspid Valve.

C- Sends the deoxygenated blood to the lungs via pulmonary trunk.

D- Represents most of the inferior border and anterior surface, but only 1/3 of the inferior surface.

E- Its lumen is circular.

F- Its wall is thicker than the wall of atria and thinner than the wall of left ventricle.

G- Its Anterior wall (Inflow part) : is a rough network of projecting cardiac muscles bundles.

H- Its Posterior wall (Outflow part) : is smooth, called Infundibulum of pulmonary artery, it leads to pulmonary trunk.

I- Contains the following structures:

(a) Trabeculae Carneae

- ✓ A network of Interconnected muscles anastomosing muscular ridges of myocardium in the ventricles.
- ✓ The biggest muscle is Septomarginal band.

(b) Septomarginal band : (Moderator band)

- ✓ Forms a bridge in the right ventricle, which part branch of the AV bundle passes through.
- ✓ Is called the moderator band for its ability to prevent overdistention of the ventricle.

The cardiac potential spreads through S.A. node 》》 AV node 》》AV bundle 》》AV bundle branches 》》Purkinje Fibers 》》Papillary Muscles before the wall of the ventricles to shut the cusps.

(c) Papillary Muscles

- ✓ Are pyramidal-shaped muscles enveloped by endocardium.
- ✓ Each one Has a base, body and Apex.
- ✓ The base Extends from the anterior and posterior ventricular walls and the septum.

- ✓ The apex is a small tendon-like structure attached to the chordae tendineae.
- ✓ Shut the cusps during diastole
- ✓ Incompetence of the Tricuspid or Bicuspid Valves means that they can't be closed before the contraction occurs, so the blood can return back to the atria.

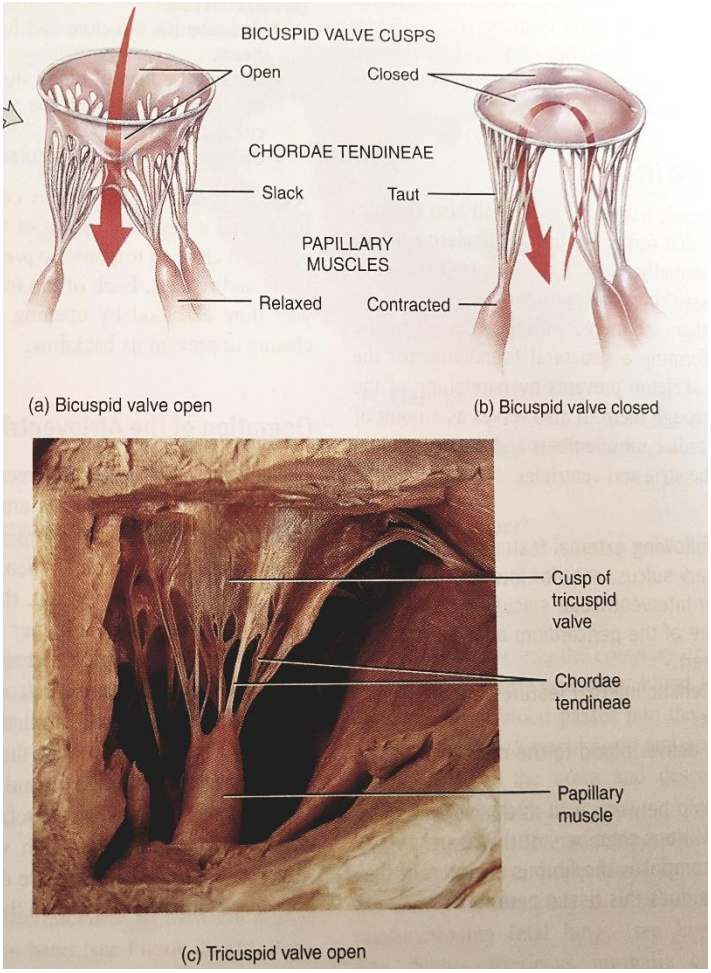

(d) Chordae Tendineae

- ✓ Extend from one papillary muscle to more than one cusp of the tricuspid valve.
- ✓ Attached to the free morgen of the cusps.
- ✓ "like a parachute man, Body of the parachute man is the Papillary Muscle, Head of him is the apex of this muscle, Cords of the parachute are Chordae Tendineae, The parachute is the cusp."
- ✓ Prevent eversion of the valve cusps into the atrium during ventricular contractions.

(e) Infundibulum

Is the upper smooth-walled portion of the right ventricle, which leads to the pulmonary trunk.

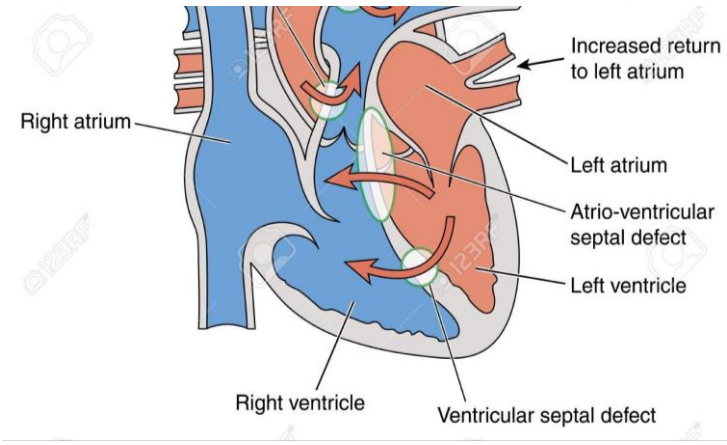

(f) IV Septum

- ✓ the place of origin of the septal papillary muscle.
- ✓ mostly muscular but has a small membranous upper part, which is a common site of ventricular septal defects (VSDs).
- ✓ In VSDs the Interventricular Septum is opened, this case can't be treated.

4. Left Ventricle

- The main chamber of the heart.
- Forms the apex of the heart , so it's directed downward and forward to the left.
- Forms most of the inferior surface, and the left border of the heart.
- Has the thickest wall, because it has the highest pressure.
- Its pressure is six times higher than it in the right ventricle.
- Its lumen is crescent in shape, due to the high pressure.
- Contains oxygenated blood.
- Receives blood from the left atrium through Bicuspid Valve.
- Sends blood to Aorta through the Aortic Semilunar Valve.
- It Anterior wall (Interventricular Septum) : is smooth, contains Aortic Vestibule.
- Its Posterior wall : is rough, Contains Trabeculae Carnea and Papillary Muscles.
- Its Papillary Muscles are bigger than them in the right ventricle.
- Contains two papillary muscles (anterior and posterior) with their chordae tendineae and a meshwork of muscular ridges, the trabeculae carneae cordis.
- Performs harder work, has a thicker (two to three times as thick) wall than right ventricle.
- Its inflow part is the apex of the heart.

Blood flow

1) SVC drains the upper half of the body, IVC drains the lower half of the body, Coronary vein drains the heart itself.
2) Right Atrium receives the venous blood from the whole body through that veins.
3) Right Ventricle receives that venous blood from the Right Atrium through Tricuspid valve.
4) Right Ventricle sends the deoxygenated blood to the pulmonary trunk through the Pulmonary Semilunar Valve.
5) The Pulmonary Artery (trunk) sends the deoxygenated blood into the right and left lungs.
6) The Left Atrium receives the oxygenated blood from the four Pulmonary Veins.
7) The Left Atrium sends the oxygenated blood to The Left Ventricle through Bicuspid Valve.

8) The Left Ventricle sends the oxygenated blood to the Aorta through the Aortic Semilunar Valve.
9) The Aorta sends the oxygenated blood to the whole of the body.

- **Diastole** : represents the **Refilling** of the Ventricles, So *Tricuspid Valve and Bicuspid Valve are opened*, **The Heart Muscle in Relaxation.**
- **Systole** : represents the **Ejecting** the blood from the Ventricles, So *Tricuspid Valve and Bicuspid Valve are closed, Aortic Valve and Pulmonary Valve are opened.* **The Heart Muscle in Contraction.**

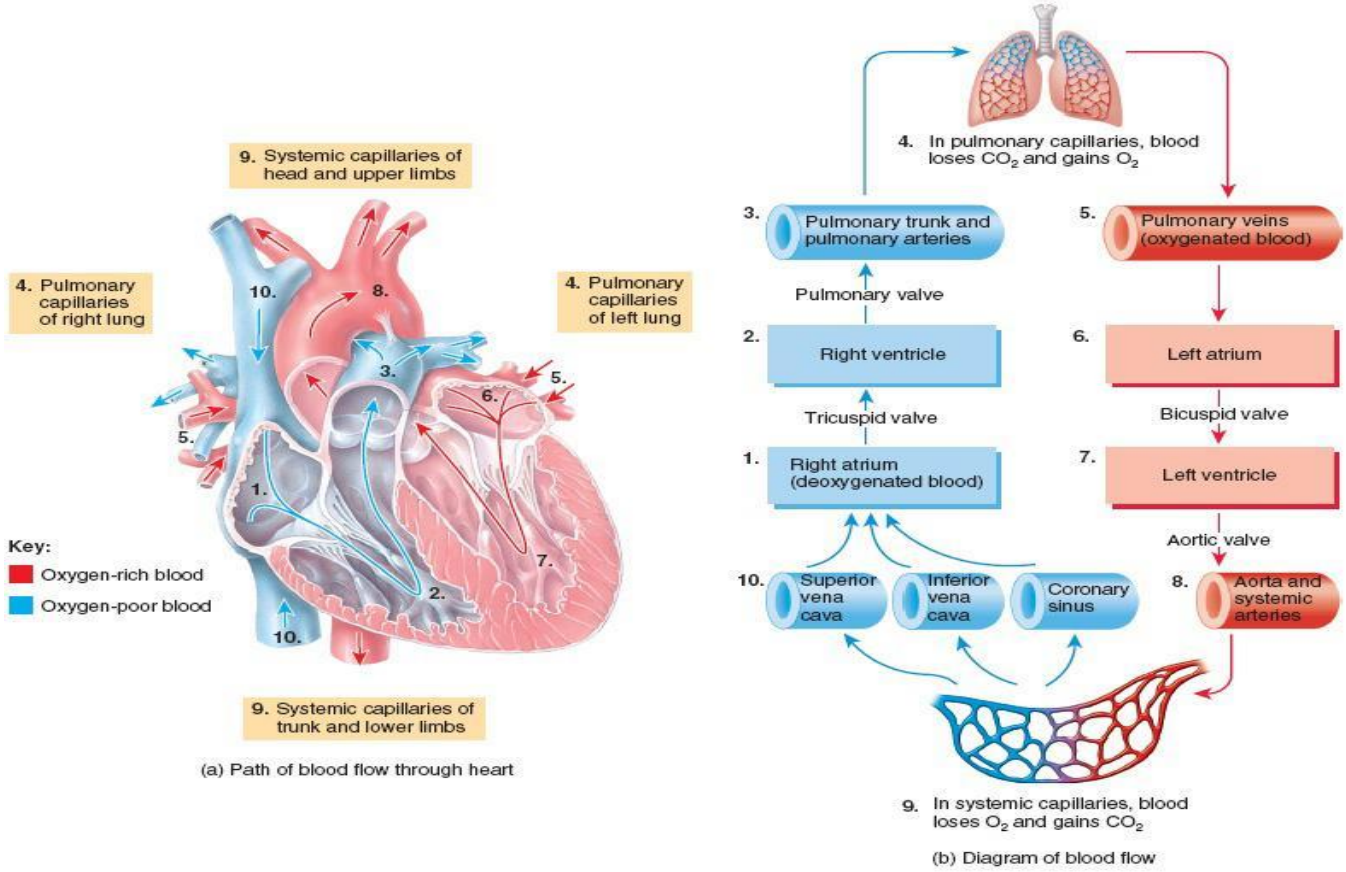

Arterial Supply of the heart

- Heart is supplied by two Coronary Arteries : one right and one left.
- Both arise from Ascending Aorta.

1) The Left Coronary artery

- Supplies the left side of the heart. Also it's Larger and Shorter than the right one.
- Passes through Pulmonary Trunk and Left Auricle. Also, Passes at inferior surface.
- It's branches into : 1-3 branches :

a) Anterior Interventricular Branch : is the largest branch, called also Left Anterior Descending (LAD): is the main blood Supply to the left ventricle, and common site for Coagulum (جلطة).

b) Circumflex branch : Supplies the left ventricle and atrium.

2) The Right Coronary Artery

- Supplies the right side of the heart. Also, it's Smaller than the left one.
- Passes through Pulmonary Trunk and Right Auricle. Also, Passes at inferior surface.
- It's branches into : 1-4 branches :

a) Marginal branch.

b) SA Nodal Artery : in 60% of people the SA node is supplied by Right Coronary Artery. In 40% of people it's supplied by Left Coronary Artery.

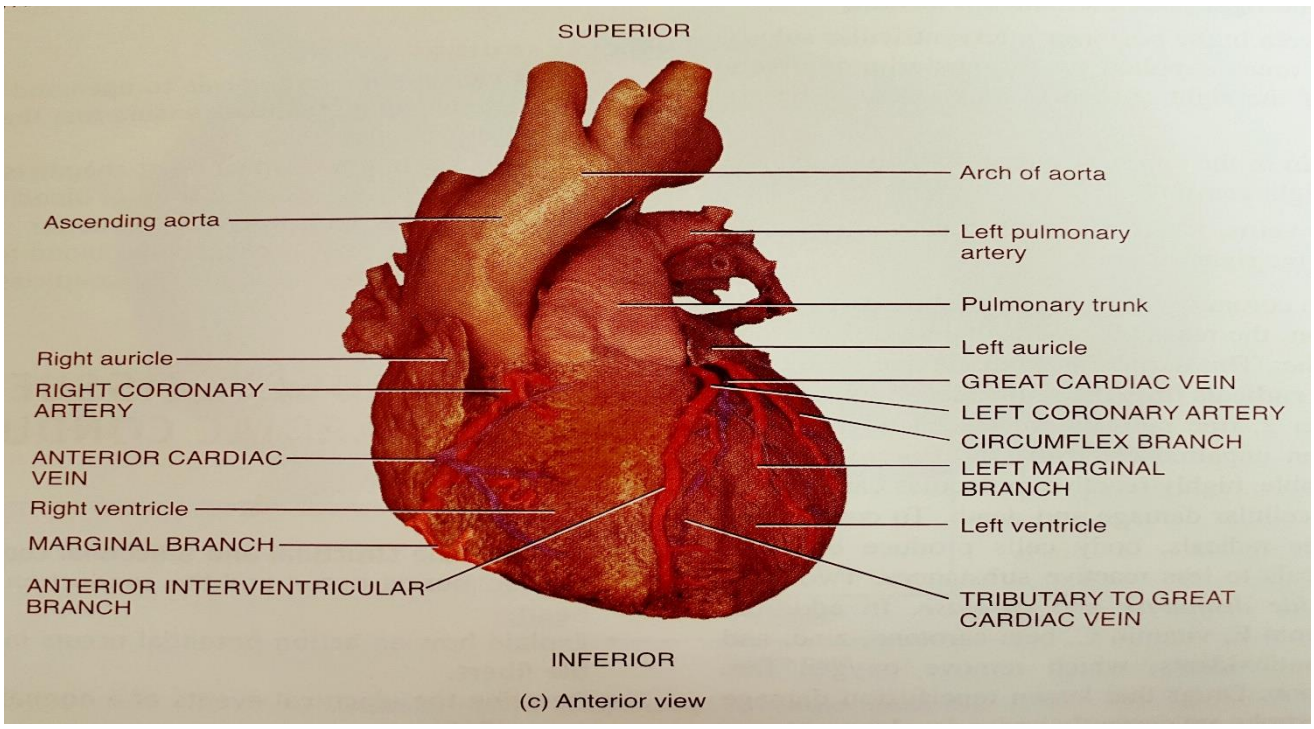

(c) Anterior view

Coronary Vein (sinus)

- Drains the tissues in the heart. Extends from left to right. Receives three veins.
- Passes through Coronary Sulcus at the inferior surface.
- About 5 cm long. Ends in the right atrium.

Conducting System of the Heart

1. A network of modified, specialized cardiac muscle cells (fibers) that lie immediately beneath the endocardium and specialized in Conductivity only.
2. Conduction means receiving and carrying impulses throughout the cardiac muscle, signaling the heart chambers to contract in the proper sequence.

3. It's autorhythmic, means that Constantly initiates and coordinates atrial and ventricular muscles contraction.
4. It's isolated from Myocardium by a sheath of Connective Tissue.
5. It establishes a Unidirectional pathway of excitation signals and contraction.
6. It's organized into four basic components : S.A. Node, AV Node, Right Bundle Branch, Left Bundle Branch and Purkinje Fibers.

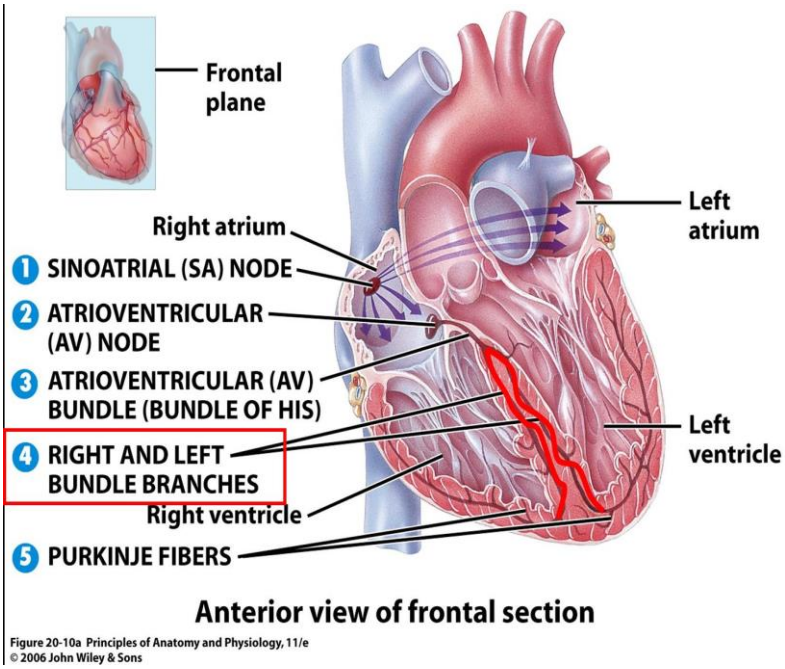

- **Sinoatrial Node**

- Is a small mass of specialized cardiac muscle fibers that lies in the myocardium at the upper end of the crista terminalis near the opening of the SVC in the right atrium.
- Is known as the pacemaker of the heart and initiates Excitation Signals (the heartbeat), spreads the impulses in a wave along The Wall (Cardiac Muscle Fibers) of the Atria.
- Can be altered by autonomic nervous stimulation (sympathetic stimulation speeds it up, and vagal stimulation slows it down).
- Sends the signals to the AV node.
- Is supplied by the sinus node artery, which is a branch of the right coronary artery.

- **Atrioventricular Node**

- At the inferior end of the Interatrial Septum.
- Receives the impulse from the sinoatrial (SA) node and Passes it to the AV bundle.
- Also it's innervate by ANS.
- Bestrides the septum by dividing into Right and Left Bundles within muscular part of Interventricular Septum.
- Each branch reaches the Papillary Muscles.

☆☆<u>Heart Sounds (additional)</u>

1. First ("Lub") Sound : Is caused by the closure of the tricuspid and mitral valves at the onset of ventricular systole.

2. Second ("Dub") Sound : Is caused by the closure of the aortic and pulmonary valves (and vibration of walls of the heart and major vessels) at the onset of ventricular diastole.