Histology

faculty of medicine - JU2017

◉ Sheet ○ Slides

Number

9

Done by:

Dr.Heba Kalbouneh

Corrected by:

Ragad Alhawi

Doctor

Dr.Heba Kalbouneh

"Cartilage"

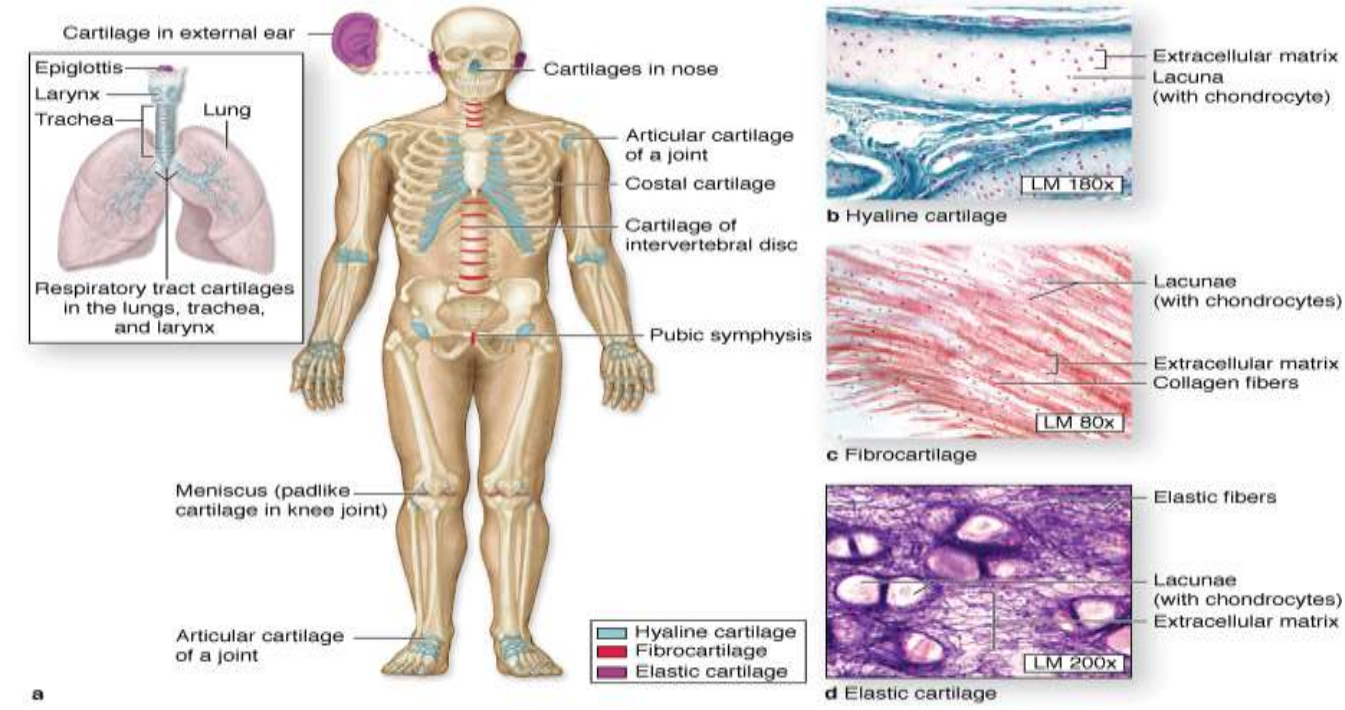

- Cartilage is a special **form of connective tissue;** it has the same origin of connective tissue (embryonic mesenchyme). It contains cells and ECM=> (fibers and ground substance).
- The ECM of the cartilage has characteristic features between the proper connective tissue and the bone; it is firmer than ECM of C.T, but at the same time it's less hard than ECM of the bone. ECM of the cartilage **is semi-solid;** it forms strong or firm gel.
- The cartilage is **avascular** (No blood vessels passing through the cartilage), **no nerves pass through the cartilage**

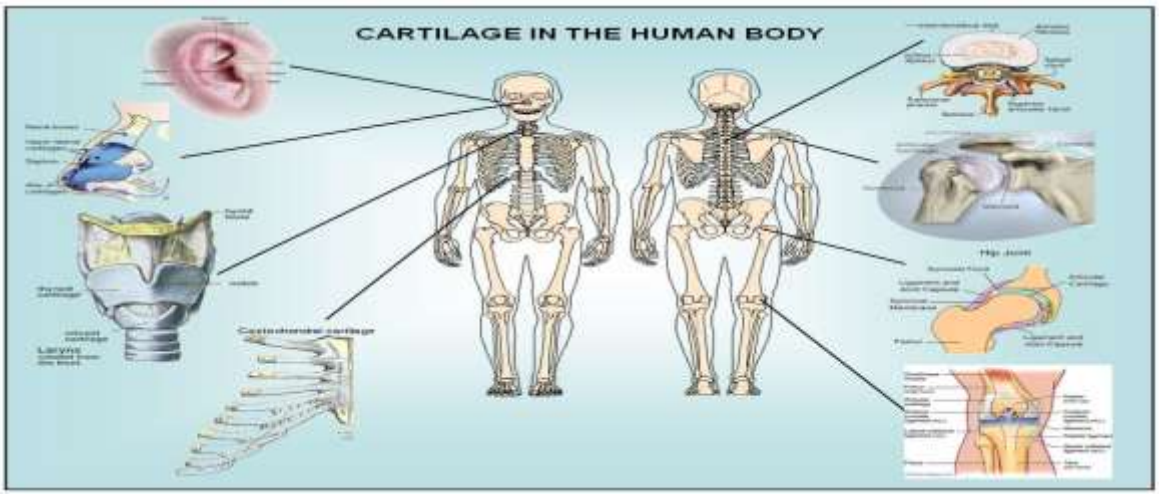

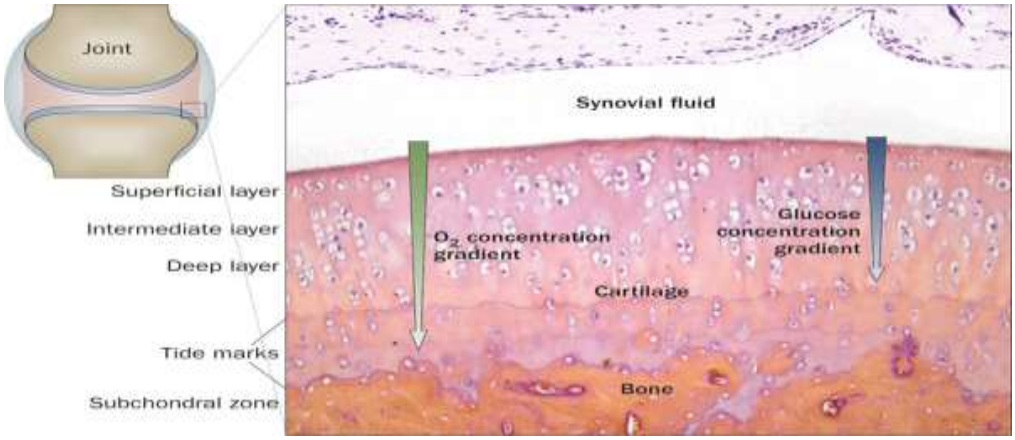

- **<u>Since the cartilage is avascular, how does it get its nutrients and eliminate the waste products?</u>** By diffusion from nearby structures (perichondrium).

- **<u>What are the functions of the cartilage?</u>**

-The main function of the cartilage is to provide shape for certain structures, such as the external ear, which is composed of certain type of cartilage.

1-It resists compression without distortion. For example; inside our knee joint, between the two articulating bones, there is a pad of cartilage (fibrocartilage) that withstands compression and tensile forces of our weight without distortion. This is the main function of the ECM of the cartilage, because ECM of the cartilage contains high amount of water; about 80%. Imagine a gel-filled balloon; it will resist the compressional forces without being distorted. Same concept with the cartilage, cartilage has a high amount of proteoglycans which makes this ECM firm jello

2-Structural support for soft tissues. <u>For example</u>, in the trachea, there are pieces of cartilage inside the wall, in order to support or give a shape for the trachea and in order for the trachea to stay open all the time, because it is an air passage way.

3-Shock absorbing: such as the pad of cartilage inside our knee joint. Also between our vertebrae there are pads of cartilages that are called intervertebral discs, these discs act as shock absorbers and weight bearing discs.

4-Smooth surface to allow the sliding movement in joints: the elbow joint is composed of 3 articulating bones; each articular surface is covered by a layer of cartilage called articular cartilage. This articular cartilage is very important to allow smooth movement between the articulating bones. With aging: degeneration of cartilage will result in stiffness and bone to bone contact (Rough joint) and that's why elderly complain from their joints especially knees.

5-The cartilage is important for growth. MOST of our bones were cartilages in the embryonic life, with growth these cartilages were replaced by bones (NOT CONVERTED). This makes sense because our bones are hard structures (ECM of the

bone is highly mineralized), so they can't grow. The cartilage grows then is replaced by bone, grows then replaced by bone, and this is how we grow.

- **Components of cartilage:**

-Like any other type of C.T, cartilage is composed of:

1. **Cells.**
2. **ECM: Fibers and ground substance.**

-The cells of the cartilage are called **"Chondroblasts" or "chondrocytes"** according to the activity/Growing state. "Chondro" refers to cartilage.

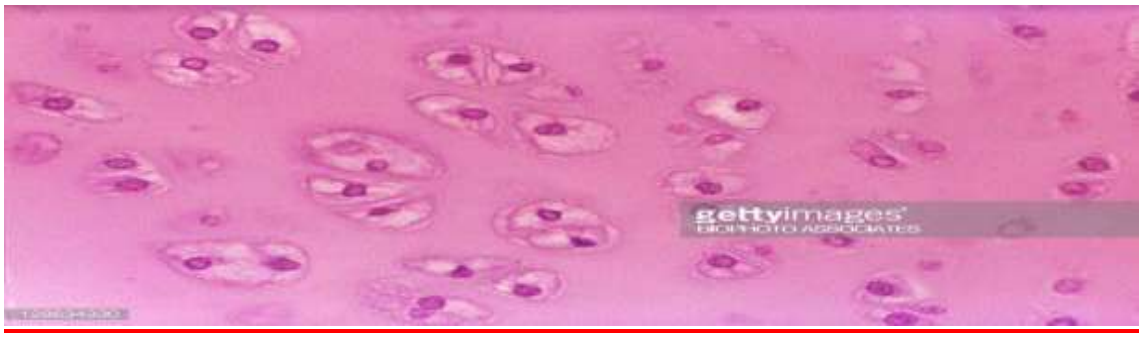

-Chondroblasts are the cells that synthesize the ECM of the cartilage (during growth).

-Chondrocytes are the resting chondroblasts; cells after finishing building up the ECM, retired cells, inactive cells, they only maintain the integrity of ECM, but they no longer synthesize more ECM. Chondrocytes are located within small spaces called lacunae; these spaces are not found in the living cartilage, because in the living cartilage, the chondroblasts fill most of these spaces, but because of preparation, shrinkage of cells occurs resulting in artifact.

-Chondroblasts and chondrocytes are analogous to the fibroblasts and fibrocytes of the ordinary connective tissue.

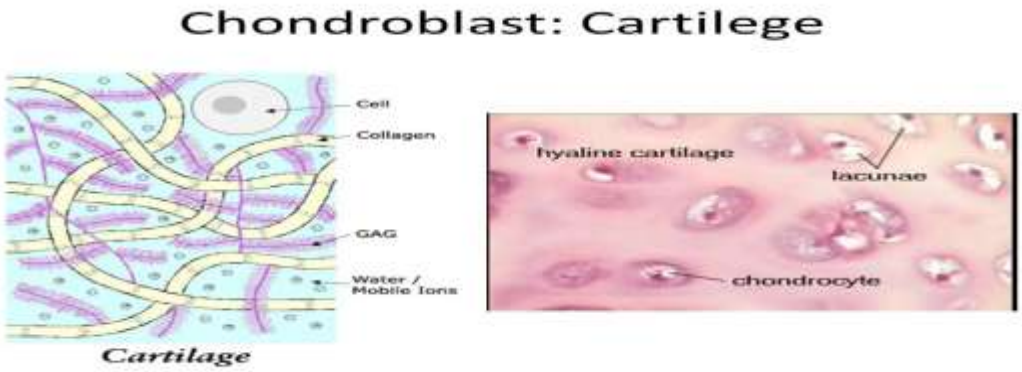

-Fibers: (Collagen + Elastic) => cartilage basically contains collagen type 2.

-Ground Substance that is composed of:

1. Proteoglycans:	2. GAGs (Repeating units of disaccharides):	3. Glycoproteins:
-The proteoglycan of the cartilage is called Aggrecan.	- In the cartilage, GAGs are mainly keratin-sulfate and chondroitin-sulfate.	chondronectin attaches the cells of cartilage (chondroblasts) to the ECM (They are adhesive molecules), (when we say attach to ECM, we mean to the fibers and ground substance).
-Proteoglycan: a protein core attached to it many GAGs (around 150 GAGs molecules in one aggrecan, so it is a very large molecule). 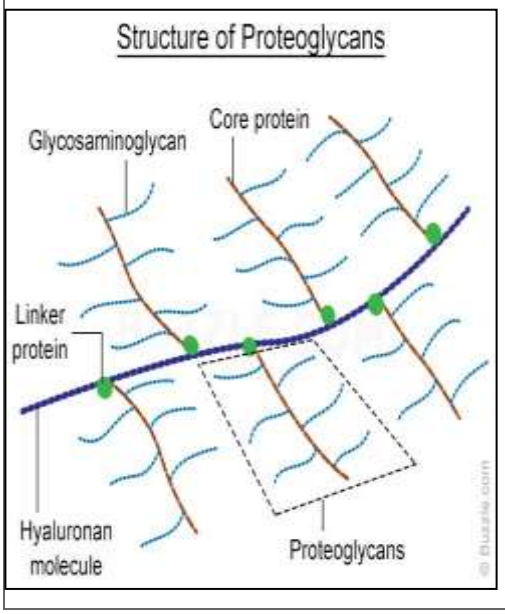	-remember GAGs are two types: a. Sulfated (mainly keratin-sulfate and chondroitin sulfate). b. Non-sulfated (Hyaluronic acid. It is a large molecule that attracts high amount of proteoglycans (Aggrecan) resulting in a structure that fills the ECM and looks like a bottle-brush in the ECM. Concentration of it around the cells is more than	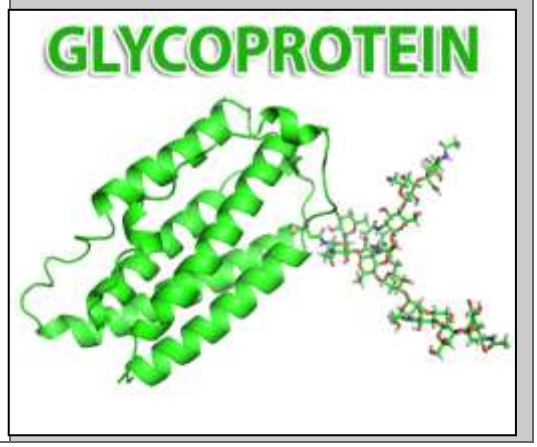

-ECM is almost homogenous and that's because collagen type II (main type of collagen in the cartilage) and ground substance have the same optical density.

- **remember collagen type 2 forms fibrils** (thin structures that cannot be stained with H & E stains).

ECM of cartilage appears basophilic or bluish because the ground substance is rich in GAGs (High amount of negative charges), that attract water and basic dyes.

-the staining reaction of ECM: a difference in the staining density occurs: the areas

around the cells appear darker than the areas away from the cells, Reason?! Because of difference in molecular composition between the matrix surrounding the cells and the matrix away from the cells, meaning that the areas around the cells have higher concentration of GAGs (more basophilic), as you go away from cells, you find less GAGs and more collagen type 2 (less basophilic)

-Dark matrix surrounding the cells is called **"Territorial Matrix"** (directly around each lacuna), and the light matrix away from the cells is called “Interterritorial” matrix

- **Perichondrium:**

-Since the cartilage is avascular, it's surrounded by a layer of dense irregular connective tissue called "Perichondrium" (Peri: surrounding, chondrium: cartilage). It contains capillaries, and by diffusion of nutrients from these capillaries, the cartilage can survive and get its nutrients.

-Now, Perichondrium is composed of 2 different layers:

a. **Outer Fibrous layer. It is composed of collagen type 1 and fibrocytes**
b. **Inner Cellular layer: rich in cells (chondrogenic cells that are able to differentiate into chondroblasts).**

-Cartilage is always found in thin plates, because it's avascular. It depends on diffusion from the perichondrium which contains capillaries, and by diffusion of nutrients from these capillaries, these chondroblasts can take their nutrients. It's impossible to find the cartilage in thick plates, because the cartilage cells in the center of the cartilage will die as no nutrients reach by diffusion.

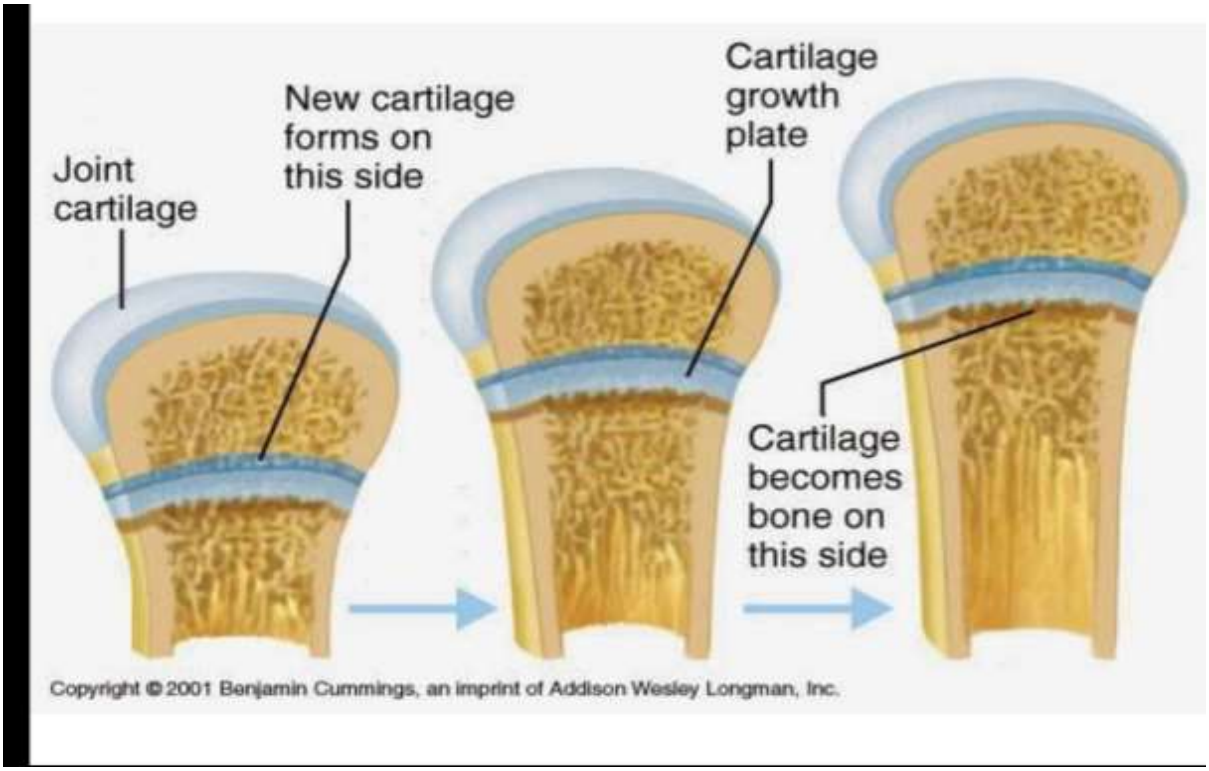

- **How the cartilage was formed?**

It's formed by a process called **"Chondrogenesis"** (Genesis: formation of), (Chondrogenesis: formation of cartilage):

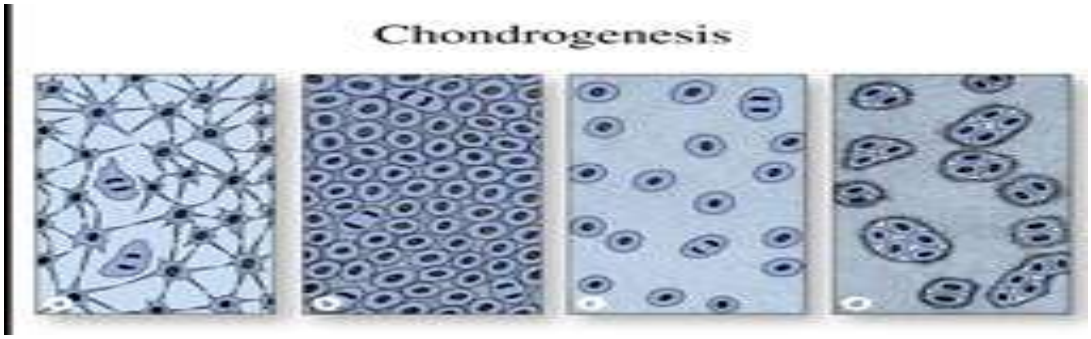

-The origin of the cartilage is from the embryonic mesenchyme like any other type of C.T. Mesenchyme is composed of mesenchymal cells and these cells are star-shaped cells, have thin processes, and the ECM of this tissue (Embryonic C.T) is richer in ground substance than fibers. Each one of these mesenchymal cells differentiates into cartilage forming cells (Chondroblasts).

-Chondroblasts secrete or synthesize ECM. These chondroblasts will be separated from each other as a result of synthesizing ECM, they secrete matrix and separate from each other.

-The histological features of chondroblast are as any other active cells: the nucleus is euchromatic and the cytoplasm is full with organelles.

-Now each one of these chondroblasts undergoes mitosis, the 2 daughter cells will synthesize ECM, then they will be separated from each other, and this how the cartilage grows and gets bigger until late adolescence is reached where growth stops. The final appearance is either single chondrocyte or groups of chondrocytes (Isogenous groups). Each group consists of 2 or 4 or 6 or 8 cells, and each group represents the last mitotic division of the chondroblast. In the late adolescence, the growth stops, chondroblasts no longer synthesize ECM and they become entrapped within the matrix they have synthesized (entrapped within lacunae), now called chondrocytes

-Meanwhile, mesenchymal cells at the periphery differentiate into Fibroblasts and these fibroblasts form the perichondrium (Fibrous C.T surrounding the cartilage).

- Cartilage also grows from periphery (from perichondrium), the inner layer of perichondrium is cellular and contains chondrogenic cells

-So Cartilage grows from 2 places, from inside because of mitosis of existing chondroblasts, and from periphery (perichondrium).

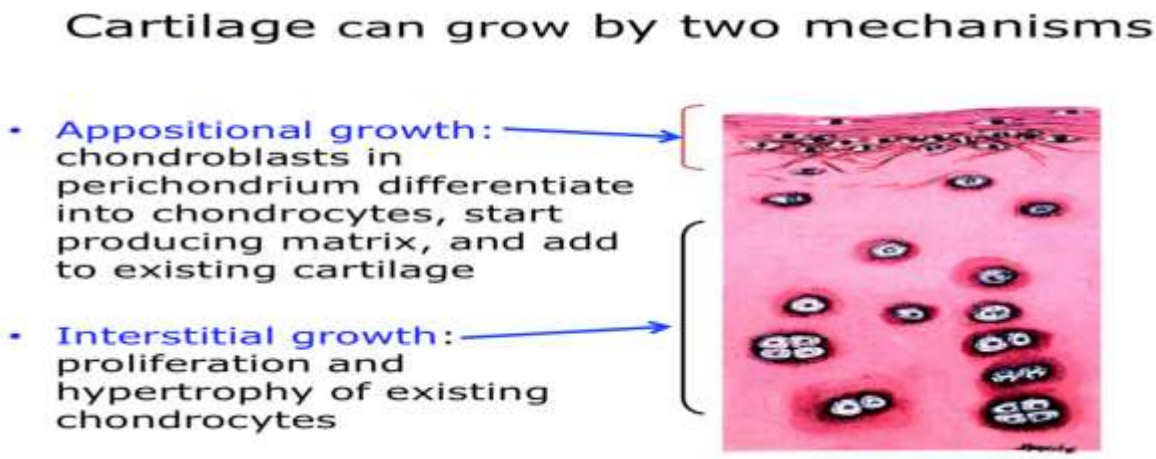

- **We have two ty pes of growth in cartilage, and it's very important to differentiate between them:**
  1. **Interstitial growth (from within/inside the cartilage):**
     -Chondroblasts within the cartilage undergo mitosis, secretion of ECM, and separation from each other.
     -So chondroblasts divide and form small groups of cells (Isogenous groups) which produce matrix and become separated from each other. This is how the cartilage grows (from the inside).

     Appositional growth (from periphery/outside/circumference of the cartilage):
     -The chondrogenic cells of the perichondrium are responsible for it.
     -chondrogenic cells of the perichondrium differentiate into chondroblasts to form the cartilage from periphery.
     -This type of growth occurs in the **mature and immature cartilage** (In both types of cartilage).

- **Types of cartilage:**

-They are classified according to the main component of ECM , note that the cartilage always contains type 2 collagen:

1. **Hyaline Cartilage:** It is composed mainly of collagen type 2
2. **Elastic Cartilage:** It is composed mainly of Elastic fibers.
3. **Fibro-Cartilage:** It is composed mainly of collagen type 1. Remember always fibro refers to collagen 1.

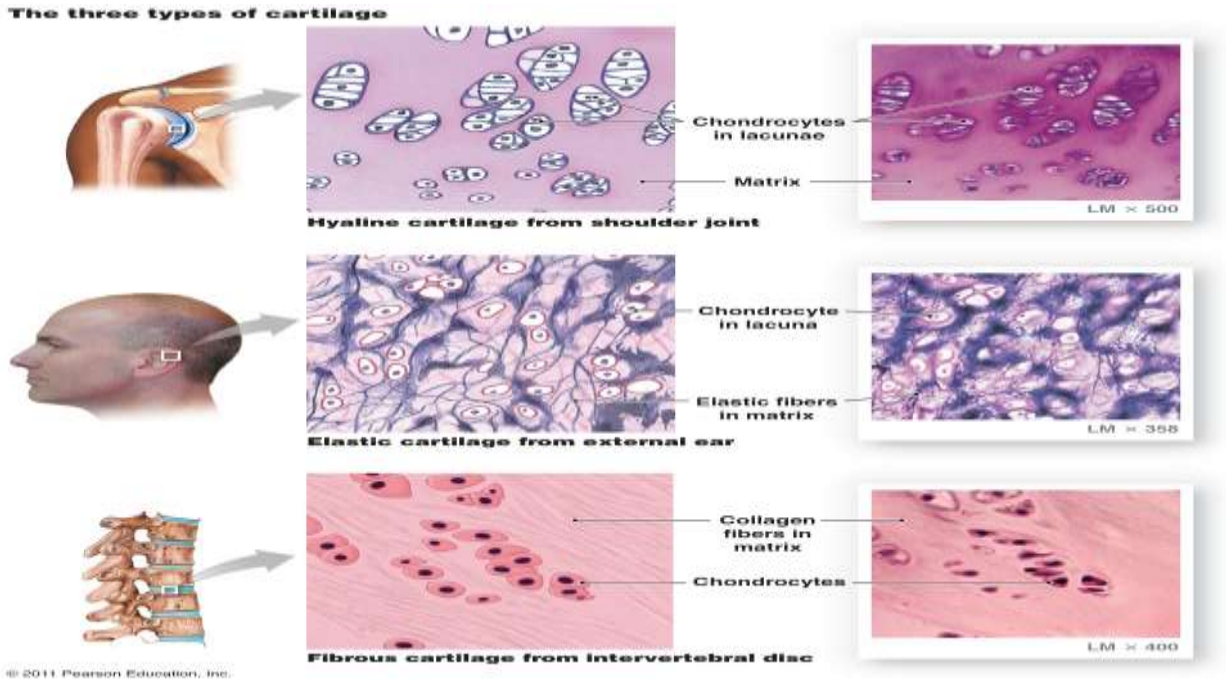

• Hyaline cartilage:

-The most common type of cartilage in our body.

-Originally (In the embryo), the skeleton was composed of cartilaginous model. This cartilaginous model is hyaline cartilage. With growth, most of this hyaline cartilage will be replaced by bone except in two places: the articular surface and the growth plate

Hyaline cartilage is also found in the septum of the nose, wall of trachea, larynx, wall of bronchii and anterior ends of the ribs which are called costal cartilages.

In the fresh state, hyaline cartilage looks glassy, “Hyalos" in latin means glass (transparent).

-Distribution of hyaline cartilage:

1. **Epiphyseal (growth) plate.**
2. **Costal cartilage (Anterior end of the ribs).**
3. **Thyroid cartilage (Adam Apple).**
4. **Fetal skeleton: cartilaginous model inside the fetus.**
5. **In the walls of larger respiratory passages (Nose, larynx, trachea and bronchi)**

6-Articular cartilage

-We see pieces of cartilage inside the wall of trachea, supporting the wall of trachea, because the respiratory passage ways must be opened all the

time. These cartilages form C-shaped structures, completed posteriorly by a muscle called trachealis muscle. The contraction and relaxation of this muscle result in broncho-constriction and broncho- dilation, but in all cases it's opened all the time.

The trachealis muscle of asthmatic people is contracted most of the time, so they have constriction in the air passage way

Elastic cartilage:

- **Mainly composed of elastic fibers which add elasticity and resilience to the cartilage.**
- **ECM of elastic cartilage also contains collagen type 2 and GAGs.**
- **Distribution of elastic cartilage:**

- **Ear pinna(External ear)**
- **External auditory tube**
- **Eustachian tubes: connection between the middle ear and the pharynx**
- **Epiglottis**

- **Notice in elastic cartilage:**

-Perichondrium.
-Chondrocytes.
-ECM: contains dark black fibers (Elastic fibers).

- It is very difficult to differentiate between the elastic cartilage and the hyaline cartilage using H and E stain, however, hyaline cartilage looks more homogenous.

✓ **How to differentiate between them?**

by using special stains such as the **elastin stain**. Once you visualize the thin elastic fibers; it is elastic cartilage, while the ECM of the hyaline cartilage is more homogenous.

Fibrocartilage:

- From its name, it has characteristics between the ordinary fibrous connective tissue (tendon; dense regular type of connective tissue) and characteristics from the cartilage.
- It is located at the insertion sites of tendons
- Fibrocartilage is composed of cartilage cells**; Chondrocytes** which are located inside small spaces **(lacunae).**

-The ECM of the fibrocartilage is composed of thick eosinophilic fibers of collagen type 1. The fibers of collagen type 1 lie parallel to each other like in tendons **(dense regular type of connective tissue).**

- ✓ **Histologically: when you look at the fibrocartilage, you will find that it is similar to the dense regular connective tissue, why?**

  - Because collagen type 1 fibers are eosinophilic, parallel to each other in both; tendons and fibrocartilage.

- ✓ **What is the difference between the tendons and the fibrocartilage?**
  - -The cells of the dense regular connective tissue (tendons) are fibrocytes which appear as naked flat nuclei between the parallel collagen type 1 fibers, whereas the cells of the fibrocartilage are chondrocytes which are located within lacunae, and form rows between the collagen type 1 fibers.

- We can conclude that the fibrocartilage is the strongest type of cartilage

Cartilage	ECM	Cells	Characteristics
Hyaline cartilage	**Collagen 2, and ground substance**	**Chondrocytes within lacunae**	**It is less flexible than elastic cartilage and less strong than fibrocartilage.**
Elastic cartilage	**Elastic fibers, collagen 2 and ground substance**	**Chondrocytes within lacunae**	**The most resilient or flexible or elastic**
Fibrocartilage	**Collagen 1, collagen type 2 and ground substance**	**Chondrocytes within lacunae and fibrocytes**	**The strongest type of cartilage**

Location

- **at the insertion sites of tendons and in areas subjected to high compression and torsion forces, Such as:**
  1. **Between the vertebrae, fibrocartilage between vertebrae is called intervertebral disc**
  2. **Inside our knee joint, because the knee joint bears all the weight of our body, so we expect to find a pad of fibrocartilage between the 2 articulating surfaces. This pad of fibrocartilage is called meniscus**
  3. **Symphysis pubis.**

- ✓ **What is the difference between the cartilage inside the knee joint and the articular cartilage of the joint?**

  -Articular cartilage is hyaline cartilage; it covers the articular surfaces to allow for smooth movement

  While the meniscus is located inside the knee joint cavity (fibrocartilage) Fibrocartilage is strong and acts as shock-absorber, its found between the vertebrae and the knee joint to resist the different mechanical forces without distortion

- ✓ **Why symphysis pubis is fibrocartilage?**

-Symphysis pubis is an articulation between the 2 pubic bones anteriorly. We find a disc of fibrocartilage between the two pubic bones and this fibrocartilage provides firm attachment between the 2 pubic bones without movement and acts also as shock- absorber. A slight movement of this joint could occur in females during delivery

- **X-ray from the knee joint: we see 2 colors in the x-ray:**

1. **White: Radiopaque, where the bone appears whitish.**
2. **Black: Radiolucent, where the soft tissue appears black.**

   -This depends on the passage of the x-ray beam.

   - the bone is dense so the x-ray beam doesn't pass through it, so it appears white, but the cartilage is not mineralized, so the x-ray beam passes through it, and it appears dark (black).

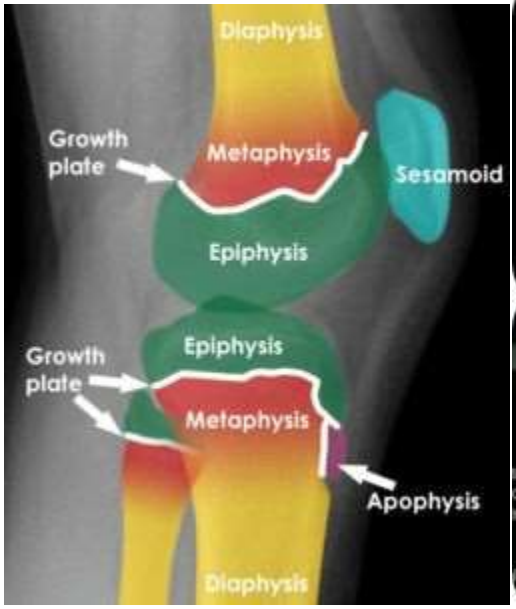

- **Epiphyseal plate (growth plate):**

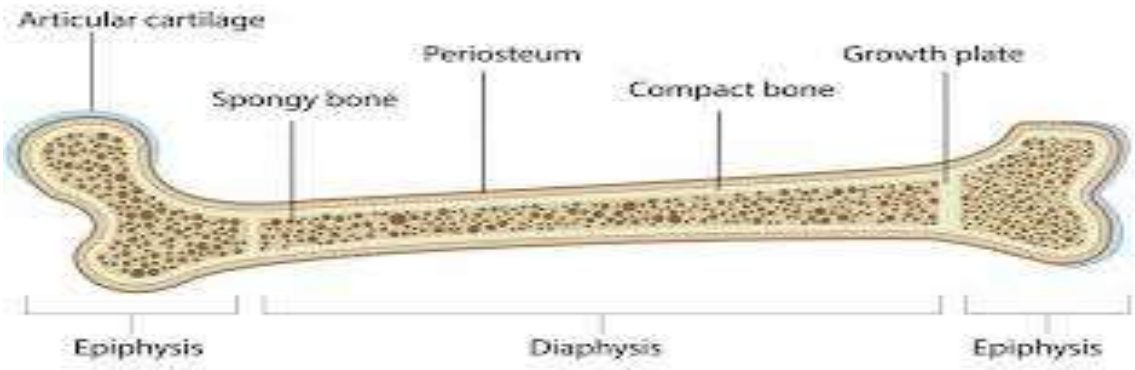

-Diaphysis: **is the shaft of the long bone.**
-Epiphysis: **proximal and distal ends of the long bone.**
-There is a radiolucent area between the diaphysis and the epiphysis, this area is filled with cartilage.

- ✓ **The humerus for example during the embryonic development was hyaline cartilage.** **Then a process called ossification (Formation of bone) starts, how?**

- In the center of diaphysis (shaft) appears a center of Ossification: from this center cartilage is replaced by bone.

- The formation of bone starts from the middle of shaft of the long bone upward (proximally) and downward (distally)

Another center of ossification appears in the distal and proximal epiphysis (ends) and inside the epiphysis the bone is formed radially.

- The area in the long bone that still has cartilage between the diaphysis and epiphysis is called epiphyseal plate, so as long as we have this plate we can grow in height but at certain point this plate is going to close and to be replaced completely by bone (epiphyseal line).

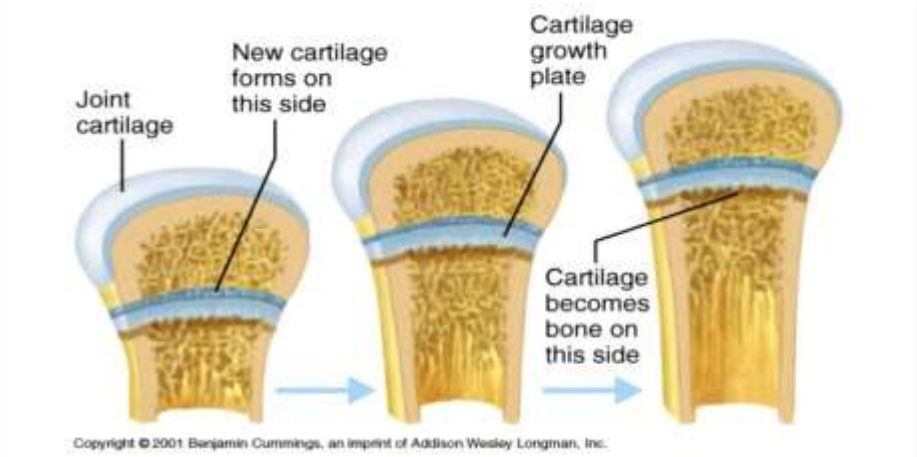

- \

- It is very important for our bone to be originally cartilage because the cartilage can grow by interstitial growth and by appositional growth. Step by step, a replacement of the cartilage with the bone occurs and this is how we grow in height until late adolescence is reached and then the growth stops, the cartilage of growth plate will disappear and will be completely replaced by bone.

- 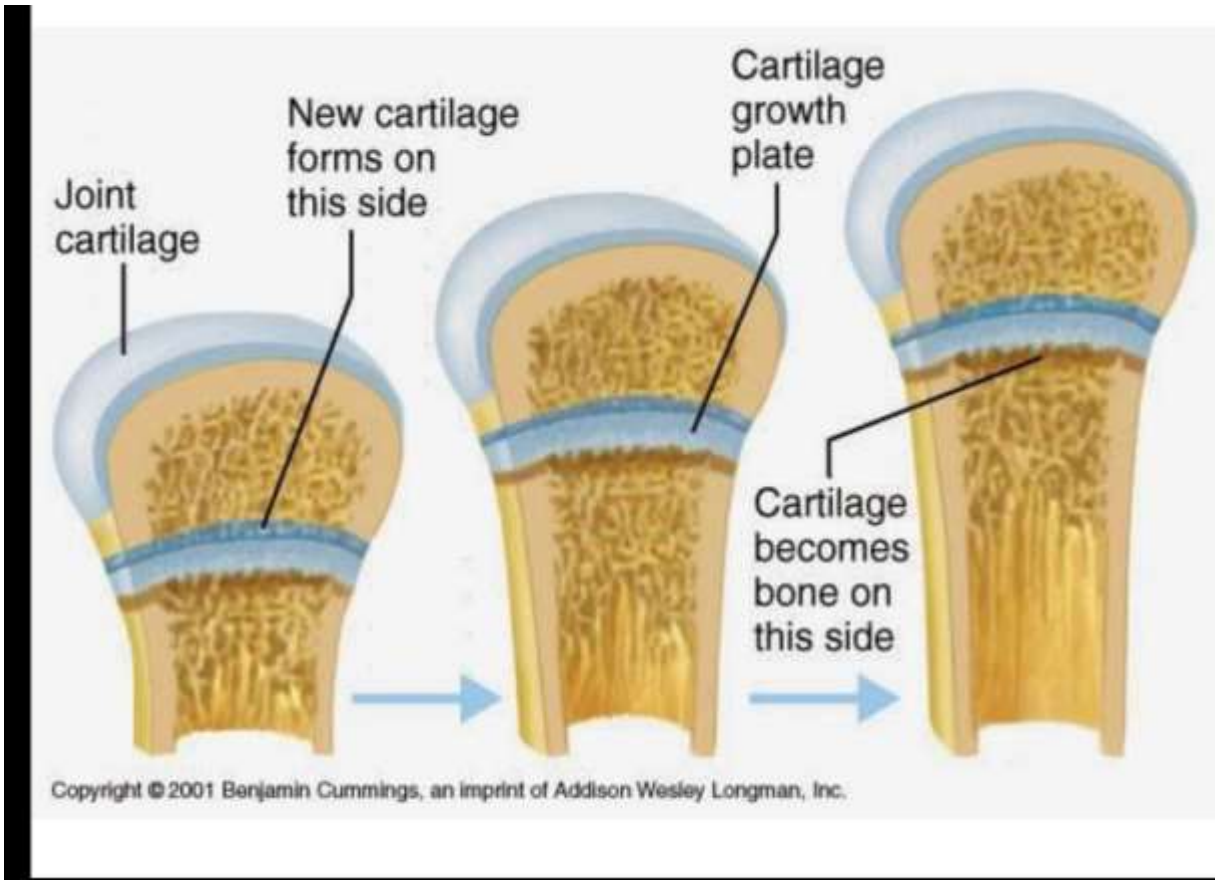

Epiphyseal plate: a thin layer of hyaline cartilage between the epiphysis and the bone shaft (diaphysis). The new bone forms along the plate. Epiphyseal plates remain open until late adolescence. Also it is called growth plate. We can find it in a developing long bone.

Note that articular cartilage has no perichondrium, it gets its nutrition mainly from synovial fluid (fluid inside the joint cavity)

➢ Clinical application:

Osteoarthritis (degeneration of the joint):

The articulating surfaces of long bones are covered by a layer of articular cartilage (hyaline), this articular cartilage is smooth to allow smooth sliding movement, again with aging, degeneration happens inside this articular cartilage, it wears down over time. It is caused by mechanical stress applied to the joint. It is characterized by pain and stiffness of the joint. It is common in knee joint.

The herniated disc:

- the intervertebral discs (fibrocartilage) are composed of 2 parts inner and outer:

1. **Inner part is called nucleus pulposus:** it is a gelatinous material (soft material) inside the intervertebral disc. Mainly this soft material is composed of water and hyaluronic acid which attracts high amount of water.
2. **Outer or surrounding layer is called annulus fibrosus :** annulus means it is on the periphery (ring-shaped), and fibrosus means that it is mainly composed of fibrocartilage (The strongest type of cartilage).

- With aging, the fibrocartilage which surrounds the disc undergoes degenerative changes so this structure will be easily cracked, the nucleus pulposus which is the soft gelatinous material will extrude and compress the nearby nerves and this will result in pain.

  - This condition is called slipped disc or herniated disc or the ruptured disc: all these conditions describing the bulging-out of the gelatinous material of the intervertebral disc outward through a crack as a result of aging.